

The use of LEDs in the treatment of acne

O uso do LED para o tratamento da acne

DOI: <http://dx.doi.org/10.5935/scd1984-8773.2017941074>

ABSTRACT

Introduction: The use of light emitting diodes (LEDs) is a new modality of treatment for acne. The blue and amber lights are indicated for the treatment of acne due to their bactericidal and cellular metabolism stimulation actions, respectively.

Objectives: To compare the effects of the combined blue and amber LEDs to those of the isolated blue LED in the treatment of acne.

Methods: A randomized, blind clinical trial was carried out with men and women distributed into 2 groups: Group 1 (blue LED) and Group 2 (blue + amber LEDs). The patients were treated in 6 sessions and qualitatively evaluated using 2 subjective tools: a questionnaire and the Visual Scale of Facial Perception and quantitatively by counting the number of acne lesions.

Results: Ten volunteers took part in the study, obtaining a reduction of 1.7 in the psychosocial impact score and of 2.1 in the Visual Scale of Facial Perception, as well as an improvement in the lesions count, with 60% presenting slight improvement and 10% presenting moderate improvement.

Conclusions: It was possible to observe that the use of LED was effective in the two groups (both in the self-assessment of improvement and in the reduction of the number of lesions), meaning it can be considered an effective and safe therapy for the management of acne.

Keywords: acne vulgaris; lasers; light; phototherapy; physical therapy specialty; psychosocial impact; skin

RESUMO

Introdução: Uma nova modalidade de tratamento para a acne é o uso dos light emitting diodes (LEDs). A luz azul é indicada para o tratamento da acne por sua ação bactericida, e a luz âmbar por sua ação no metabolismo celular.

Objetivos: Comparar os efeitos do LED azul associado ao âmbar com os do LED azul isolado no tratamento da acne.

Métodos: Ensaio clínico randomizado, cego, em indivíduos de ambos os sexos, subdivididos em Grupo 1 (LED azul) e Grupo 2 (LED azul + âmbar), tratados em seis sessões, avaliados de forma qualitativa por meio de dois instrumentos subjetivos: um questionário e a Escala Visual de Percepção Facial.

Resultados: Participaram 10 voluntários, obtendo redução de 1,7 no escore de impacto psicossocial; e de 2,1 no de percepção facial, bem como melhora na contagem do número de lesões, com 60% de melhora leve e 10% de melhora moderada.

Conclusões: Observou-se que o uso do LED se mostrou eficaz para ambos os grupos, tanto na autoavaliação da melhora, quanto na diminuição do número de lesões, podendo ser considerada uma terapêutica eficaz e segura para o manejo da acne.

Palavras-chave: acne vulgaris; fisioterapia; fototerapia; impacto psicossocial; lasers; luz; pele

Original Articles

Authors:

Felipe Ryuichi Yamada¹
Mônica Maciel da Silva¹
Katuscia Rosette Scasni²

¹ Universidade São Francisco, Bragança Paulista (SP), Brazil.

² Discipline of dermatologic physiotherapy da Universidade São Francisco - Bragança Paulista (SP), Brazil.

Correspondence to:

Felipe Ryuichi Yamada
Rua Aquidaban, 101
Jardim Santa Rita de Cássia
12914-270 Bragança Paulista, SP
Brasil.
E-mail: feliperyuichi@hotmail.com

Received on: 28/08/2017

Approved on: 28/12/2017

This study was performed at the Clinic School of Physiotherapy of the University São Francisco, Campus of Bragança Paulista - SP, Bragança Paulista (SP), Brazil.

Financial support: None.

Conflict of interests: None.

INTRODUCTION

Acne is one of the most common diseases of the sebaceous glands, affecting teenagers at the peak of the release of androgens, that regulate sebaceous secretion.^{1,2}

The objective of dermatological treatment is to reduce bacterial colonization and the obstruction of the pilosebaceous unit. Multiple treatment of proposed the management of this condition, through the use of systemic and topical medications.^{3,4}

A new treatment modality for acne is the use of LEDs (light emitting diode) with the wavelength of 405 nm (blue light with superficial absorption) to 940 nm (infrared light with deep absorption). The blue light is commonly indicated for the treatment of acne and is used by professionals because of their known bactericidal action; amber light is usually indicated by its anti-inflammatory action.^{5,6}

According to Meyer et al.,⁷ LED phototherapy, known as photo stimulation, is effective against acne due to the release of endogenous coproporphyrin type III, a photo sensitizing substance produced by the bacteria that cause acne, *P. Acnes*, according to the studies of Lee et al.⁸ and Ashkenazi et al.⁹ This explains the contraindication of the use of antibiotics in the treatment of acne with phototherapy, since it is dependent on the production of porphyrins by the bacteria.¹⁰

The energy from LED light acts directly on the cells (in the permeability of the cellular membrane), on its organelles (mitochondria), on its proteins (collagen and elastin) and omits physiological processes (ATP synthesis).⁷

The mechanism of action of LED in the treatment of acne consists in exciting large amounts of coproporphyrin III, produced and stored by *P. Acnes*, that generates photosensitivity against the bacteria. When in contact with the radiation of visible light, porphyrins enter an excited state, following the production and release of singlet oxygen that combines to the cellular membranes and destroys *P. Acnes*. This mechanism depends on the amount of porphyrins present (the higher the amount of porphyrins excited by the light, the higher the eradication of the bacteria will be) as well as the amount of photons.^{9,11}

Leyden et al.¹² observed in their clinical trial the blue light alone or associated to amber has a higher efficacy for the treatment of mild-to-moderate inflammatory acne in comparison to topical clindamycin; however, it was inferior to the association of clindamycin and benzoyl peroxide.

In the study by Ashkenazi et al.⁹ *P. Acnes* cultures were performed, finding comparable coproporphyrin III in both groups. The cultures were subsequently exposed to blue light (407–420 nm) for 24 hours and they noticed that a single exposure to the light is not enough for a viable reduction of *P. Acnes*, with 3 to 4 exposures needed (48 hours and 72 hours) to obtain this result. These observations suggested multiple irradiations of blue light (407–420 nm) in acne vulgaris patients can generate positive results.

In a clinical, randomized, double-blinded study by Papageorgiu et al.¹³, the group that used blue light associated to amber light had a 76% improvement of the inflamed lesions compared to the other groups, concluding that the synergistic action of the

blue and amber lights, with antibacterial and anti-inflammatory actions, respectively, is a safe and effective treatment for acne.

The objective of this study is to analyze the effects of blue LED associated to amber, comparing them to blue LED alone, for the treatment of acne.

METHODS

It is a clinical, randomized, blinded study. The research was conducted at Clínica Escola de Fisioterapia da Universidade São Francisco, Bragança Paulista Campus - SP, with the participation of two researchers and one assistant.

Fifteen volunteers with acne from grade II of the Holmes classification,⁶ with ages between 15 and 40 years were assessed for the study, according to the proposed inclusion criteria. The exclusion criteria were: acne grade I; topical treatment – benzoyl peroxide, retinoids, topical antibiotics, salicylic acid and azelaic acid – or systemic – antibiotics, contraceptives, antiandrogens and retinoids –; less than 5 inflammatory lesions; severe acne; or pregnancy in the last 3 months.

After selection, volunteers received and signed a written informed consent form, approved by the committee of ethics in research of the Universidade São Francisco under the number 1.757.915.

The patients were distributed in two randomized groups using numbered envelopes with a content unknown both by the volunteers and the examiner. Each individual selected an envelope that directed them to group 1 – isolated blue LED or to group 2 – blue LED associated to amber LED.

Two weekly sessions were performed for 3 weeks, with a total of 6 sessions and a duration of 16 minutes for group 1–blue LED and 32 minutes for group 2 –16 minutes of blue LED + 16 minutes of amber LED. On the first day of the treatment, the researchers filled out an evaluation form.

The evaluation was qualitative through two subjective tools: one questionnaire – Analysis of the Psychosocial Impact of Acne (AIPA),¹⁴ applied in the first and second last intervention – and the Visual Scale of Facial Perception (EVPF),¹⁵ applied on the first, third and fifth session, in which lesion count (CNL) was also performed.¹⁵ The variables obtained with the CNL were classified according to the improvement (reduction) or worsening (increase) in the number of lesions classifying them into worsening ($\leq -10\%$), no change ($-9-9$), mild improvement ($\geq 10-39\%$), moderate improvement ($\geq 40-59\%$) and great improvement ($\geq 90\%$), repeating the method used in the study by Papageorgiou et al.¹³

The procedure was performed with the patient in supine position, clean skin, with the application of the LEDs on eight points bilaterally of the frontal, zygomatic, masseter and chin regions, with the duration of 2 minutes per point.

The device used (Fluence[®], HTM eletrônica, Amparo, SP, Brazil), had a potency of $1500\text{mW} \pm 10\%$ divided into 3 500mW LEDs, with a wave length of $470\text{nm} \pm 10\%$ for the blue cluster and $617\text{nm} \pm 10\%$ for the amber cluster, dose of $180\text{J}/\text{cm}^2$ ($1.5\text{Watts} \times 120$ seconds) per point, resulting in a total dose of $1440\text{J}/\text{cm}^2$ in group 1 and $2880\text{J}/\text{cm}^2$ in group 2.

Data were inserted into a Microsoft Office Excel 2007 spreadsheet, performing the descriptive analysis with the calculation of the frequency (%) for qualitative variables (sex, phototype and grade of acne) and of mean and standard deviation for quantitative variables (age, AIPA, EVPF and CNL). The comparison of the variables was performed intergroup and intragroup with the Wilcoxon, Wilcoxon Mann Whitney and Fisher's exact tests, with the significance level of $p < 0.05$.

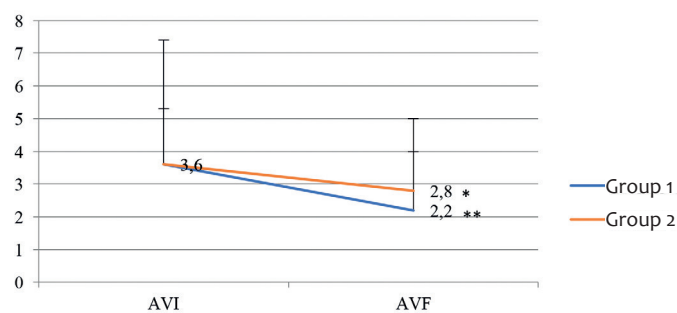
RESULTS

Data collection took place from November/December 2016 to March/April 2017. The initial sample had 15 patients, with the inclusion of 10 volunteers, with a mean age of 21.5 ± 1.4 years, with 50% ($n = 5$) female and 50% ($n = 5$) male. Among them, 30% ($n = 3$) had acne grade 2, and 70% ($n = 7$) acne grade 3, being statistically similar regarding the variables described and shown in table 1. In group 2, 2 participants did not show up, but both were replaced.

In the application of AIPA, group 1 had a reduction of the 1.4 score, even though a statistically significant difference was not observed between the initial and final steps (Wilcoxon $p = 0.454$). Group 2 had a score reduction of 0.8, with no statistically significant difference between the initial and final steps in the evaluation of the psychosocial impact (Wilcoxon $p = 0.387$). analyzing the 10 subjects, a reduction of 1.7 was seen in the score. Considering that the lower the score the lower the psychosocial impact, the comparison between the groups regarding this evaluation was not different in the initial steps (Wilcoxon Mann Whitney $p = 0.527$) and final (Wilcoxon Mann Whitney $p = 0.519$) either, comparisons are shown in graph 1.

The second tool used was EVPF, applied in three moments, beginning, during (middle) and end of the treatment.

Group 1 obtained values of AV1 5.8 ± 3.3 , AV2 4.6 ± 2.5 and AV3 4.2 ± 2.5 , observing the reduction of 1.6 while comparing AV1 and AV3, expressive improvement even though there was no statistically significant difference (Wilcoxon $p = 0.240$). Group 2 obtained values of AV1 5.8 ± 5.5 , AV2 4.4 ± 2.1 and AV3 3.2 ± 1.9 , observing a reduction of 2.6 comparing AV1 and AV3, an expressive improvement even though it was not significant either (Wilcoxon $p = 0.114$). Analyzing the 10 subjects for the values of AV1 5.8 ± 4.3 , AV2 4.5 ± 2.2 and AV3 3.7 ± 2.2 , a reduction of 2.1 was observed comparing AV1 and AV3. A more expressive reduction was seen in the score of the group 2 when compared to group 1, observing that throughout the treatment individuals of both groups obtained a gradual reduction in the values, considering that the lower the score, the more satisfied. The comparison between the groups regarding this evaluation, shown in graph 2, was not different in the initial step either (Wilcoxon Mann Whitney $p = 0.167$) nor final (Wilcoxon Mann Whitney $p = 0.750$).



GRAPH 1: Analysis of the Psychosocial Impact of Acne in group 1 and 2 Initial and final evaluation * $p > 0.05$ (Wilcoxon) ** $p > 0.05$ (Wilcoxon Mann Whitney)

TABLE 1: Characteristics of the subjects divided into group 1 and 2

	Group 1 n (%)	Group 2 n (%)	p value
Age			0.748 [†]
(mean + SD)	21.6 ± 1.8	21.4 ± 1.1	
Median (min-max)	22 (19-24)	21 (20-23)	
Sex			0.500*
Male	03 (60)	02 (40)	
Female	02 (40)	03 (60)	
Phototype			1.000*
2	03 (60)	02 (40)	
3	02 (40)	02 (40)	
4	0 (0)	10 (20)	
Acne grade			0.500*
2	02 (40)	01 (20)	
3	03 (60)	04 (80)	

[†] Wilcoxon test; * Fisher's exact test

Lesion count (CNL) was used for quantitative analysis, also in three moments at the beginning, during (middle) and end of treatment. Group 1 had values of AV1 15 ± 11.1 , AV2 15 ± 12.9 and AV3 11.6 ± 7.6 , and a plateau could be seen between AV1 and AV2, and a reduction of 3.4 when comparing AV1 to AV3, therefore, with no statistically significant difference (Wilcoxon $p = 0.671$). Group 2 had values of AV1 20.2 ± 9 , AV2 21.8 ± 5.3 and AV3 16.2 ± 3.1 ; an increase of 1.6 between AV1 and AV2 could be seen followed by a reduction of 3.8 when comparing AV1 to AV3, with no statistically significant difference either (Wilcoxon $p = 0.674$). Analyzing the 10 subjects in the values of AV1 17.6 ± 9.9 , AV2 18.4 ± 10 and AV3 13.9 ± 6 , observing an increase of 0.8 in the mean number of lesions between AV1 and AV2, with subsequent reduction of 3.7 when comparing AV1 to AV3, variables described and shown in table 2. The comparison between the groups regarding this evaluation was not different in the initial steps (Wilcoxon Mann Whitney $p = 0.671$) nor final (Wilcoxon Mann Whitney $p = 0.674$) either.

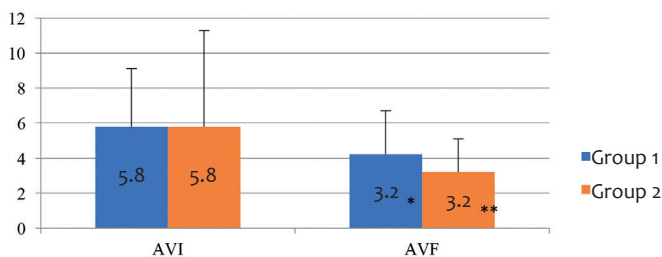
Regarding the number of lesions, the 10 subjects were classified in worsening 10% ($n = 1$), no change 20% ($n = 2$), mild improvement 60% ($n = 6$) and moderate improvement 10% ($n = 1$). Analyzing the individuals divided in their respective groups, 60% of them ($n = 3$) had a mild improvement for both groups; among them we highlight group 2 that obtained 20% ($n = 2$) of moderate improvement; however, 20% ($n = 1$) worsening. In group 1 40% ($n = 2$) of the participants did not improve, comparisons are shown in graph 3.

In figure 1 we highlight subject 1, from group 1, in the initial assessment (A) and final assessment (B), being evident the global reduction in the number of lesions and reduction of the erythema in the lesions suggesting reduction of inflammation. In figure 2 we highlight subject 3, from group 2, in the initial assessment (A) and final assessment (B), also showing reduction in the number of lesions and inflammation.

DISCUSSION

Regarding the patients age, in an epidemiological study conducted in the city of São Paulo,¹⁶ of 16,399 subjects evaluated, 433 had acne, being the most common dermatological condition in children and adults from 11 to 35 years of age. It was similar in this study, with an age range of 19 to 24 years.

The gender distribution of the patients in this study was 50% male and 50% female, differently from the population in



Graph 2: Visual Scale of Facial Perception in groups 1 and 2 Initial and Final evaluation * $p > 0.05$ (Wilcoxon) ** $p > 0.05$ (Wilcoxon Mann Whitney)

the mentioned article,¹⁶ where 63.2% ($n = 10,364$) were women upon dermatological examination of the subjects, possibly due to higher demand for health care. In turn, Lauerma et al.,¹⁷ study evaluated 2,201 18-year-old men and observed a prevalence of acne of 89.4% among them.

Even though the incidence of acne in darker phototypes is high, this study had only one phototype IV patient, who worsened with LED, indicating a possible difference in the response to treatment of darker phototypes, what could be explained by the presence of sebaceous glands with an increased production in comparison to light-colored skin.¹⁸

In an experimental, quantitative, study performed by Herrera et al.¹⁹ 19 individuals with acne were treated with blue LED, two weekly sessions for eight weeks, 15 minutes each session, with a significant reduction in the mean number of lesions (initial 45.1 and final 16.4), very expressive for grade II, followed by grade III, preferentially in lighter phototypes (phototype II); these authors also noticed an improvement, as in this study, demonstrating that the grades of acne have a tendency to regress with this treatment.

The number of sessions (six) used in this study was lower than what is seen in the literature. Meffert et al.²⁰ obtained acne and seborrhea improvement in men after 17 sessions of blue LED with a dose of 22KJ/cm².

Kawada et al.,²¹ utilized blue light in a clinical trial with 30 individuals, and reported a 64% reduction of acne lesions and reduction in the amount of *P. Acnes* in vitro, with 2 sessions per week for 5 weeks, with a fluence of 90mW/cm² and dose of 324J/cm². These authors correlated the use of blue light with the improvement in the number of lesions and its ability in reducing the amount of bacteria in the culture, observing its efficacy and tolerance among acne patients, suggesting phototherapy as a new treatment modality for acne.

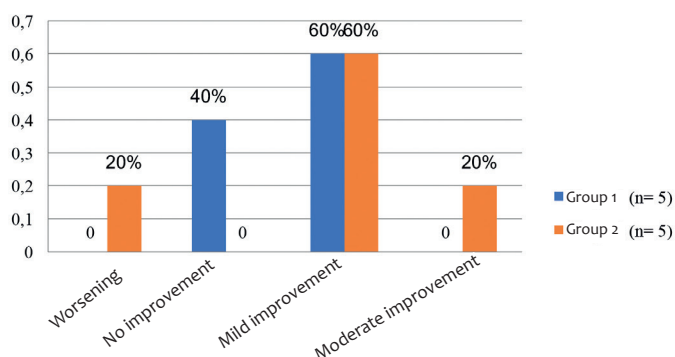
Arruda et al.²² compared the effects of blue light to the topical use of benzoyl peroxide 5% in 60 individuals with acne grade II and III, in a prospective, open, randomized and comparative study. They obtained a similar mean reduction of lesions.

Araújo et al.²⁴ studied the effects of lights, among them ambar light (590–630nm) in the healing of wounds in 25 wistar mice; with an experimental, controlled and randomized study, with daily treatments in 5 consecutive sessions of 6 minutes duration and energy of 3w. As results, the use of lights was effective for secondary intention wound healing, with highlight for amber light for providing better quality healing. Based on the findings by Araújo et al.,²⁴ we can infer that the group that received ambar light in this study might have obtained better results due to the effects of the light in the healing process, between the groups, concluding that both therapies are effective, with phototherapy causing a smaller number of adverse events.

The second light that appears in the literature is the red, known by its anti-inflammatory effects; however, most the studies have experimental groups with the combination of blue and red lights, supporting the hypothesis that the use of both lights with distinct effects and depth would be more effective for the treatment of acne.

TABLE 2: Lesion count in groups 1 and 2 initial and final assessment

Subject	Initial assessment	Final assessment	Initial assessment	Final assessment
1	34	25	17	13
2	8	8	17	15
3	16	10	18	14
4	8	6	13	19
5	9	9	36	20
Mean	15	11.6	20.2	16.2
Standard deviation	11.14	7.64	9.04	3.11
Median	9	9	17	15
Minimum	8	6	13	13
Maximum	34	25	36	20



GRAPH 3: Classification of the improvement of lesion count in groups 1 and 2

Differently from most studies, Na et al.,²³ performed a clinical, randomized, controlled and blind study with 28 volunteers, using only red LED on one side of the face, being the other side the control, twice a day for 8 weeks, during 15 minutes with a total of 112 sessions, with a final cumulative dose of 604.8J/cm², and obtained a 55% reduction in lesion count compared to the control group (19%) in the 8th week. We can conclude the red light is effective for the management of acne, suggesting that the number of exposures to the treatment is much more important than the dose employed to obtain a positive result, acting as an adjuvant for the blue light in the resolution of the inflammatory process.

In this study we aimed to observe if the effects found in the literature related to amber light can complement the effects produced by blue light, formulating a new more effective therapeutic approach for the treatment of acne.

In clinical practice it is common the use of active substances associated to LEDs in order to treat many functional and aesthetic dysfunctions; however, no studies that explain the mechanism of light interaction with the active substance on the skin were found, proving its efficacy and superiority. It is sugges-

ted that such association is an adapted type of photodynamic therapy, well established in the literature, as observed by other authors.²⁵⁻²⁷

Acne is a condition that can affect the individuals psychologically, what motivates professionals to look for decisive treatments, improvement in the quality of life of those affected and satisfaction with their own image. Many studies use the Visual Analog Scale (VAS) as an evaluation method in the attempt of quantifying the degree of satisfaction with the skin throughout treatment. Na et al.²³ obtained a significant reduction (3.9 to 1.8), when using the adapted VAS in comparison to the degree demonstrated by the control group in 28 individuals treated with red LED. In this study, the researchers opted to use the Visual Scale of Facial Perception (EVFP) for the subjective analysis of the individuals in the study, with a clear tendency to improvement even with no statistically significant results.

Massuia et al.¹⁵ noticed the qualitative response of nine male individuals through a clinical, prospective, randomized study. Using EVA as evaluation method, they obtained as a result the improvement of the individuals' perception regarding open and closed comedones, pain on extraction, aspect of the skin and quality of life. They also used Cadi (The Cardiff Acne Disability Index I) to evaluate the psychosocial impact of acne, noticing an improvement that ranged from 21.43 to 100% in the groups.

The variation of the data obtained when using EVFP and AIPA is due to the degree of impact that acne has on the individuals' lives, depending on how much each person cares individually about their acne in their daily activities in the questions evaluated with the AIPA questionnaire and the satisfaction with their face, evaluated by EVFP. Thus, as seen in the populational study by Tasoula et al.²⁸, with 1531 adolescents from 11 to 19 years of age, the grade of acne is directly proportional to the impact on the quality of life.

As the predominant clinical manifestation of acne are the inflammatory lesions, and with the intention of quantifying them, the researchers

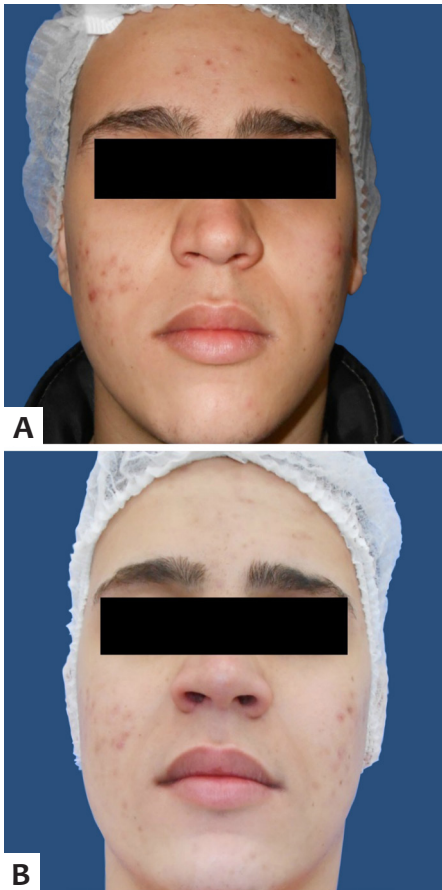


FIGURE 1:
Subject 1,
Group 1 (blue LED)
A - Initial assessment
B - Final assessment

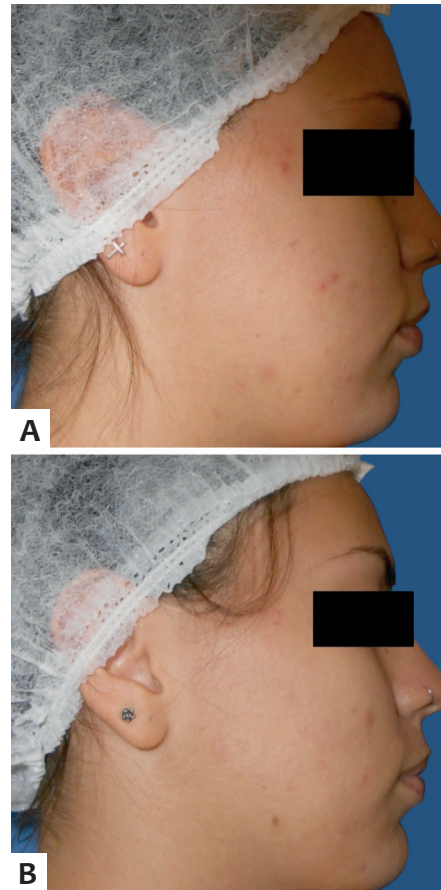


FIGURE 2:
Subject 3,
group 2 (blue + ambar
LED)
A - Initial assessment
B - Final assessment

Counted them, attributing improvement to the reduction of the lesions, as done in the studies by Papageorgiou et al.¹³ and Kawada et al.²¹

Lesion count is an effective and trustworthy method; however, some aspects can make counting difficult such as, for example, the presence of beard, which yields very questionable results at times. A technical way of observing differences is with the use of softwares that evaluate changes on the face, as the one used in the study by Estrela et al.²⁹ to evaluate the reduction of the angle and of the nasolabial fold in 24 patients treated with red LED for tissue laxity.

In future studies, it is suggested the increase in the weekly frequency of the treatment, since in all studies analyzed, LED was used daily for longer than 4 weeks, with significant results. In this study, however, there was resistance and little availability of the subjects to attend with a higher weekly and monthly frequency.

According to the AIPA and EVPF analysis, the patients did not improve significantly possibly because the impact depends on how much each individual cares about acne, this being a heterogenous datum among the subjects of the study.

As mentioned, lesion count can have some subjectivity,

and it is suggested to subdivide the face into areas (forehead, left and right sides) or use imaging softwares.

Observing the results obtained in the two groups, one can notice the improvement for both treatments (blue and blue/ambar), although with no statistical significance, possibly due to the size and heterogeneity of the sample and, above all, for the insufficient time of exposure to note differences. We suggest that future studies improve these aspects and also include one group ambar to evaluate its isolated efficacy in the treatment of acne.

CONCLUSIONS

Acne treatment with LED was effective either with blue light or with its association to ambar light, obtaining qualitative results with the reduction of AIPA and EVPF scores, and quantitative, with the reduction in the number of lesions as demonstrated by CNL. LED was shown to be an effective and safe therapy, with good results, with future studies being needed with a larger number of subjects, variability of the groups treated, increased number of sessions and weekly frequency of treatment to make possible the analysis of data with more confidence, in order to define its isolated effects and associations. ●

DECLARATION OF PARTICIPATION:**Felipe Ryuichi Yamada:**

Responsible for literature review and theoretical support, recruitment of the research subjects according to inclusion and exclusion criteria, evaluation of the subjects by lesion count, visual analogic scale of facial satisfaction, evaluation of the psychosocial impact of acne and photography; organization of the data collected; interpretation and discussion of the results obtained; formatting and adaptation to the journal's norms

Mônica Maciel:

Responsible for literature review and theoretical support, randomization of the research subjects into group 1 and 2; blue LED treatment for group 1 and blue + red LED treatment for group 2; interpretation and discussion of the results obtained and adaptation of the journal's norms

Katiuscia Scasni:

Responsible for the theme guidance helping in choosing the theme acne treatment; intervention with LEDs' use. Responsible for the methodological supervision of the research suggesting a study design, number of recruited subjects, statistical analysis and interpretation on the results obtained

REFERENCES

- Vivier AD, Mckee PH. Doenças das Glândulas Sebáceas, Sudoríparas e Apócrinas. In: Atlas de Dermatologia Clínica. São Paulo: Editora Manole; 1997. p. 1-10.
- Wolff K, Johnson RA, Saavedra AP. Distúrbios das Glândulas Sebáceas e Apócrinas. In: Dermatologia de Fitzpatrick: Atlas e Texto. New York: AMGH Editora Ltda; 2015. p. 2-7.
- Costa CS, Bagatin E. Evidence on acne therapy. São Paulo Med J. 2013;131(3):193-7.
- Hadade CSG, Rolino DF, Oliveira MMC, Nadal M, Braga T. Distúrbios das secreções sebácea, écrina e apócrina. In: Petri V. Dermatologia Prática. Rio de Janeiro: Guanabara Koogan; 2009. p. 35-44.
- Barolet D. Light-emitting diodes (LEDs) in Dermatology. Semin Cutan Med Surg. 2008;27(4):227-38.
- Holmes HS. Acne, rosácea e distúrbios relacionados. In: Soutor C, Hordinsky M. Dermatologia Clínica (Lange). Porto Alegre: AMGH; 2014. p. 138-144.
- Meyer PF, Araújo HG, Carvalho MGF, Tatum BIS, Fernandes ICAG, Ronzio AO, et al. Assessment of effects of LED on skin wound healing in Wistar rats. Fisioterapia Brasil. 2010;11(6):428-32.
- Lee WS, Shalita AR, Poh-Fitzpatrick MB. Comparative studies of porphyrin production in propionibacterium acnes and propionibacterium granulosum. J Bacteriol. 1978;133(2):811-15.
- Ashkenazi H, Malik Z, Harth Y, Nitzan Y. Eradication of Propionibacterium acnes by its endogenous porphyrins after illumination with high intensity blue light. FEMS Immunol Med Microbiol. 2003;35(1):17-24.
- Filgueira AL, Duque HE, Azulay RD. Tratamento pelas radiações. In: Azulay RD, Azulay DR, Azulay-Abulafia L. Dermatologia - Sexta edição revisada e atualizada. Rio de Janeiro: Guanabara Koogan; 2013. p. 691-697.
- Elman M, Lask G. The role of pulsed light and heat energy (LHE) in acne clearance. J Cosmet Laser Ther. 2004;6(2):91-5.
- Leyden JJ, Hickman JG, Jarratt MT, Stewart DM, Levy SF. The Efficacy and safety of a combination benzoyl peroxide/clindamycin topical gel compared with benzoyl peroxide alone and a benzoyl peroxide/erythromycin combination product. Journal Cutan Med Surg. 2001;5(1):37-42.
- Papageorgiou P, Katsambas A, Chu A. Phototherapy with blue (415 nm) and red (660 nm) light in the treatment of acne vulgaris. Br J Dermatol. 2000;142(5):973-78.
- Grando LR, Horn R, Cunha VT, Cestari TF. Translation, cultural adaptation and validation for Brazilian Portuguese of the Cardiff Acne Disability Index instrument. An Bras Dermatol. 2016;91(2):180-86.
- Massuia FAO, Silva DF, Santos FMR, Durante RF, Trofino MR, Costa EL, et al. Physical therapy in open and closed comedones in acne vulgaris. Revista Inspirar. 2011;3(1):31-40.
- Bertanha F, Nelumba EJ, Freiberg AK, Samorano LP, Festa Neto C. Profile of patients admitted to a triage dermatology clinic at a tertiary hospital in São Paulo, Brazil. An Bras Dermatol. 2016;91(3):318-25.
- Laueremann FT, Almeida Junior HL, Duquia RP, Souza PRM, Breunig JA. Acne scars in 18-year-old male adolescents: a population-based study of prevalence and associated factors. An Bras Dermatol. 2016;91(3):291-95.
- Herrera SDSC, Mota JR, Chaves SP, Ueda TK, Rezende AAB, editors. 1º Congresso Brasileiro de Fisioterapia Dermato Funcional, 2012 Nov 1-6; Recife, Pernambuco. Brasil. to da acne vulgar. Congresso Brasileiro de Fisioterapia Dermato Funcional. 2012.1-5.
- Alchorne MMA, Abreu MAMM. Dermatology in black skin. An Bras Dermatol. 2008;83(1):7-20.
- Meffert h, Scherf HS, Sonnichsen N. Treatment of acne vulgaris with visible light. Dermatol Monstsschr. 1987;173(11):678-9. Apud Paschoal FM, Ismael APPB. A ação da luz no tratamento da acne vulgar. Surg Cosmet Dermatol. 2010;2(2)117-23.
- Kawada A, Agarane Y, Kameyama H, Sangen Y, Tezuka T. Acne phototherapy with a high-intensity, enhanced, narrowband, blue light source: an open study and in vitro investigation. J Dermatol Sci. 2002;30(2)129-35.
- Arruda LHF, Kodani V, Bastos Filho A, Mazzaro CB. A prospective, randomized, open comparative study to evaluate safety and efficacy of blue light treatment versus topical benzoyl peroxide 5% formulation in patients with acne grades II and III. An Bras Dermatol. 2009;84(5):463-8.
- Na Ji, Suh DH. Red Light Phototherapy Alone Is Effective for Acne Vulgaris: Randomized, Single-Blinded Clinical Trial. Dermatol Surg. 2007;33(10):1228-33.
- Araujo HG, Silva RMV, Canela PM, Silva NF, Santos-Filho FC, Ronzio AO, et al. Different Wavelengths of LEDs on Cutaneous Wound Healing in Wistar Rats. Journal of Basic & Applied Sciences. 2015;11:389-96.
- Torezan L, Festa Neto C, Niwa ABM. Photodynamic therapy in dermatology: basic principles and clinical use. An Bras Dermatol. 2009;84(5):445-59.
- Issa MCA, Manela-Azulay M. Photodynamic therapy: a review of the literature and image documentation. An Bras Dermatol. 2010;85(4):501-11.
- Barbaric J, Abott R, Posadzki P, Car M, Gunn LH, Layton AM, et al. Light therapies for acne. Cochrane Database Syst Rev. 2016; 9:CD007917.
- Tasoula E, Gregoriou S, Chalikias J, Lazarou D, Danopoulou I, Katsambas A, et al. The impact of acne vulgaris on quality of life and psychic health in young adolescents in Greece. Results of a population survey. An Bras Dermatol. 2012;87(6):862-9.
- Estrela JV, Duarte CCF, Almeida DNA, Araruna VR, Silva RMV, Cavalcanti RL, et al. Effect of tissue facial led flaccidity. Revista Científica da Escola da Saúde UP. 2014;3(2):29-36.