

Original Articles

Autor:

Emerson Vasconcelos de Andrade Lima¹

¹ Cosmiatry Coordinator at Santa Casa de Misericórdia do Recife - Recife (PE), Brasil.

Correspondence to:

Emerson Vasconcelos de Andrade Lima
Avenida Governador Agamenon Magalhães 2939, apt. 401-404 / Espinheiro
E-mail: emersonderma@terra.com.br

Received on: 04/04/2017

Approved on: 20/07/2017

Study conducted at the Department of Dermatology, Santa Casa de Misericórdia de Recife – Recife (PE), Brasil.

Financial support: None.

Conflict of interests: None.

Percutaneous induction of collagen with needles (IPCA®) associated with Pulsed radiofrequency with multineedles (RFPM®) in the management of depressed acne scars: treatment protocol

Indução percutânea de colágeno com agulhas (IPCA®) associada a radiofrequência pulsada com multiagulhas (RFPM®) na condução de cicatrizes de acne deprimidas: protocolo de tratamento

DOI: <http://dx.doi.org/10.5935/scd1984-8773.20179304>

ABSTRACT

Introduction: Depressed acne scars always arise as a therapeutic challenge. Fractional lasers, surgical approaches and chemical peels have attempted to offer acceptable aesthetic results, however it is still difficult to determine the ideal treatment.

Objective: To evaluate the efficacy of Percutaneous Collagen Induction with needles (IPCA®) associated with Pulsed Radiofrequency with Multineedles (RFPM®) in depressed acne scars.

Methods: Retrospective study of the safety and effectiveness of the technique through the evaluation of results based on a satisfaction questionnaire answered by the patients and the clinical and photographic assessment carried out by a dermatologist.

Results: Thirteen patients (aged between 21 and 37 years) who had undergone the combination treatment were evaluated. All (100%) reported satisfaction with the outcomes, while in the comparative evaluation of photographs yielded an improvement rate of 50% in 2 patients and of 70% in 6 patients.

Conclusion: This new therapeutic proposal arises as an alternative in the treatment of depressed acne scars.

Keywords: scars; pulsed radiofrequency treatment; collagen

RESUMO

Introdução: As cicatrizes de acne deprimidas apresentam-se sempre como um desafio terapêutico. Lasers fracionados, abordagens cirúrgicas e peelings químicos têm tentado oferecer resultados cosméticos aceitáveis, mas continua difícil a escolha do tratamento ideal.

Objetivo: Avaliar a eficácia da indução percutânea de colágeno com agulhas associada a radiofrequência pulsada com multiagulhas em cicatrizes de acne deprimidas.

Métodos: Estudo retrospectivo da segurança e efetividade da técnica mediante avaliação dos resultados por aplicação de questionário de satisfação aos pacientes e julgamento clínico e fotográfico pelo dermatologista.

Resultados: Foram avaliados 13 pacientes com idade entre 21 e 37 anos, submetidos à associação, 100% dos quais relataram satisfação com os resultados, enquanto na avaliação comparativa das fotografias o índice de melhora foi de 50% em dois pacientes e de 70% em seis pacientes.

Conclusão: Essa nova proposta terapêutica se apresenta como alternativa ao tratamento de cicatrizes de acne deprimidas.

Palavras-chave: cicatrizes; tratamento por radiofrequência pulsada; colágeno

INTRODUCTION

Depressed acne scars always present as a therapeutic challenge. We commonly see significant changes in color, texture and relief due to an inflammatory process that causes destruction of the epidermis, dermis and, sometimes, with important consumption of the subcutaneous tissue.¹ Surgical techniques and technologies have been used in the management of these difficult-to-treat lesions, however, due to the different presentations, we do not have a gold-standard therapeutic option.¹ Percutaneous collagen induction (PCI) with needles proposes the substitution of the cicatricial collagen for a new collagen at the same time that it preserves the epidermis of the area treated. The scars are broken down by a roller with 192 microneedles on average that, after many passes on the area of interest, results in the formation of micro channels, bleeding and an inflammatory cascade that induces the remodeling of the scar tissue.²⁻⁴ With the intention to optimize the results obtained with PCI, the author has been using the combination of other techniques before the use of the needle roller. Based on the findings from treatment of eyelid laxity and in old stretch marks, the author initiated an investigation looking for the applicability of fractional radiofrequency micro-needling (FRM) in depressed acne scars.^{5,6} In FRM, the random fractional, high frequency energy applied on the skin results in dermal regeneration at the level of the interface papillary-reticular, through the stimulation of fibroblasts with subsequent synthesis of collagen and elastic fibers, as well as epidermal regeneration generated by keratinocyte migration. This study is the result of the observation of the association of PCI and FRM. Here, it is proposed an innovative approach for the treatment of depressed acne scars, based on the sub-ablative energy, with electrodes with multiple needles connected to a radioelectrosurgery device. This technique, performed accurately and isolated, does not compromise the tissue surrounding the vaporized micropoints and causes a significant impact on the tissue, enabling the stimulus for a new collagen (Figure 1). Electrodes known as Lima 2, Lima 4 e Lima 8 are needed for the execution of FRM, named after the author, made up of two, four or eight tungsten needles, respectively, with a diameter of 100 thousandth of millimeters, identical weight and length and oriented in a parallel fashion, with the objective of reaching the

same depth. With a length of 2.5mm, these needles pass through the epidermis and act in the dermis, stimulating the contraction and the renovation of the collagen.

METHODS

In this retrospective study of the safety and efficacy of the combined techniques, the records of 13 patients with depressed acne scars on the face, treated at Santa Casa de Misericórdia do Recife with the combination of PCI and FRM, performed in the outpatient setting by the same physician, using the same protocol, between January and December 2016 were. Photographic records were done with the same digital camera in identical environmental conditions, immediately before and two months after a single treatment. The study was conducted according to the ethical criteria of the Helsinki declaration. After disinfection with chlorhexidine 1%, the area was infiltrated with lidocaine 2% without vasoconstrictor 1:2 saline 0.9% solution, respecting the maximum safe dose according to the weight of each patient. Then protocol was initiated with FRM. For its execution, the device FRAXX[®] (Loktal Medical Electronics, São Paulo, Brazil Anvisa n. 10362610008) was used in the single pulse mode. The patients in this group were treated with the setting CUT, with potency 30 and Active 30', using the electrode Lima 8 following the trajectory of the scars, without overlapping. Subsequently and on the same surgical step, PCI was performed using a 2.5mm roller (Dr. Roller[®]-Mooohan Enterprise CO., Gyeonggi-do, South Korea, Anvisa n. 80669600001) looking for a uniform purpura pattern.

RESULTS

Seven female patients and six male patients, aged 21-37 years, were included in this investigation. The phototypes were III to V, according to the classification of Fitzpatrick. All patients were satisfied with the results, shown in the questionnaires as good and very good, according to the norms proposed. In the clinical and comparative evaluation of the photographs from before the treatment and two months after, the improvement rates were: 50% = good in 2 patients and 70% = very good in 6 patients (Figure 2). Pain during treatment was considered bear-

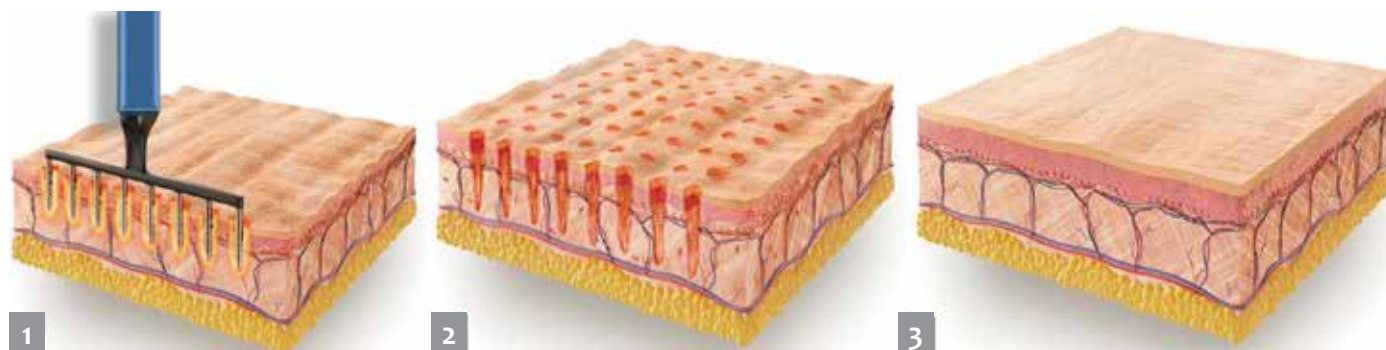


FIGURE 1: 1. Electrode Lima 8 acting on the skin 2. Immediately after fractional radiofrequency micro-needling 3. Regeneration of the skin 30 days after treatment

able, and tissue regeneration was seen between 5 to 7 days, with return to normal activities in the same time.

There was no infection, dyspigmentation or unsightly scars observed in this group after the treatment. Edema and er-

ythema were as expected for a surgical intervention, with spontaneous regression between 7 to 10 days.

DISCUSSION

Even with the wide range of therapeutic options currently available for the treatment of scars, we still see mild or dissatisfactory improvement in many patients. Micro-needling has been offering promising results for the correction of acne scars, stretch marks, laxity and wrinkles.^{7,8} In this investigation, we proposed the combination of two techniques that use microneedles in an innovative intervention, following a protocol by the author for the correction of difficult-to-treat scars. The results obtained allow us to conclude that:

FRM is a promising therapy for the treatment of depressed acne scars, when associated to PCI.

The results obtained are reproducible by qualified professionals using the methodology described in this article.

The quick return to normal activities and the few side effects seen in the group assessed encourage the author to recommend the inclusion of this new proposition in the wide therapeutic arsenal already available.

The procedure demands training and is essentially operator-dependent. The operator needs to be adequately trained and have all the basic knowledge to achieve the best results.

We suggest the evaluation of the protocol here established in other groups to confirm the results and conclusions here presented. ●

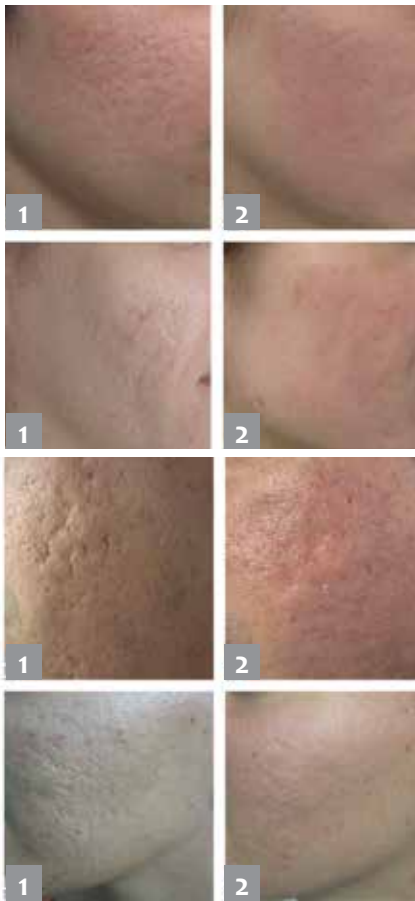

FIGURE 2: Patients before the combination treatment with PCI and FRM (1) and 60 days after the treatment (2)

DECLARATION OF PARTICIPATION:

Emerson Vasconcelos de Andrade Lima

Study conception and planning. Preparation and wording of the manuscript. Data collection, analysis and interpretation.

REFERENCES

1. Kadunc BV Almeida ART. Surgical Treatment of Facial Acne Scars Based on Morphologic Classification: A Brazilian Experience. *Dermatol Surg*. 2003; 29(12):1200-9
2. Lima EVA, Lima MA, Takano D. Microagulhamento: estudo experimental e classificação da injúria provocada. *Surg Cosmet Dermatol*. 2013;5(2):110-4.
3. Lima EA. Associação do microagulhamento ao peeling de fenol: uma nova proposta terapêutica em flacidez, rugas e cicatrizes de acne da face. *Surg Cosmet Dermatol* 2015;7(4):328-31.
4. Fabroccini G, Fardella N, Monfrecola A, Proietti I, Innocenzi D. Acne scar treatment using skin needling. *Clin Exp Dermatol*. 2009; 34(8):874-9.
5. Lima E A . Radiofrequência pulsada com multiagulhas: uma proposta terapêutica em rugas, flacidez e pigmentação periorbital. *Surg Cosmet Dermatol* 2015;7(3):223-6.
6. Lima EVA .Radiofrequência pulsada com multiagulhas (RFPM®) no tratamento de estrias atroficas. *Surg Cosmet Dermatol* 2016;8(3):242-5.
7. Fernandes D. Minimally invasive percutaneous collagen induction. *Oral Maxillofac Surg Clin North Am*. 2005; 17(1):51-63.
8. Aust MC1, Fernandes D, Kolokythas P, Kaplan HM, Vogt PM. Percutaneous Collagen Induction therapy -an alternative treatment for scars, wrinkles and skin laxity. *Plast Reconstr Surg*. 2008; 121(4):1421-9.