

## Case Report

### Authors:

Luiz Eduardo Garcia Galvão <sup>1</sup>

<sup>1</sup> Dermatologist Physician, Instituto do Câncer do Ceará and at the Centro de Dermatologia Dona Libânia; Dermatology discipline instructor, Universidade Christus (UNICHRISTUS), Fortaleza (CE), Brazil.

### Correspondence:

Luiz Eduardo Garcia Galvão  
Avenida Engenheiro Santana  
Júnior, 3000, sala 1405 – Edifício  
Central Park  
60192205 – Fortaleza – CE  
**E-mail:** lgalvaodermato@yahoo.com.br

Received on: 17/08/2016

Data de aprovação: 01/09/2016

This study was performed at a private practice in Fortaleza (CE), Brazil.

**Conflict of interests:** Dr. Luiz Galvão EduarGarcia acted as a lecturer for LEO Pharma and Galderma Laboratórios

**Financial support:** none

# Daylight photodynamic therapy: clinical and aesthetic benefit with repeated sessions for facial actinic keratoses

*Terapia fotodinâmica com luz do dia: benefício clínico e estético com sessões repetidas para ceratoses actínicas faciais*

DOI: <http://dx.doi.org/10.5935/scd1984-8773.201683103>

## ABSTRACT

Daylight photodynamic therapy (daylight-PDT) has been used in the treatment of facial and scalp actinic keratoses (AKs) as an alternative of similar efficacy but with greater tolerance than the conventional form of the procedure (c-PDT). Twelve patients performed 2 sessions of daylight-PDT with 30-day intervals without major adverse events. Improvement of AKs and photorejuvenation were observed. Repeated sessions of daylight-PDT are well tolerated and may increase clinical and aesthetic benefit in patients with face and scalp AKs.

**Keywords:** Keratosis, Actinic ; Photochemotherapy; Rejuvenation

## RESUMO

A terapia fotodinâmica com luz do dia tem sido utilizada no tratamento das ceratoses actínicas de face e de couro cabeludo como alternativa de eficácia semelhante, mas com maior tolerância do que a forma convencional do procedimento. Doze pacientes realizaram duas sessões de terapia fotodinâmica com luz do dia com intervalos de 30 dias sem efeitos adversos importantes. Foi observada melhora das ceratoses actínicas e fotorrejuvenescimento. Sessões repetidas de terapia fotodinâmica com luz do dia são bem toleradas e podem aumentar o benefício clínico e estético em pacientes com ceratoses actínicas de face e de couro cabeludo.

**Palavras-chave:** ceratose actínica; fotoquimioterapia; rejuvenescimento

## INTRODUCTION

Conventional Photodynamic Therapy (c-PDT) with methyl aminolevulinate cream and red light irradiation three hours after, has been successfully performed for face and scalp actinic keratoses (AKs), with complete response rates that may reach up to 90% within three months, after one or two sessions. A secondary aesthetic effect could also be observed, with the improvement of pigmentation, erythema, roughness, cutaneous paleness, telangiectasia and wrinkles. However, the painful sensibility and intense local cutaneous reactions following the procedure may limit the indication for new sessions.

Daylight Photodynamic Therapy (DLPDT) consist in a recent therapeutic alternative to the conventional method, with similar efficacy in the treatment of Grade I and II facial and scalp AKs. The absence of painful sensibility and intense local cutaneous reactions following the procedure favor the indication of

repeated sessions of DLPDT, which may be necessary in cases of recurring lesions or in patients who have AKs in greater number or extension. The authors have reported 12 cases of patients who were treated in a private practice and have undergone two DLPDT sessions, with a 30-day interval, and have observed that, in addition to the reduction in the number of AKs, there was an improvement in clinical parameters of photoaged skin.

## METHODS

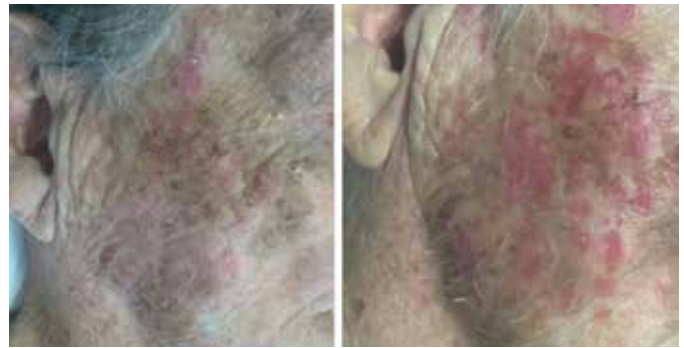
Twelve patients (eight men and four women) with ages ranging between 38 and 91 years, with at least three Grade I and II facial AKs each and signs of cutaneous aging, underwent two DLPDT sessions, 30 days apart from each other. Half of these patients had previously undergone c-PDT, however, they had not undergone any type of cosmetic or laser treatment in the six months preceding the aforementioned therapy.

The sessions took place in a private clinic in the city of Fortaleza, Ceará, Brazil, on days with bright sunlight or with few clouds in the sky, between 7am and 3pm. On the day of the DLPDT procedure, after the facial cleansing with saline solution with gauze, curettage of the facial AKs was performed, followed by the application of FPS50+ chemical sunscreen lotion (Actinica®, Galderma, France) on the face and other exposed regions. Next, approximately 1g of a thin layer of 16% methyl aminolevulinate cream (Metvix®, Galderma, France) was applied throughout the face, followed by exposure to the open air, under the shade for two hours. Following, the methyl aminolevulinate cream was removed and FPS50+ chemical sunscreen lotion was applied, the patient was released and instructed to maintain a rigorous regime of sunscreen application at home. The procedure was repeated after 30 days.

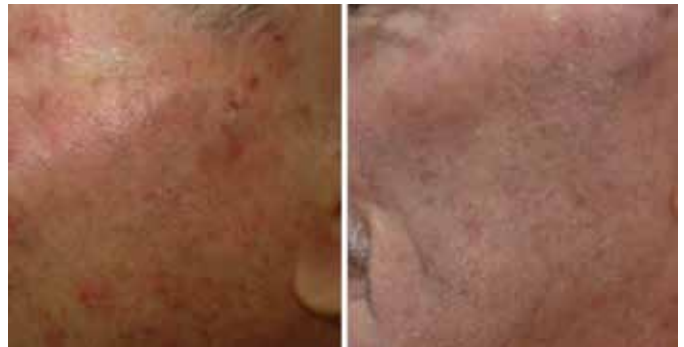The number of AKs was evaluated clinically and through digital photographs taken before the DLPDT sessions, on the day of the follow-up visit, and 90 days after the first procedure. A AK lesion was defined as a small keratotic, isolated plaque, with adherent scales, well delineated, located in the area of chronic photo exposure. All patients were also similarly evaluated for overall facial photoaging, diffuse pigmentation, fine wrinkles, facial paleness, roughness, erythema and telangiectasias.

## RESULTS

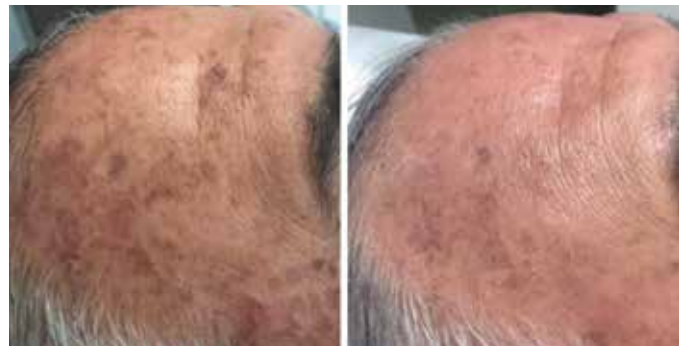All 12 patients have followed through the end of the treatment. During exposure to open air, there was no report of pain nor were observed intense local cutaneous reactions. The most common side effects were mild pruritus and slight erythema on the areas corresponding to the AK lesions that were clinically visible (Figure 1). Regarding the results of the treatment, nine patients were satisfied even before the second session, and none were dissatisfied 90 days after the first session of DLPDT. Satisfaction regarding the clinical improvement of AK lesions and cutaneous rejuvenation were observed in all patients three months after undergoing two sessions of DLPDT, when the authors could observe an improvement in telangiectasias (Figure 2), pigmentation (Figure 3), roughness and erythema (Figure 4), and fine wrinkles (Figure 5).



**FIGURE 1:** Erythema post-procedure corresponding to clinically visible AK lesions on the right malar region



**FIGURE 2:** Improvement of telangiectasias

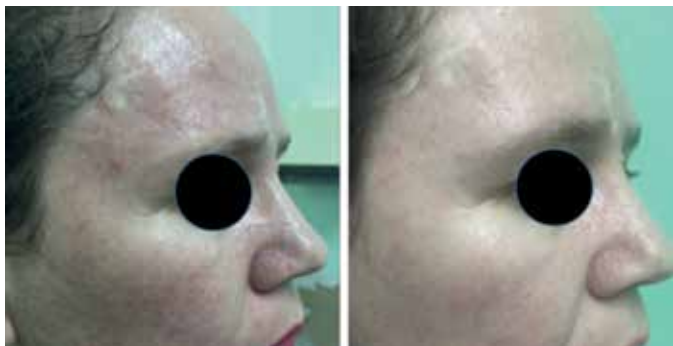

**FIGURE 3:** Improvement of AKs and pigmentation after two DLPDT sessions

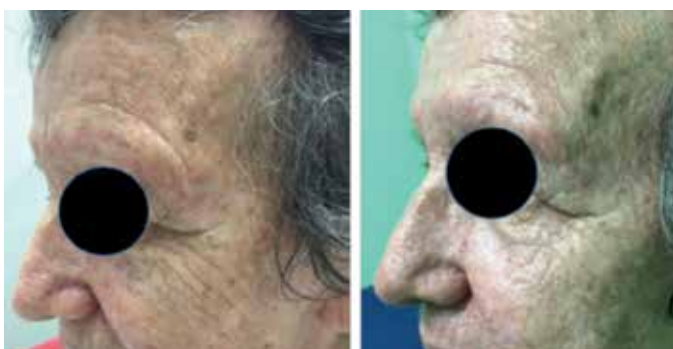## DISCUSSION

The absence of painful sensitivity and intense local cutaneous reactions in the DLPDT sessions permits that, contrary to the conventional form of PDT, the procedure be repeated with greater frequency. Taking into account the chronic and recurring characteristics of the AKs, the possibility of performing a procedure that allows a practically painless treatment of extensive areas of the face and the scalp and still produce secondary aesthetic gain, makes DLPDT a first choice in the treatment of AKs.

The effect regarding aesthetic improvement with c-PDT had already been demonstrated in previous studies. Regarding DLPDT, it was possible to observe that a second session performed after 30 days, aside from having an additional effect in



**FIGURE 4:** Improvement of telangiectasias, roughness and facial erythema



**FIGURE 5:** Improvement of fine wrinkles

the treatment of multiple AKs, yielded overall rejuvenation in all patients, thus contributing to the increase in satisfaction about the procedure.

New forms of photodynamic therapy have been performed with microneedling and ablative fractional laser aiming to increase the penetration of the methyl aminolevulinate cream and to improve the efficacy in treating AKs and in rejuvenation. The possibility of repeated sessions of DLPDT may yield a similar effect without the use of laser, LED or any other equipment.

In Brazil, this DLPDT procedure, which can be performed practically throughout the year, allows greater patient compliance by allowing repeated treatments of extensive areas of AKs with minimal discomfort, without disrupting the daily routine of the patient, and with high efficacy and secondary aesthetic gain.

## CONCLUSION

Repeated sessions of DLPDT may be performed in such a manner that they are virtually painless and with the added gain of clinical efficacy in patients who have multiple AKs on their face and scalp. Secondary aesthetic gain may also be observed in a more evident manner with at least two sessions of DLPDT, which may be equivalent to the conventional form of PDT, or in combination with ablative methods, however offering the advantage of great tolerance to the procedure. ●

## REFERENCES

1. Szeimies RM1, Karrer S, Radakovic-Fijan S, Tanew A, Calzavara-Pinton PG, Zane C, et al. Photodynamic therapy using topical methyl 5-aminolevulinate compared with cryo therapy for actinic keratosis: a prospective, randomized study. *J Am Acad Dermatol*. 2002;47(2):258–62.
2. Torezan LA. Estudo da pele do campo cancerizável antes e após a terapia fotodinâmica através dos métodos clínicos, histopatológicos e imunohistoquímicos. São Paulo (SP): Universidade de São Paulo; 2011. 152 p.
3. Braathen LR1, Morton CA, Basset-Seguin N, Bissonnette R, Gerritsen MJ, Gilaberte Y, et al. Photodynamic therapy for skin field cancerization: an international consensus. *International Society for Photodynamic Therapy in Dermatology. J Eur Acad Dermatol Venereol*. 2012;26(9):1063–6.
4. Rubel DM, Spelman L, Murrell DF, See JA, Hewitt D, Foley P, et al. Daylight photodynamic therapy with methyl aminolevulinate cream as a convenient, similarly effective, nearly painless alternative to conventional photodynamic therapy in actinic keratosis treatment: A randomized controlled trial. *Br J Dermatol*. 2014;171(5):1164–71.
5. Wiegell SR, Haedersdal M, Philipsen PA, Eriksen P, Enk CD, Wulf HC. Continuous activation of PpIX by daylight is as effective as and less painful than conventional photodynamic therapy for actinic keratoses; a randomized, controlled, single-blinded study. *Br J Dermatol*. 2008;158(4):740–6.
6. Duncan KO, Leffel DJ. Epithelial precancerous lesions. In: Freedberg IM, Eisen AZ, Wolff K, Austen KF, Goldsmith LA, Katz S, editors. *Fitzpatrick's Dermatology in General Medicine*. 6th ed. New York: Mc-Graw-Hill; 2003. p.719–36.
7. Morton CA, Wulf HC, Szeimies RM, Gilaberte Y, Basset-Seguin N, Sotiriou E, et al. Practical approach to the use of daylight photodynamic therapy with topical methyl aminolevulinate for actinic keratosis: A European consensus. *J Eur Acad Dermatol Venereol*. 2015;29(9):1718–23.
8. MCA, Pineiro-Maceira J, Vieira MTC, Olej B, Mandarim-Lacerda CA, Luiz RR, Azulay MM. Photorejuvenation with topical Methyl aminolevulinate and red light: a randomized, prospective, clinical, histopathologic and morphometric study. *Dermatol Surg*. 2010;36(1):39–48.
9. Clementoni MT, B-Roscher M, Munavalli GS. Photodynamic photorejuvenation of the face with a combination of microneedling, red light, and broadband pulsed light. *Lasers Surg Med*. 2010;42(2):150–9.
10. Haedersdal M, Katsnelson J, Sakamoto FH et al. Enhanced uptake and photoactivation of topical methyl aminolevulinate after fractional CO<sub>2</sub> laser pretreatment. *Lasers Surg Med*. 2011;43(8):804–13.