

# Pulsed radiofrequency with multineedles for earlobe aging treatment

Radiofrequência pulsada com multiagulhas (RFPM®) no tratamento do envelhecimento do lóbulo da orelha

DOI: <http://dx.doi.org/10.5935/scd1984-8773.20168403>

## ABSTRACT

**Introduction:** Numerous techniques have been described to treat the earlobe aging. Surgical and nonsurgical methods as peelings, CO<sub>2</sub> laser and fillings have been proposed to produce collagen remodeling.

**Objective:** The objective of this retrospective clinical study was to evaluate the effectiveness of microneedling assisted radiofrequency for earlobe aging.

**Methods:** Retrospective study of the technique's safety and effectiveness through the evaluation of the results with the application of a satisfaction questionnaire to patients and of the analysis of clinical outcomes by independent dermatologists.

**Results:** Twelvy patients aged between 48 and 67 years who underwent the technique were evaluated. One hundred percent of the patients reported satisfaction with the results, whereas in the comparative evaluation of the photographs carried out by two independent dermatologists the rate of improvement was 75% in four patients, 100% in eight patients. Post-inflammatory hyperpigmentation was observed ten to 15 days after the treatment in five patients, though it was reversed after clinical treatment.

**Conclusion:** This new procedure emerges as an alternative treatment for earlobe aging.

**Keywords:** ear cartilage; pulsed radiofrequency treatment; rejuvenation

## RESUMO

**Introdução:** Várias técnicas vêm sendo descritas para o tratamento do envelhecimento do lóbulo da orelha. Métodos cirúrgicos e não cirúrgicos, como *peelings*, laser fracionado de CO<sub>2</sub>, e preenchedores vêm sendo propostos com o intuito de produzir remodelamento de colágeno dessa região.

**Objetivo:** O objetivo deste estudo clínico retrospectivo foi avaliar a eficácia da radiofrequência pulsada com multiagulhas (RFPM®) no rejuvenescimento do lóbulo da orelha.

**Métodos:** Estudo retrospectivo da segurança e efetividade da técnica mediante avaliação dos resultados por aplicação de questionário de satisfação aos pacientes e julgamento dos resultados clínicos por dermatologistas independentes.

**Resultados:** Foram avaliados 12 pacientes com idade entre 48 e 67 anos, submetidos à técnica, 100% dos quais relataram satisfação com os resultados, enquanto na avaliação comparativa das fotografias por dois dermatologistas independentes o índice de melhora foi de 75% em quatro pacientes e 100% em oito pacientes. A hiperpigmentação pós-inflamatória foi observada entre dez e 15 dias após o tratamento em cinco pacientes, tendo sido revertida após tratamento clínico.

**Conclusão:** Esse novo procedimento se apresenta como alternativa ao tratamento do envelhecimento do lóbulo da orelha.

**Palavras-chave:** cartilagem da orelha; tratamento por radiofrequência pulsada; rejuvenescimento

## Original Articles

### Author:

Emerson Vasconcelos de Andra de Lima<sup>1</sup>

<sup>1</sup> Coordinator, Cosmiatry and Dermatologic Surgery, Santa Casa de Misericórdia do Recife - Recife (PE), Brazil.

### Correspondence:

Emerson Vasconcelos de Andrade Lima  
Av. Agamenon Magalhães, 2939 / Sl. 402-404  
Cep 52020-000 – Recife (PE), Brazil  
Email: [emersonderma@terra.com.br](mailto:emersonderma@terra.com.br)

Received on: 23/06/2015

Approved on: 20/03/2016

This study was performed at the Santa Casa de Misericórdia de Recife and at a private practice - Recife (PE), Brazil.

**Financial support:** None

**Conflict of interests:** None

## INTRODUCTION

Aligned with the natural process of aging, the aging of the earlobe is characterized by sagging, excess skin, volume loss and the onset of rhytids. These alterations, secondary to the degeneration of this anatomical segment's tissue, cause the expansion of the earring orifice, a situation that can many times be worsened by the use of heavy adornments over the years, or even by traumas that form partial or total clefts in the earlobe.<sup>1,2</sup>

Surgical and non-surgical alternatives are available aimed at restoring the damage caused to this region, isolatedly or in association, observing the diversity of unsightly and progressive signals.<sup>1,2</sup> Among surgical correction techniques are: removing the excess skin and / or correcting the cleft; hyaluronic acid based cutaneous filling; the use of caustic substances, with application limited to the orifice or covering the lobe completely; or, still, the use of lasers, which is frequent in the therapeutic armamentarium.<sup>3-5</sup> More recently, pulsed radio frequency with multineedles was indicated by Lima for the rejuvenation of the eyelids. In the present study, the author describes outcomes showing important cosmetic improvement in 19 patients, with correction of sagging and wrinkles, and increased quality of the skin.<sup>6</sup>

Based on the findings regarding the aging process of the eyelid, an investigation was conducted aimed at verifying the applicability of the technique in cases of aging of the earlobe. The present study presents this investigation's results.

### Pulsed radiofrequency with multineedles (RFPM®)

The use of fractional random high frequency energy beamed on the skin results in dermal regeneration at the papillary-reticular interface, through the stimulation of fibroblasts and subsequent synthesis of collagen and elastic fibers, as well as epidermal regeneration caused by the migration of keratinocytes.

This paper proposes an innovative approach for skin rejuvenation, based on subablative energy, using electrodes with several needles, connected to a radio-electrosurgery device.

This technique, performed in a well-delimited and accurate manner, does not compromise the tissue adjacent to the vaporized micropoints and causes significant tissular impact, thus enabling the stimulus for new collagen formation.

Electrodes called Lima 2, Lima 4 and Lima 8 – in a reference to the Author's name – (Figure 1) are required for performing RFPM®. They respectively consist of 2, 4 or 8 tungsten needles with a diameter of 100 thousands of a millimeter, with identical weight and length, arranged in parallel, aimed at reaching the same depth. Being 2mm long, these needles cross the epidermis and act in the dermis, stimulating the contraction and renewal of collagen (Figure 2).

The present retrospective clinical study was to evaluate the effectiveness of RFPM® in rejuvenating the earlobe.

## METHODS

The medical records of 12 female patients with aged earlobes treated with RFPM®, performed ambulatorially by the same physician, between March and December 2015, were analyzed. The photographic records were carried out with the same

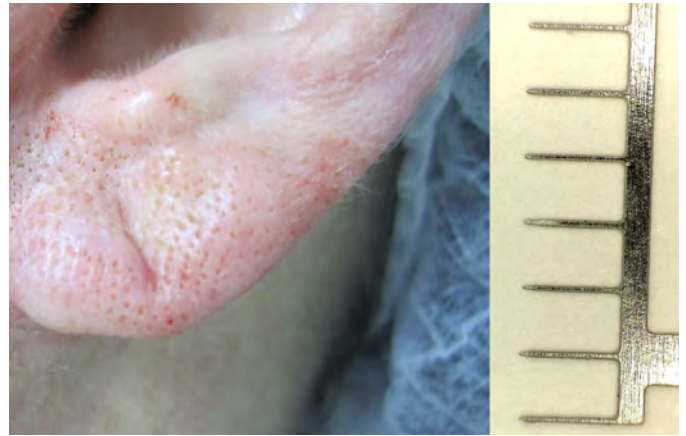


FIGURE 1: RFPM®'s immediate postoperative period and electrode with 100µ needles (depicted with great magnification)

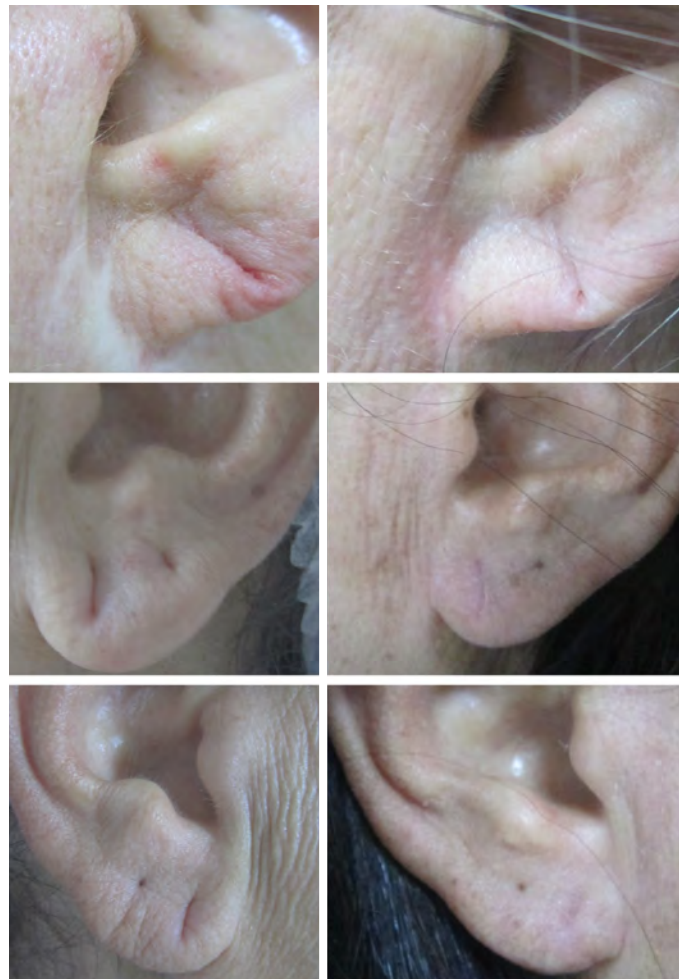

FIGURE 2: Earlobes before and 30 days after treatment with RFPM®

digital camera, under the same environmental conditions, immediately before and 1 month after a single intervention. The study was performed according to the Helsinki Declaration.

After antiseptics with 1% chlorhexidine, the earlobe was injected with 2% lidocaine without vasoconstrictor. The FRAXX® device (Loktal Medical Electronics, São Paulo, Brazil, Anvisa 10362610008) was used for the application of RFPM® in the single pulse mode, and with parameters set at levels guided by 12 months of investigative effort. The patients in this group were treated with the device set in the CUT mode, power at 30, Active at 30ms, using the Lima 8 electrode. A single pass was performed, avoiding overlapping. The earlobe was completely covered with the treatment and both faces – anterior and posterior – were punctured by the needles.

After the procedure, dressings with micropored bandage were applied and removed on the following day. The patients were instructed to use a skin regenerating cream (Ciclapast baume® La Roche Posay, Rio de Janeiro, Brazil) in the postoperative period twice a day, in addition to an industrialized SPF 60 sunscreen.

The evaluation of results was performed based on patient satisfaction questionnaires and the judgment of clinical outcomes performed by independent dermatologist physicians.

The self-assessment questionnaire included questions on the degree of satisfaction with the procedure, measured with the ratings *poor*, *reasonable*, *good* and *very good*.

Photographs of before and 30 days after the procedure were evaluated by 2 dermatologist physicians unrelated to the study, who used the following scale: *regular* (for 25% of improvement), *good* (50% improvement), *very good* (for 75% improvement) and *excellent* (for 100% improvement).

Figure 1: Lima 8 electrode and earlobe immediately after the intervention.

## RESULTS

Twelve women between 42 and 67 years old, treated at the author's private clinic and the Cosmiatry Ambulatory of the Santa Casa de Misericórdia do Recife were evaluated. The patients' Fitzpatrick phototypes ranged from II to IV. All patients reported satisfaction with the results, choosing the ratings *good* and *very good* for the questions asked in the questionnaire.

Based on the comparative evaluation of the photographs taken before and after the procedure, performed by 2 independent dermatologist physicians, the improvement indices were the following: 75% = *very good* (4 patients) and 100% = *excellent* (8 patients). Also, a substantial improvement was observed in the size of the earring orifice (Figure 2).

The pain during the treatment was considered tolerable, and tissue regeneration was observed between 5 and 7 days, with patients returning to their work activities after a significant reduction of the edema and hematoma resulting from the infiltrative anesthesia and the procedure. No infections, permanent

dyschromia or unsightly scars were observed in this group.

Mild to moderate post-inflammatory hyperpigmentation was observed in 5 of the 12 patients after a period of 10 to 15 days after the treatment. Resolution was achieved in 15 to 30 days with the use of whitening formulations.

## DISCUSSION

Earlobe sagging is a frequent complaint among patients seeking cosmetic treatments. The annoyance becomes more pronounced when earrings are no longer used due to the enlargement of the cleft, which loses its ability to hold the adornment well positioned because of the lobe's sagginess and looseness.

The corrective techniques used have offered satisfactory results, however some patients might respond poorly to the interventions, and the combination of procedures is often mandatory.<sup>4,5</sup>

When excess skin and sagging are intense, conventional surgical intervention might not be well accepted by the patient since it results in scars, even when the necessary preventative measures are taken. Peels or semi-ablative techniques can be insufficient for the improvement of the damage, especially in elderly patients. Hyaluronic acid, a common cutaneous filler aimed at treating this region's aging, volumizes and attenuates fine wrinkles and sagging, nevertheless has limitations regarding the improvement in the skin's quality and deeper static wrinkles, which many times behave as scars due to the intense elastosis.<sup>3-7</sup>

For rejuvenating this area, the Author of the present paper proposes the use of RFPM® with specific electrodes, a methodology that has been recently developed and studied in detail, based on results obtained in the treatment of periorbital aging.<sup>6</sup> The data presented in this article suggest that:

1. RFPM® is a promising therapeutic proposal for the rejuvenation of the earlobe, especially when there is absence of indication of or desire for conventional surgery, and when thin, sagging and wrinkled skin is the main complaint
2. The results obtained are reproducible using the methodology and the electrodes described in this article
3. The possibility of a swift return to the professional activities and few adverse effects observed in the evaluated group encouraged the Author of the present article to recommend the inclusion of this new proposal in the already available broad therapeutic armamentarium for intervention in this region.
4. Performing the procedure requires training and is technician-dependent. The operator needs to be properly skilled and must have all necessary basic knowledge to ensure excellence of outcomes

The Author of the present article suggests that the technique be evaluated in other groups with a view to confirming the outcomes and conclusions presented in this paper. ●

## REFERENCES

1. Beschloss J, Toren L, Bingham JL. Earlobe stabilization with 6-0 suture for repair of a complete split. *Dermatol Surg.* 2011;37(6):848–849.
2. Mendça M, de Oliveira AR, Araújo JM, Silva Md, Gamonal A . Nonsurgical technique for incomplete earlobe cleft repair. *Dermatol Surg.* 2009;35(3):446–450.
3. Niamtu J 3rd. Eleven Pearls for Cosmetic Earlobe Repair . *Dermatol Surg.* 2002;28(2):180–185.
4. Bagatin E, Hassun K, Talarico S. Revisão sistemática sobre peelings químicos. *Surg Cosmet Dermatol.* 2009;1(1):37-46.
5. Ravanfar P, Alster TS. Laser earlobe revision. *Dermatol Surg.* 2013;39(7):1056–1061.
6. Lima E . Radiofrequência pulsada com multiagulhas: uma proposta terapêutica em rugas, flacidez e pigmentação periorbital. *Surg Cosmet Dermatol.* 2015;7(3):223-6.
7. Chiummariello S, Iera M, Arleo S. L-specular plasty versus double-round plasty: two new techniques for earlobe split repair. *Aesth Plast Surg.* 2011 35(3):398–401.