

# Thinning of the lower third of the face using botulinum toxin in the masseter muscle

*Afinamento do terço inferior da face com uso de toxina botulínica no músculo masseter*

DOI: <http://dx.doi.org/10.5935/scd1984-8773.201681566>

## ABSTRACT

The width of the lower third of the face is mainly determined by the size and shape of the jawbone, the thickness of the masseter muscle and the volume of adjacent subcutaneous tissue. The ideal, culturally recognized pattern for a male face corresponds to a wider lower third and a mandibular angle tending to 90°, while a female face should have a more oval appearance or the shape of a heart, and the middle third wider than the lower third. In order to achieve these aesthetically ideal proportions, botulinum toxin type A (BoNTA) has been successfully applied in the masseter muscle, which is one of the determinates of the lower face's width. The present article reviews the current literature on the use of botulinum toxin for this purpose, offering the experience of the authors in this practice, aiming at achieving a more harmonious facial contour.

**Keywords:** botulinum toxins, type A; masseter muscle; hypertrophy

## RESUMO

A largura do terço inferior da face tem como principais determinantes o tamanho e a forma do osso mandibular, a espessura do músculo masseter e o volume de tecido celular subcutâneo adjacente.

Culturalmente o que é considerado ideal para a face masculina é terço inferior mais largo e ângulo mandibular mais reto, enquanto a face feminina deve apresentar aspecto mais oval ou em coração, com a largura do terço médio da face maior do que a do terço inferior.

Para atingir essas medidas esteticamente ideais a toxina botulínica tipo A (BoNTA) tem sido utilizada com sucesso através de sua aplicação no músculo masseter, um dos determinantes da largura do terço inferior da face. Dessa forma, este artigo faz uma revisão do que a literatura atual descreve com o uso da toxina botulínica para essa finalidade, complementando com a experiência dos autores nessa prática para a obtenção de um contorno facial mais harmonioso.

**Palavras-chave:** toxinas botulínicas tipo A; músculo masseter; hipertrofia

## Review article

### Authors:

Bruna Souza Felix Bravo<sup>1</sup>  
Laila Klotz de Almeida Balassiano<sup>2</sup>  
Camila Roos Mariano da Rocha<sup>3</sup>  
Julien Totti de Bastos<sup>3</sup>  
Priscila Mara Chaves e Silva<sup>3</sup>  
Bruno Messias Pires de Freitas<sup>4</sup>

<sup>1</sup> Head of the Cosmiatry Ambulatory, Instituto de Dermatologia Professor Rubem David Azulay, Santa Casa de Misericórdia do Rio de Janeiro and Hospital Federal da Lagoa Rio de Janeiro - Rio de Janeiro (RJ), Brazil

<sup>2</sup> Graduate student, Dermatology Service, Policlínica Geral do Rio de Janeiro - Rio de Janeiro (RJ), Brazil

<sup>3</sup> Resident physician, Dermatology Service, Hospital da Lagoa - Rio de Janeiro (RJ), Brazil

<sup>4</sup> Physician, medical degree from the Universidade Estácio de Sá - Rio de Janeiro (RJ), Brazil

### Correspondence:

Bruna Souza Felix Bravo  
Rua Dona Mariana 143 - Botafogo  
22280-020 - Rio de Janeiro - RJ  
Email: [brunabravo@globo.com](mailto:brunabravo@globo.com)

Received on: 14/11/2015

Approved on: 20/03/2016

This study was performed at the Hospital Federal da Lagoa - Rio de Janeiro (RJ), Brazil.

Financial support: None

Conflict of interests: None

## INTRODUCTION

The contour of the face is a determining factor in differentiating beauty for men and women. The male face is square and composed of well-marked angles, and the middle and lower thirds have equal widths. On the other hand, the female face tends to be more delicate, with oval or triangular shape, with the lower third thinner than the superolateral projection of the zygomatic arch.<sup>1</sup>

The so-called *angle of beauty* emerged from the evaluation of the geometry of the facial contour of people considered beautiful.<sup>2</sup> This angle is formed by the intersection of a line drawn parallel to the midline of the face with the crossing point of two other lines (one coinciding with the mandibular body and the other a projection of the ascending branch of the mandible).

In patients with masseter hypertrophy or increased parotid, this angle is acute. In patients with triangular shaped face or when the contour of the inferior third of the face is attenuated, this angle becomes less acute. Still according to the author, the ideal angle would be between 9° and 12° (Figure 1).<sup>3</sup>

The hypertrophy of the masseter muscle is a benign condition of unknown etiology, most frequent in people aged between 20 and 40 years, with no gender preference, and that can be unilateral or bilateral. It is common among Asians and contributes to the conformation of broad faces. It is less common in Caucasians, however can be associated with bruxism and temporomandibular joint pain.

Several surgical procedures have been described aimed at correcting this condition, mainly involving the resection of the mandibular angle and/or masseter muscles, in order to make

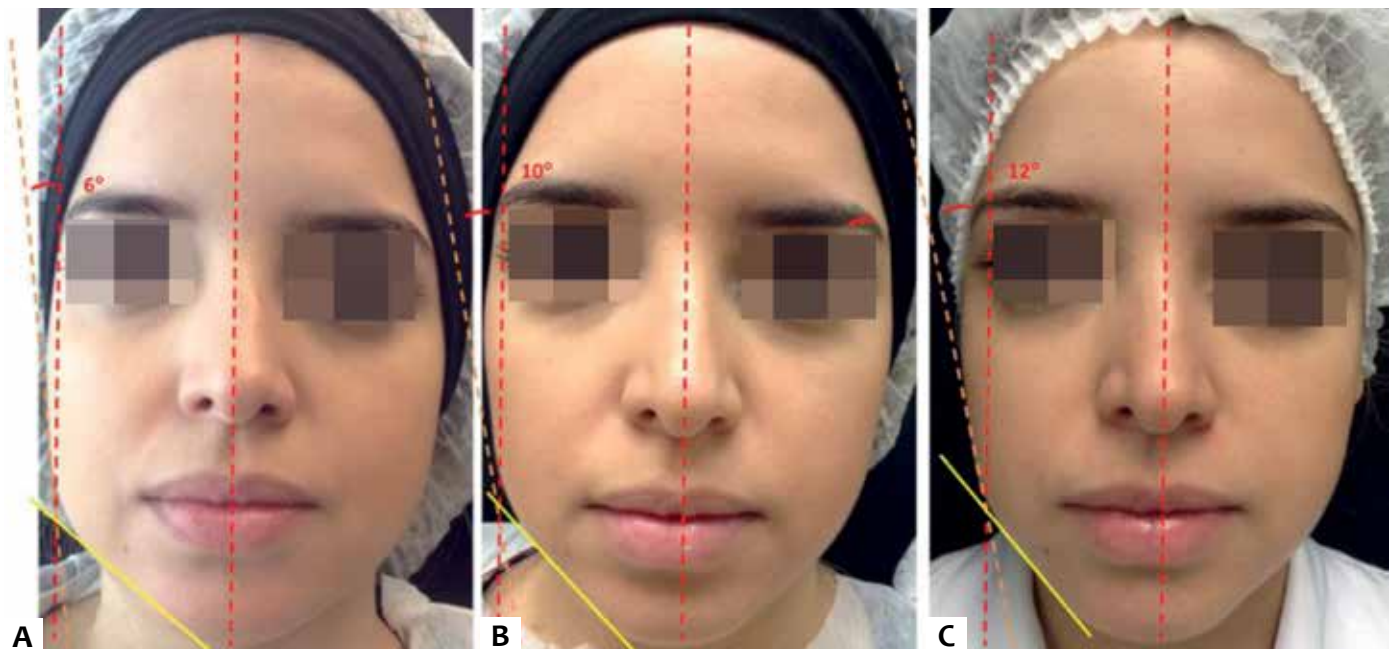
the inferior third of the face thinner. As with in any surgical procedure, it is necessary to highlight the general risks associated with it – in this case, the specific risk of facial nerve lesion. In addition, patients who usually wish to undergo facial contouring procedures are in their economically active age and do not want to be away from work for long periods, which makes more difficult a choice for the surgical procedure.<sup>4,5</sup>

In this respect, and with the development of conservative therapy, several articles have demonstrated the successful use of BoNTA as an alternative to the surgical treatment of masseteric hypertrophy, in this way avoiding long recovery times and, more recently, its use for the attenuation of the facial contour.

BoNTA has been successfully used for many years for cosmetic purposes, aiming at preventing and smoothening wrinkles and expression lines in the upper face. Its benefits have already been widely described in the lower face with the purpose to achieve a more harmonious facial contour. More recently, these applications have been demonstrated in clinical trials of greater impact, allowing further refinement of the technique.<sup>3-4</sup>

The technique was initially developed with a focus on Asian patients, whose ethnic characteristics include prominence of the mandibular angle, however it has more recently been also applied in Caucasians. In 2001, To et al. reported the first use of BoNTA with purely aesthetic purpose in the contour of the lower face.<sup>2,4,6,7</sup>

After being introduced in the human body, BoNTA is directed to the neuromuscular junction, where it binds to high affinity presynaptic receptors. It is then internalized and subsequently cleaves a membrane protein, which is responsible for the



**FIGURE 1:** The angle of beauty. A less acute angle after the remodeling of the lower third of the face. (a) Pre-treatment. (b) Three months after the application. (c) Six months after the application.

exocytosis of acetylcholine. This cascade results in the blocking of the release of acetylcholine and consequently inhibition of muscle contraction by chemical denervation.

The muscle treated begins to weaken within 2 to 20 days.

The use of BoNTA in the treatment of facial contour is aimed at reducing the function of the masseter muscle, causing atrophy, since the muscle's hyperactivity

and conditions such as bruxism may be associated with its hypertrophy.<sup>3,6,7</sup>

## ANATOMY

The masseter is the largest and strongest muscle of mastication. It is comprised of three overlapping layers, which originate from the zygomatic arch and insert in the ascending arch of the mandible, thus allowing the muscle to fulfill its function of lifting and closing the jawbone. The masseter's superficial portion arises from the zygomatic process of the maxilla and the anterior two thirds of the zygomatic arch's border. The middle portion originates from the deep surface of the zygomatic arch's anterior two-thirds and posterior third's inferior edge. The deep portion arises from the deep surface of the zygomatic arch. The three layers merge while the fibers are directed backwards and downwards in order to insert in the lateral surface of the angle, branches and coronoid process of mandible. The thickest palpable region, when the patients are clenching their teeth, is located where these fibers overlap. This muscle is innervated by the masseteric nerve, which arises from the anterior division of the mandibular branch of the trigeminal nerve. Its vascular supply is derived from facial transverse branch of the superficial temporal artery, the masseteric branch of the maxillary artery and facial arteries.<sup>1</sup>

## DISCUSSION ABOUT THE TECHNIQUES

The technique for applying BoNTA aiming at remodeling the inferior third of the face is very similar to the application for the treatment of hypertrophy of the masseter muscle and consists in the injection of one to six points distributed along the muscle's body.<sup>2,4,5,8-16</sup>

Most articles suggest an application distributed in three points – two inferior points close to the mandible, and a superior one.<sup>12-17</sup>

The injection points are located below the line drawn from the tragus to the corner of the mouth (a line that delimits the lower facial third) and approximately 1.5cm above the mandibular angle. This prevents the paralysis of the zygomatic and risorius muscles and/or lesions in the parotid gland's duct. For the demarcation of the anterior and posterior borders of the masseter muscle, the patient is asked to clench his or her teeth, allowing thus that muscle be palpated in its entire length. Although there is no consensus in the literature regarding doses – that can range from 10U to 300U of BoNTA per area, with great discrepancy among authors – an average dose of 20U per hemiface are described as being sufficient to soothe the facial contour in the Caucasian population.<sup>9-18</sup>

Patients of Asian origin and with masseter hypertrophy

and/or bruxism, may require higher doses. In cases of unilateral or asymmetric hypertrophy, doses should be adjusted.<sup>3,19</sup>

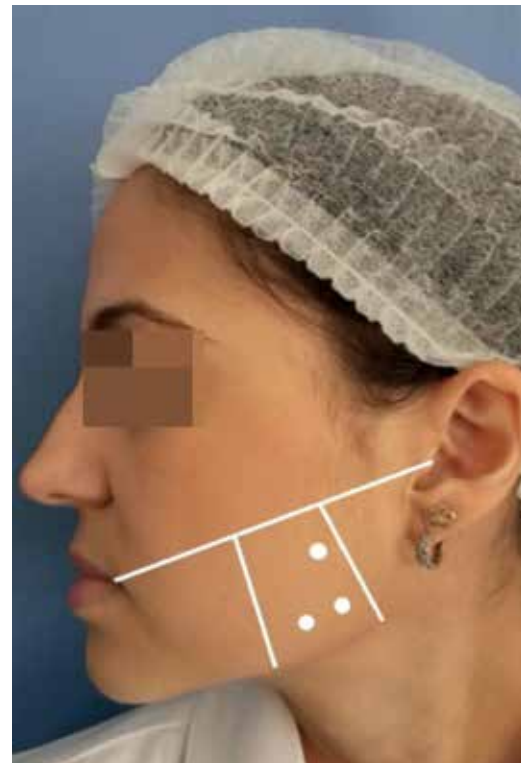Despite the fact that the injected points are located in the lower portion of the masseter, the disuse of the muscle caused by the injection of BoNTA leads to muscle atrophy as a whole.

After the application, the effect on the muscles follows a progressive course, with the patients already reporting changes in the contour of the inferior third of the face in 2 to 4 weeks, which becomes more clinically apparent between 8 and 12 weeks.<sup>8,20</sup>

YU et al. evaluated the masseter's thickness using 3D images obtained by computerized tomography before and after 3 months of the BoNTA application observing a reduction of roughly 30% in the initial volume of the muscle.<sup>4</sup>

In most studies, the peak effect also coincided with the period of greatest patient satisfaction. The positive aspect is that there is a time interval between the recoveries of the function and of the muscle volume. The muscle's action returns after 12 weeks, while its volume being recovered only after 16 weeks. Furthermore, the time required for recovery of the muscle volume increases with patient age. In addition, although the atrophy of the fibers is reversible and temporary, the muscle volume appears not to return to the pre-treatment state, even after the complete recovery of its function after the BoNTA effect has receded, with a more natural outcome arising with the passing of the time.<sup>2,7,8,21,22</sup>

Moreover, the authors suggest that successive doses at



**FIGURE 2:**  
BoNTA application points

regular intervals allow gradual thinning and necessity of lower doses in subsequent applications, since the muscle volume tends to decrease.<sup>18, 23, 24</sup>

Complementary techniques with lipolytic substances, hyaluronic acid and radio frequency can be combined to optimize the facial contour.<sup>12, 25</sup>

Regarding side effects, the most commonly reported is the reduction or asymmetry of the rise of the corner of the mouth while in the smiling position. Other rarer and also transient complaints were: masticatory weakness, changes in facial expressions caused by injection points in high and close to the zygomatic bone locations, dry mouth due to temporary decrease of salivary secretion from the parotid gland, and bulging in parts diverse from the injection site during mastication in patients who underwent application in a single site. All side effects were temporary and did not affect the daily life of patients. The decrease in bite force began one week after the procedure, with complete recovery in 3 weeks. The possible reason for this is the compensation by other muscles participating in the masticatory function. There was no evidence, however, of compensatory hypertrophy.<sup>4, 21</sup>

A change in the smile can occur when the BoNTA application points are very close to the anterior border of the masseter muscle, with the neurotoxin spreading into the risorius muscle, which connects the masseter to the corner of the mouth. Bulgings identified during mastication should be treated with a new BoNTA injection in the surrounding area.<sup>4, 6, 8</sup>

The best results are obtained in patients with well-developed masseters, aligned facial contours, without protrusive bones and small amounts of adipose tissue around the chin or cheekbones. Patients with round faces due to the bone structure, excess of adipose tissue, highly developed parotid gland or little tissue elasticity may experience poor outcomes.<sup>8</sup>

The application should be repeated at intervals of 4 to 6 months, until the desired facial contour is achieved.<sup>4, 26</sup>

### THE AUTHORS' EXPERIENCE

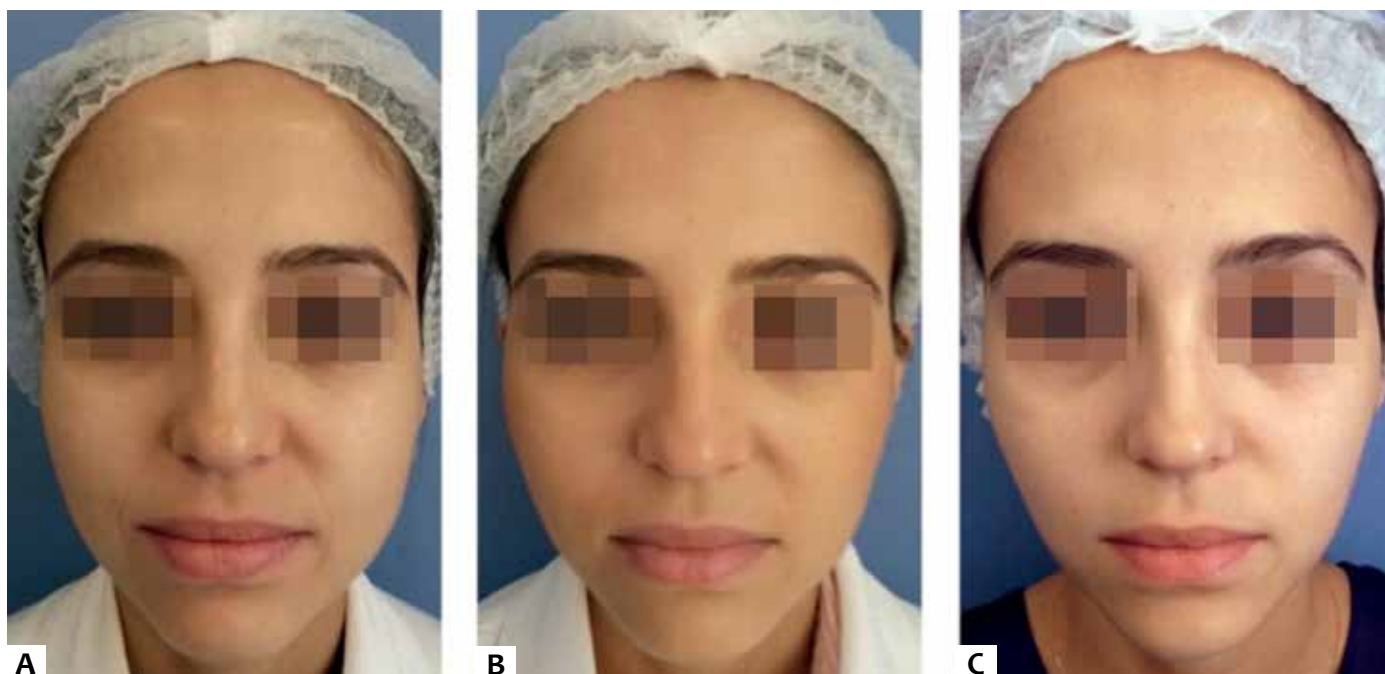The authors' experience with the application of botulinum toxin for the aesthetic treatment of the masseter muscle is performing the injection of, on average, 5 to 10 onabotulinumtoxin A units per point, at three points distributed within the defined limits: two located inferiorly and one located superoposteriorly (Figure 2). The injection is performed perpendicularly to the skin, reaching the deep intramuscular plane.

The reduction of the masseter muscle was gradual during the weeks after the treatment, with a significant reduction over the 6 months after the application. (Figures 3 and 4).

Aligned with the literature, one of the treatment's side effects was the decrease in the amplitude of the smile due to the risorius muscle's proximity to the range of action of the toxin during the application (Figure 5).

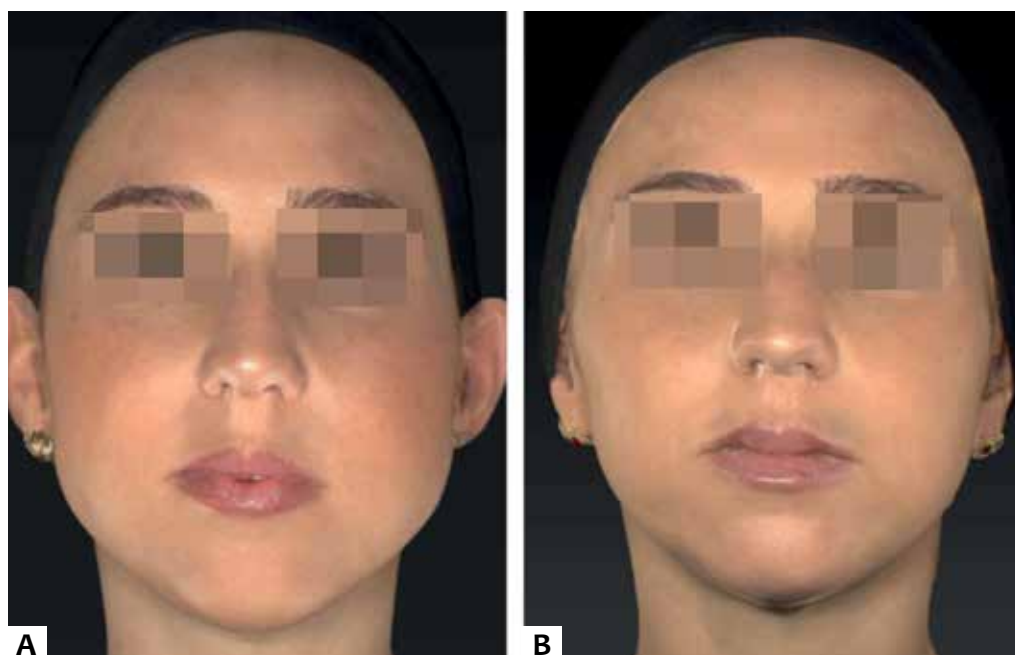### CONCLUSION

The application of BoNTA has proven to be a straight-

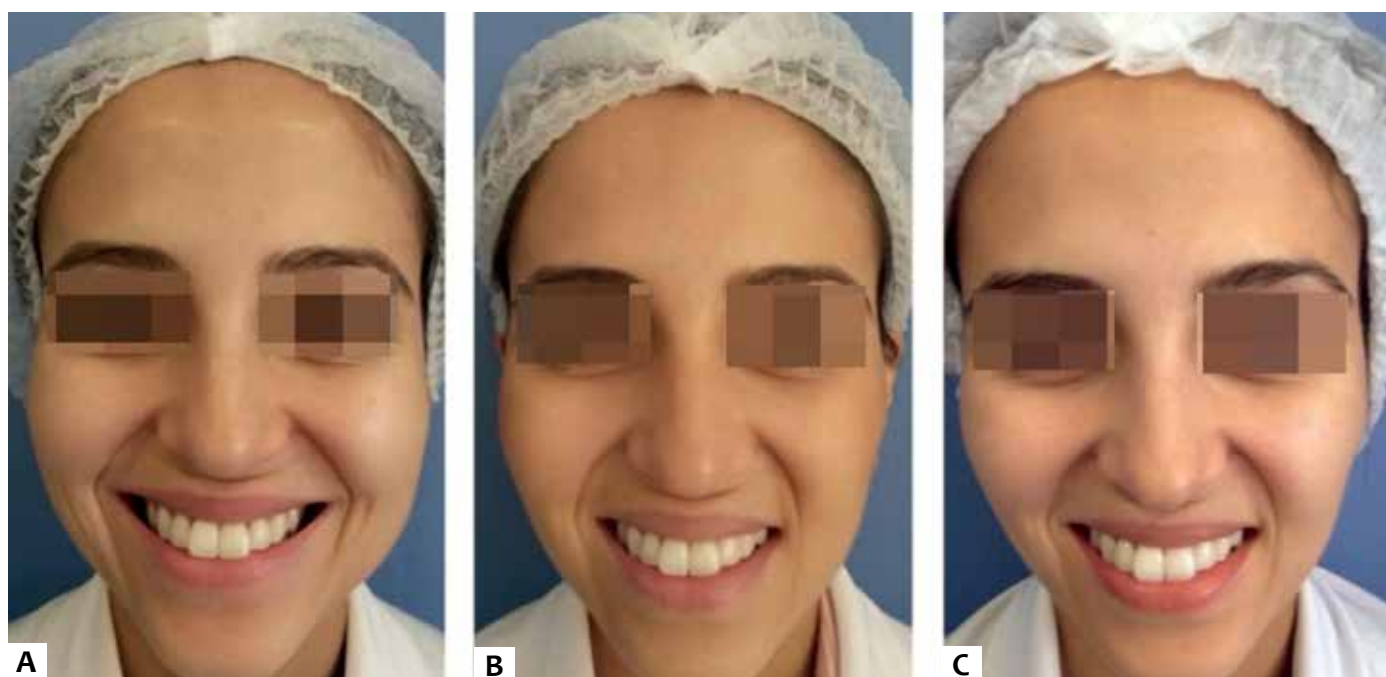


**FIGURE 3:** (a) Pre-treatment. (b) Three months after the application. (c) Six months after, with the thinning of the lower third





**FIGURE 4:** (a) Pre-treatment. (b) Six months after the application



**FIGURE 5:** (a) Pre-treatment. (b) Three months after the application, reduced amplitude and asymmetry in the smile. (c) Six months after, with improved smile amplitude and thinning of the lower third of the contour

forward and safe method leading to good clinical outcomes in patients who wish to soothe the contour of the inferior third of the face, without being exposed to the risks of surgery or long recovery periods. The chemical denervation's effects begin to be noticed after 2 weeks, with reduced strength of the masseter. The clinical changes in the contour and thinning of the face become

more evident in 3 months as a result of the masseter's atrophy and have an average duration of 9 months. There is absence of reports of serious complications. In conclusion, the treatment becomes an option accessible to patients who want narrow faces, which convey the real features of a feminine face. ●

## REFERENCES

1. Carruthers A, Carruthers J. Procedures in cosmetic dermatology: Toxina Botulínica; 3ª Ed. Madrid: Elsevier; 2012.
2. Liew S, Dart A. Nonsurgical reshaping of the lower face. *Aesthet Surg J*. 2008;28(3):2517.
3. Goodman GJ. The Masseters and Their Treatment with Botulinum Toxin. In: Carruthers A, Carruthers J, editors. *Botulinum Toxin*. New York: Elsevier; 2013. p. 135-41.
4. Yu C C, Chen P K T, Chen Y R. Botulinum Toxin A for Lower Facial Contouring: A Prospective Study. *Aesth Plast Surg*. 2007;31(5): 445-51.
5. Park MY, Ahn KY, Jung DS. Botulinum toxin type A treatment for contouring of the lower face. *Dermatol Surg*. 2003;29(5):477-83.
6. Ascher B, Talarico S, Cassuto D, Escobar S, Hexsel D, Jaén P, et al. International consensus recommendations on the aesthetic usage of botulinum toxin type A (Speywood Unit) part II: wrinkles on the middle and lower face, neck and chest. *J Eur Acad Dermatol Venereol*. 2010;24(11):1285-95.
7. Choe S W, Cho W I, Lee C K, Seo S J. Effects of Botulinum Toxin Type A on Contouring of the Lower Face. *Dermatol Surg*. 2005;31(5):502-7; discussion 507-8.
8. Kim NH, Chung JH, Park RH, Park JB. The use of botulinum toxin type A in aesthetic mandibular contouring. *Plast Reconstr Surg*. 2005; 115(3):919-30.
9. Kwon JS, Kim ST, Jeon YM, Choi JH. Effect of botulinum toxin type A injection into human masseter muscle on stimulated parotid saliva flow rate. *Int J Oral Maxillofac Surg*. 2009;38(4):316-20.
10. Ahn KY. Commentary: The effect of botulinum toxin type A injection on lower facial contouring evaluated using a three-dimensional laser scan. *Dermatol Surg*. 2010;36(Suppl 4):2167.
11. Wu WT. Botox facial slimming/facial sculpting: the role of botulinum toxin-A in the treatment of hypertrophic masseteric muscle and parotid enlargement to narrow the lower facial width. *Facial Plast Surg Clin North Am*. 2010;18(1):133-40.
12. Wong GR, Chen WP. Phosphatidylcholine/deoxycholate lipolysis and hyaluronic acid augmentation to enhance nonsurgical lower facial contouring using botulinum toxin type A. *J Cosmet Dermatol*. 2011;10(2):159-62.
13. Ba B, Ozan B, Mu lali M, Celebi N. Treatment of masseteric hypertrophy with botulinum toxin: a report of two cases. *Med Oral Patol Oral Cir Bucal*. 2010;15(4): 649-52.
14. Ahn KY, Kim ST. The change of maximum bite force after botulinum toxin type a injection for treating masseteric hypertrophy. *Plast Reconstr Surg*. 2007;120(6):1662-6.
15. Klein FH, Brenner FM, Sato MS, Robert FM, Helmer KA. Lower facial remodeling with botulinum toxin type A for the treatment of masseter hypertrophy. *An Bras Dermatol*. 2014;89(6):878-84.
16. Ahn BK, Kim YS, Kim HJ, Rho NK, Kim HS. Consensus recommendations on the aesthetic usage of botulinum toxin type A in Asians. *Dermatol Surg*. 2013;39(12):1843-60.
17. Lee DH, Jin SP, Cho S, Feneran A, Youn CS, Won CH, et al. RimabotulinumtoxinB versus OnabotulinumtoxinA in the treatment of masseter hypertrophy: a 24-week double-blind randomized split-face study. *Dermatology*. 2013;226(3):227-32.
18. Kim NH, Park RH, Park JB. Botulinum toxin type A for the treatment of hypertrophy of the masseter muscle. *Plast Reconstr Surg*. 2010;125(6):1693-705.
19. Cha YR, Kim YG, Kim JH, Kim ST. Effect of unilateral injection of botulinum toxin on lower facial asymmetry as evaluated using three-dimensional laser scanning. *Dermatol Surg*. 2013; 39(6):900-6.
20. Shim W H, Yoon S H, Park J H, Choi Y C, Kim S T. Effect of Botulinum Toxin Type A Injection on Lower Facial Contouring Evaluated Using a Three-Dimensional Laser Scan. *Dermatol Surg*. 2010;36 (Suppl 4) :2161-6.
21. Chang CS, Bergeron L, Yu CC, Chen PK, Chen YR. Mandible changes evaluated by computed tomography following Botulinum Toxin A injections in square-faced patients. *Aesthetic Plast Surg*. 2011; 35(4):4525.
22. Song JH, Cho ES, Kim ST, Ahn HJ. Change of distribution and timing of bite force after botulinum toxin type A injection evaluated by a computerized occlusion analysis system. *Yonsei Med J*. 2014; 55(4):1123-9.
23. Aydil B, Ba aran B, Unsaler S, Süo lu Y. The use of botulinum toxin type A in masseter muscle hypertrophy: long-term effects and lasting improvement. *Kulak Burun Bogaz Ihtis Derg*. 2012;22(5):249-53.
24. Arzul L, Corre P, Khonsari RH, Mercier JM, Piot B. Asymmetric hypertrophy of the masticatory muscles. *Ann Chir Plast Esthet*. 2012;57(3):286-91.
25. Huang JL, Chen G, Chen XD, Zhou BR, Luo D. A comparative study of the efficacy and safety of radiofrequency ablation and botulinum toxin A in treating masseteric hypertrophy. *Exp Ther Med*. 2014;7(5):1203-8.
26. Dayan S H, Maas C S. Botulinum Toxins for Facial Wrinkles: Beyond Glabellar Lines. *Facial Plast Surg Clin North Am*. 2007;15(1):41-9.