

# Epidemiological study of 740 areas treated with cryolipolysis for localized fat

Estudo epidemiológico de 740 áreas tratadas com criolipólise para gordura localizada

## Authors:

Guilherme Olavo Olsen de Almeida<sup>1</sup>  
 Carlos Roberto Antonio<sup>2</sup>  
 Guilherme Bueno de Oliveira<sup>3</sup>  
 Ivan Rollemberg<sup>4</sup>  
 Renata Cristina Vasconcellos<sup>5</sup>

<sup>1</sup> Dermatologist physician - São Paulo (SP), Brazil.

<sup>2</sup> Instructor and Head of Dermatologic Surgery, Faculdade de Medicina de São José do Rio Preto (FAMERP) – São José do Rio Preto (SP), Brazil.

<sup>3</sup> Preceptor at the Dermatology ambulatory, FAMERP.

<sup>4</sup> Dermatology resident physician, FAMERP.

<sup>5</sup> Medicine undergraduate student, FAMERP.

## Correspondence:

Carlos Roberto Antonio  
 Rua Silva Jardim, 3114, Centro,  
 CEP 15010-060 - São José do Rio Preto,  
 SP, Brazil  
 Email: carlos@ipele.com.br

Received on: 15/09/2015

Approved on 10/11/2015

The present study was carried out at the Faculdade de Medicina de São José do Rio Preto (FAMERP) – São José do Rio Preto (SP), Brazil.

Financial support: None

Conflict of interests: None

DOI: <http://dx.doi.org/10.5935/scd1984-8773.201574697>

## ABSTRACT

**Introdução:** A non-invasive alternative for the treatment of localized fat is cryolipolysis that, by freezing adipocytes, reduces fat volume in the region where the procedure was performed.

**Objective:** To statistically describe the experience of a referral center for this procedure.

**Methods:** A cross-sectional study with 251 patients undergoing cryolipolysis was carried out with the epidemiological analysis of patient data.

**Results:** Thirty-eight males and 213 females underwent the procedure, with a total number of 740 treated areas. The anterior abdomen (lower third) was the most popular region, with 45.30% of cases. Eighty-eight percent were satisfied or very satisfied with the result. Nearly all cases required 2 or more sessions to achieve this degree of satisfaction.

**Conclusions:** Cryolipolysis is a noninvasive method for the selective reduction of fat that has shown efficacy in reducing the subcutaneous tissue, with minimal and reversible side effects in this study.

**Keywords:** lasers; abdominal fat; lipolysis

## RESUMO

**Introdução:** Uma das alternativas não invasivas para o tratamento da gordura localizada é a criolipólise que, mediante o congelamento dos adipócitos, diminui o volume de gordura na região em que foi realizado o procedimento.

**Objetivo:** Descrever estatisticamente a experiência de um centro de referência para esse procedimento.

**MÉTODOS:** Estudo transversal com 251 pacientes submetidos à criolipólise, com análise epidemiológica dos dados dos pacientes.

**Resultados:** 38 homens e 213 mulheres, com número total de áreas tratadas de 740. O terço inferior do abdômen anterior foi a região mais procurada, com 45,30% dos casos. 88% dos pacientes ficaram satisfeitos ou muito satisfeitos com o resultado. Quase todos os casos necessitaram de duas ou mais sessões para atingir esse grau de satisfação.

**Conclusões:** É método não invasivo para redução seletiva de gordura que demonstrou eficácia na diminuição do tecido subcutâneo, com efeitos colaterais mínimos e, neste estudo, reversíveis.

**Palavras-chave:** lasers; gordura abdominal; lipólise

**INTRODUCTION**

Liposuction used in the removal of excess localized fat is the most frequently performed surgery in the United States of America. Due to the disadvantages inherent to this surgical procedure, such as the possibility of hospitalization and general anesthesia, complications and time of postoperative recovery, there is a growing demand for non-invasive body esthetical procedures.<sup>1-6</sup>

A frequently used non-invasive alternative is the cryolipolysis, that reduces fat volume in the region where the procedure was performed through the freezing of adipocytes. Due to the fact that adipocytes are more sensitive to cold than other histological structures such as the epidermis, dermis, blood vessels, sweat glands, muscles and nerves, their apoptosis occurs before that of the other cells.<sup>2,7-10</sup>

The adipose tissue is placed in contact with cold plaques using a pressure applicator that thermally “kills” the fat without damaging the skin.<sup>11</sup> The dead cells are then removed metabolically, as with the fat found in food.<sup>1,9</sup>

The present study statistically describes the experience of a referral center for this procedure in the Brazilian Southeast city of São Paulo.

**METHODOLOGY**

A cross-sectional study was carried out with 251 patients who spontaneously and randomly sought a private dermatologic practice for the treatment of localized fat. All patients in this study underwent only the cryolipolysis procedure with the Coolsculpting® device (Zeltic Aesthetics, Pleasanton (CA), USA). The exclusion criteria for not undergoing this therapy were: cryoglobulinemia, cryofibrinogemia, cold urticaria and obesity grade I, II and III according to the Abeso’s (Brazilian Association for the Study of Obesity and Metabolic Syndrome) body mass index.

The present study described the epidemiological profile of patients who underwent this procedure with the percentage analysis of the following variables: *gender, age, number of sessions per area, distribution of body sites treated with the procedure, patient’s satisfaction, independent observer evaluation and description and management of adverse events.*

The patient satisfaction rate was determined by the following scale: 0 = unsatisfied, 1 = somewhat satisfied, 2 = satisfied and 3 = very satisfied. The results were compared by an independent observer in the before the treatment and eight months after the treatment based on three dimensions digital photographs (Vectra M3®, Canfield), according to the following scale: 0 = absence of improvement, 1 = little evident improvement and 2 = evident improvement.

**RESULTS**

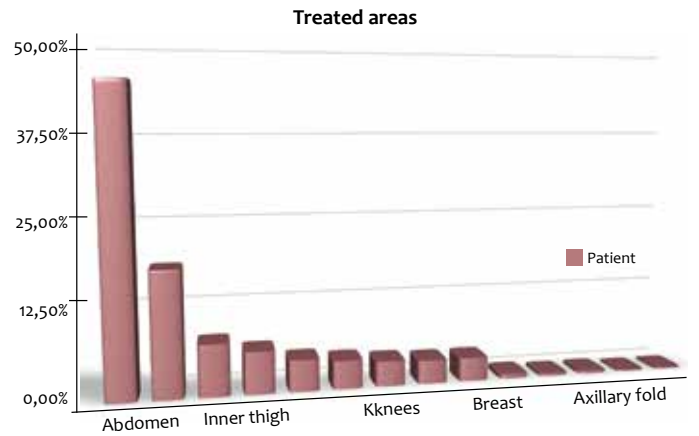
The authors treated 251 patients (38 men and 213 women) who had accumulation of localized fat, with a total of 740 areas treated. Ninety-six (96) patients underwent the procedure in more than one area, with 8 having undergone more than one session in the same area (the most common combination being

flanks and abdomen). The average age of the study participants was 45 years (min = 13, max = 71).

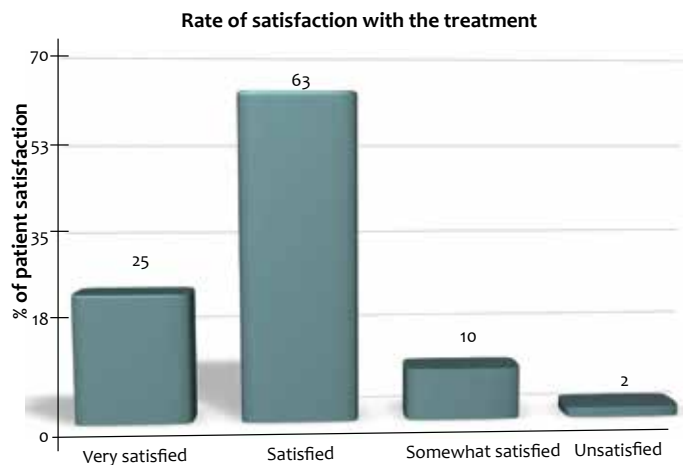
The treated areas showed the following distribution (Graph 1): anterior abdomen – lower third (45.30%), flanks (18.77%), lateral side of the thigh or (7.74%), internal side of the thigh (6.33%), arms (4.69%), infragluteal area (4.22%), knees (3.75%), lateral abdomen (3.52%), accumulation around bra area (3.52%), breast (0.70%), anterior side of the thigh (0.46%), iliac (0.46%), axillary fold (0.23%) and gluteus (0.23%).

The patient satisfaction index seen in Graph 2 depicts the following percentages: 25% were very satisfied, 63% satisfied, 10% somewhat satisfied and 2% were unsatisfied. The 3D photographic analysis carried out by the independent observer presented the following distribution: 17% of cases were rated as 1 and 83% were rated as 2.

The minimum number of sessions required to achieve any level of clinical outcome in the body area can be seen in



**GRAPH 1:** Distribution of the body areas treated in the study



**GRAPH 2:** Patient satisfaction index

Table 1. It is worth to note that all areas required two sessions in order to acquire some satisfactory result, except for the anterior region of the abdomen, in which 21% of cases required only one session.

Adverse events observed were: late pain of varying duration within two to three days after the procedure, appearance of hematomas and 5 cases of panniculitis. The events were managed with analgesia, using 30mg codeine associated with 500mg paracetamol, 50U sodium heparin with 2.067mg nicotinate benzyl, and ultrasound sessions (Accent Ultra®, LBT Lasers, São Paulo, Brazil), respectively.

**TABLE 1: Distribution of minimum number of sessions required per area for achieving some level of clinical outcome**

TREATED REGIONS		N. PATIENTS
Abdomen	1 session	217
	2 sessions	58
FLANK	1 session	12
	2 sessions	96
OUTTER THIGH	1 SESSÃO	5
	2 session	8
BRA AREA	1 SESSÃO	2
	2 session	22
INNER THIGH	1 SESSÃO	0
	2 session	25
LATERAL ABDOMEN	1 SESSÃO	0
	2 session	22
AXILLARY FOLD	1 SESSÃO	0
	2 session	2
ARMS	1 session	0
	2 session	30
ANTERIOR THIGH	1 session	0
	2 session	3
BREAST	1 session	0
	2 session	5
INFRAGLUTEAL	1 session	3
	2 session	22
KNEE	1 session	3
	2 session	21

## DISCUSSION

Cryolipolysis targets only the fat cells in the selected region. The physician chooses the region to be treated and areas to place the application device. The device pulls and holds the fat between its two panels, automatically cooling it for one hour. The sensation is that of a firm pull, and the freezing action does not affect the skin or other organs and tissues. The epidermis and dermis are protected by a gel film during the session. For this reason, given that the contraindications for the procedure are observed, it can be performed in patients of any age, which is consistent with the present study, which included patients

between 13 and 69 years of age. The average age of 40 years observed in the present study is consistent with the literature, coinciding with the age when the greatest level of concern with the body takes place.<sup>11</sup>

The majority of the population in the present study lived in the Brazilian State of São Paulo, and in most of the cases had greater concern with the abdominal region (67.60%). This can be due to the trend to be overweight that is expected to occur in the population of more developed areas and the fact that the abdominal region is the primary body site that develops localized fat.

The rate of patient satisfaction and the independent observer evaluation carried out before treatment and eight months after the last session through 3D digital photographs presented high scores in the present study. The reduction of the treated fat, with some studies finding an average of 22.4% four months after the treatment,<sup>2, 4, 9, 12</sup> can explain the high effectiveness of the method and the resulting high degree of satisfaction in patients with good indication.

Another point of agreement would be the histological evaluation carried out in some studies, which confirm the gradual selective reduction of adipose tissue in humans and animals after cryolipolysis sessions.<sup>2, 9, 13, 14</sup> The exclusion of patients with obesity grades I, II and III according to the Abeso's body mass index contributed to the correct selection of the study patients, as well as to the high level of positive results.

All patients had late pain that lasted for two to three days after the procedure, nevertheless having been easily controlled by analgesia using 30mg codeine associated with 500mg paracetamol. The cases presenting hematomas were managed with 50U heparin sodium combined to 2.067mg nicotinate benzyl. The five cases of panniculitis were described as painful subcutaneous nodules, with absence of systemic signs or symptoms. The patients were followed up on weekly sessions with non-focused ultrasound (Accent Ultra®, LBT Lasers, São Paulo, Brazil), with complete clinical improvement of the picture. The authors of the present study did not observe bacterial or mycobacterial infections, or temporary alterations in the peripheral sensory nerves' function.

## CONCLUSIONS

Cryolipolysis is a non-invasive method for the selective reduction of fat that has shown efficacy in the reduction of subcutaneous tissue with minimal and reversible side effects in the present study. This technology should be used by dermatologists who have experience with it, always observing the contraindications, in order to achieve good results. ●

## REFERENCES

1. Myrer JW, Measom GJ, Fellingham GW. Exercise after cryotherapy greatly enhances intramuscular rewarming. *J Athl Train.* 2000;35(4):412-6
2. Avram MM, Harry RS. Cryolipolysis for subcutaneous fat layer reduction. *Lasers Surg med* 2009.;41(10): 703-8.
3. Nelson AA, Wasserman D, Avram MM. Cryolipolysis for reduction of excess adipose tissue. *Semin Cutan Med Surg.*2009;28 (4):244-9.
4. Jewell ML, Solish NJ, Desilets CS. Noninvasive body sculpting technologies with an emphasis on high-intensity focused ultrasound. *Aesthetic Plast Surg.* 2011;35(5):901-12.
5. Alderman AK, Collins ED, Streu R, Grotting JC, Silkin AL, Neligan P, et al. Benchmark outcomes in plastic surgery: National complication rates for abdominoplasty and breast augmentation. *Plast Reconstr Surg.* 2009;124(6):2127-33.
6. Desrosiers AE III, Grant RT, Breitbart AS. Don't try this at home: Liposuction in the kitchen by an unqualified practitioner leads to disastrous complications. *Plast Reconstr Surg.* 2004;113(1):460-4.
7. Zelickson B, Egbert BM, Preciado J, Allison J, Springer K, Rhoades RW, et al. Cryolipolysis for Non invasive fat cell destruction: Initial results from a pig model. *Dermatol Surg* 2009;35(10): 1462-70.
8. Manstein D, Laubach H, Watanabe K, Farinelli W, Zurakowski D, Anderson RR. Selective Cryolysis: A novel Method of non invasive fat removal. *Lasers Surg Med.* 2008;40(9): 595-604.
9. Coleman SR, Sachdeva K, Egbert BM, Preciado J, Allison J. Clinica efficacy of noninvasive cryolipolysis and its effects on peripheral nerves. *Aesthetic Plast Surg.* 2009;33(4):482-8.
10. Rotman H. Cold panniculitis in children. *Arch Dermatol* 1966; 94(6): 720-1.
11. Klein KB, Zelickson B, Riopelle JG, Okamoto E, Bachelor EP, Harry RS, et al. Noninvasive Cryolipolysis for subcutaneous fat reduction does not affect serum lipid levels or liver function tests. *Lasers Surg med* 2009 41(10):789-90.
12. Dover J, Burns J, Coleman S, et al. A prospective clinical study of noninvasive cryolipolysis for subcutaneous fat layer reduction-interim report of available subject data. *Lasers Surg Med.* 2009; S21:45. Aguardando respuesta autor!
13. Ferraro GA, De Francesco F, Cataldo C, Rossano F, Nicoletti G, D'Andrea F. Synergistic Effects of Cryolipolysis and Shock Waves for Noninvasive Body Contouring. *Aesthet Plast Surg.* 2012;36(3):666-79.
14. Mulholland RS, Paul MD, Chalfoun C. Noninvasive body contouring with radiofrequency, ultrasound, cryolipolysis, and low-level laser therapy. *Clin Plast Surg.* 2011;38(3):503-20.