

# Surgical treatment of the aging reversal lip

## Tratamento cirúrgico da inversão labial do envelhecimento

### Authors:

Heliane Sanae Suzuki<sup>1</sup>  
 Gabriela Bestani Seidel<sup>1</sup>  
 Vanessa Cristina Soares<sup>1</sup>  
 Themis Hepp<sup>1</sup>  
 Karin Helmer<sup>2</sup>

<sup>1</sup> Dermatologist Physician, private practice - Curitiba (PR), Brazil

<sup>2</sup> Collaborating Physician, Cosmiatry Ambulatory, Dermatology Department, Hospital de Clínicas da Universidade Federal do Paraná (UFPR) - Curitiba (PR), Brazil

### ABSTRACT

One of the signs of perioral aging is the lengthening of the upper lip followed by perioral sagging that leads to the depressed angle of the mouth. Various perioral rejuvenation techniques – such as the use of fillers and ablative techniques – are described, however the inversion of the lip does not usually fully improve with those treatment modalities. The authors describe three patients with depressed angles of the mouth that were surgically corrected through a simple, however little used technique, which produces satisfactory aesthetic results.

**Keywords:** mouth; aging; surgery, plastic.

### RESUMO

*Um dos sinais do envelhecimento perioral é o alongamento do lábio superior seguido de flacidez perioral que ocasiona a queda do ângulo da boca. São descritas várias técnicas de rejuvenescimento perioral, tais como preenchimentos e técnicas ablativas, observando, porém, que a inversão labial não costuma melhorar totalmente com essas modalidades de tratamento. Relatam-se três casos de queda do ângulo da boca corrigidos cirurgicamente por técnica simples, mas pouco utilizada, que apresenta resultados estéticos satisfatórios.*

**Palavras-chave:** boca; envelhecimento; cirurgia plástica.

### INTRODUCTION

Particularly evident in the perioral area, facial aging results from changes in the skin, subcutaneous tissue, muscles, and bones.<sup>1-5</sup> In the lower third of the face, facial aging entails the lengthening of the upper lip followed by perioral sagging and the resulting fall of the angle of the mouth,<sup>1</sup> which can be called frowning mouth and is associated with the formation of marionette lines.<sup>2</sup> The youthful, aesthetically ideal mouth resembles a rhombus-shaped diamond, with smooth contours extending between the commissures, with the cupid's bow well demarcated and protruding the philtrum.<sup>2</sup> With age, however, the loss of curvature and the fall of labial commissures lend a senile and saddened appearance.<sup>2</sup>

Among the techniques for perioral rejuvenation, the following can be highlighted: injections of cutaneous fillers (such as hyaluronic acid, which reconstruct lip volume and soften the grooves), dermabrasion and deep peels (which soften the rhytids), and botulinum toxin. Nevertheless, the improvement of the frowning and sad appearance of the mouth is not usually completely achieved with these modalities.<sup>2,3</sup>

The authors report on three cases of patients who underwent surgical correction of the fall of the labial commissures with a simple and rarely used technique, which nonetheless leads to satisfactory aesthetic results.

### Correspondence:

Dra. Heliane Sanae Suzuki  
 Rua Desembargador Otavio Amaral, 717  
 Cep: 80730-400 - Curitiba - PR, Brazil  
 E-mail: helianesuzuki@yahoo.com.br

Received on: 10 January 2014

Approved on: 10 July 2014

The present study was carried out at the Dermatology Department of the Hospital de Clínicas da Universidade Federal do Paraná (UFPR) - Curitiba (PR), Brazil.

Financial support: None  
 Conflict of interest: None

## METHODS

The correction of the frowning mouth is carried out by removing the excess of skin with an incision in the shape of a triangle (Figure 1). The base of the triangle (the line joining the points A and C) must be demarcated on the marionette line, starting at the edge of the skin with the semi-mucosa of the upper lip, taking care not to surpass the lower limit of the fold. After evaluating where and by how much it is necessary to raise the corner of the mouth, aiming to obtain a good aesthetic result, point B (the apex of the triangle) is marked. The end points of the line A-C (base of the triangle) are linked to point B. The exeresis of the marked skin is carried out, followed by hemostasis with cautery and simple suture using 5.0 mononylon. The suture must be started at point B, which should be joined to another point on the triangle's base (at the point where the greater elevation is intended), without the necessity of undermining the skin.

Post-operatively, the patients were instructed to restrict movement of the mouth during the first 24 hours. Sutures were removed after 7 days and the use of micropore tape over the scar was prescribed for 30 days.

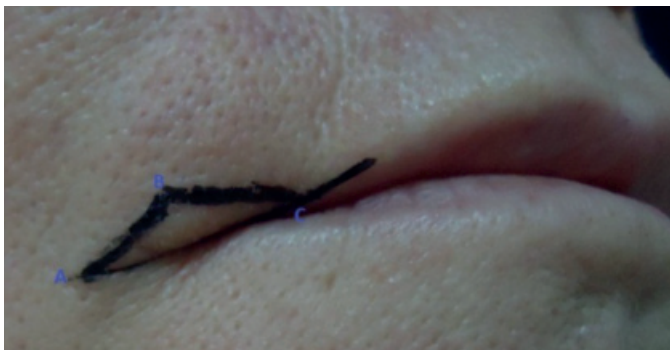
## RESULTS

The authors report 3 cases of surgical correction of the frowning mouth through the described technique: Patient 1 (47 years old), Patient 2 (45 years old), and Patient 3 (58 years old). Figure 2 depicts a satisfactory aesthetic result – both from the physician's and the patients' assessments. After 2 years of follow-up, the patients reported satisfaction with the good results achieved from the surgery.

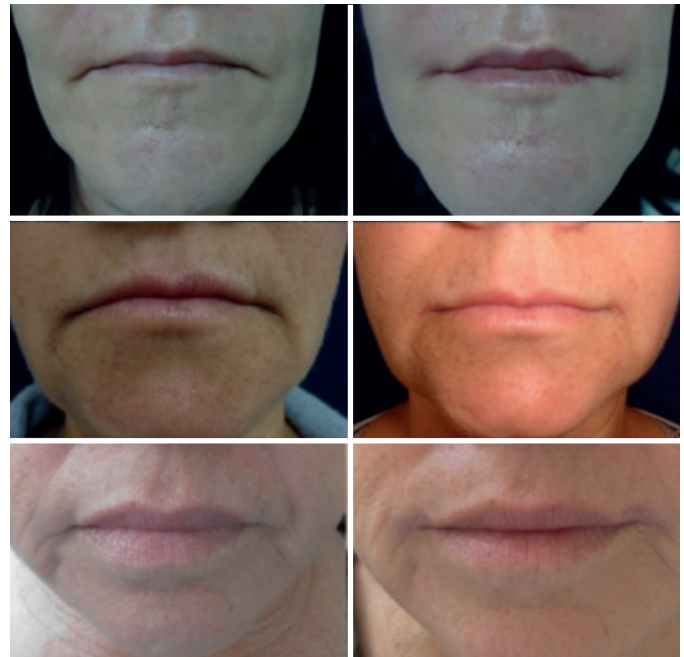## DISCUSSION

Perioral aging is caused by a number of factors, such as collagen degeneration, atrophy of facial muscles and maxillary and mandibular bone absorption.<sup>1,3,4</sup> In addition, the repeated movement of the muscles of facial expression, combined with the effects of the exposure to the sun, contributes to the alterations seen in aging.<sup>1</sup>

The literature describes several ways to surgically correct the fall of the angle of the mouth. 1-3 In the described cases the authors used the technique of Fereydoun Don Parsa et al.. These authors classified patients with labial reversal as follows: Type I (those who only have a fall of the labial commissures), Type II (in



**FIGURE 1:** The correction of aging-related labial reversal is carried out with the removal of the excess skin in the shape of a triangle, as depicted here



**FIGURE 2:** Pre-operative and 14thday post-operative, with satisfactory aesthetic results both in the physician's and the patient's evaluation

addition to the fall of the labial commissures there is a formation of marionette lines). Type I patients are treated with a triangular excision adjacent to the vermilion of the upper lip. In Type II patients, the excision is extended along the marionette lines, also with the aim of correcting them. As the patients studied did not have marked aging, the authors chose the Type I technique.<sup>2</sup>

The main complication reported post-operatively was the formation of visible scars, sometimes hypertrophic.<sup>2,3</sup> In most cases, however, there was significant improvement with this issue after a few weeks of follow-up. The studied patients presented normal healing with an almost unnoticeable scar.

## CONCLUSIONS

The frowning mouth lends a heavy facial expression, which in many cases cannot be corrected using only less invasive procedures. Often, surgical intervention is also required, which, as in the cases reported in the present study, proves to be effective, safe for ambulatory execution, and leads to excellent aesthetic results for the correction of aging-related labial reversal. ●

## REFERENCES

1. Marques A, Brenda E. Lifting of the upper lip using a single extensive incision. *Br J Plast Surg.* 1994;47(1):50-3.
2. Parsa FD, Parsa NN, Murarin D. Surgical correction of the Frowning Mouth. *Plast Reconstr Surg.* 2010;125(2):667-76.
3. Aiache AE. Rejuvenation of the perioral area. *Dermatol Clin.* 1997;15(4):665-72.
4. Sullivan PK, Hoy EA, Mehan V, Singer DP. An anatomical evaluation and surgical approach to the perioral mound and facial rejuvenation. *Plast Reconstr Surg.* 2010;126(4):1333-40.
5. Paixão MP, Montedonio J, Queiroz-Filho W, Pouza CET, Almeida AEF. Lifting de lábio superior associado à dermoabrasão mecânica. *Surg Cosmet Dermatol;* 2011;3(3):249-53.