

Surgical treatment of axillary hyperhidrosis: internal “shaving” of the sweat glands

Tratamento cirúrgico da hiperidrose axilar: "Shaving" interno das glândulas sudoríparas

ABSTRACT

Primary axillary hyperhidrosis is a common disease that affects the social and professional lives of individuals. There are various treatments described in the literature, such as topical, systemic, and surgical. The present study describes the technique applied in a female patient, bearer of axillary hyperhidrosis, who underwent surgical treatment of axillae, progressing with significant regression of local sweating. The objective of the present study is to demonstrate the effectiveness of this surgical technique, with low complication rates, as a therapeutic option for axillary hyperhidrosis.

Keywords: hyperhidrosis; axilla; dermatologic surgical procedures; sweat glands.

RESUMO

A hiperidrose axilar primária é doença comum, que afeta a vida social e profissional do indivíduo. Existem vários tratamentos descritos na literatura, como tópicos, sistêmicos e cirúrgicos. Relatamos a técnica empregada em uma paciente do sexo feminino, portadora de hiperidrose axilar, que realizou tratamento cirúrgico das axilas, evoluindo com regressão significativa da sudorese local. O objetivo deste trabalho é demonstrar a eficácia dessa técnica cirúrgica com baixos índices de complicações como opção terapêutica à hiperidrose axilar.

Palavras-chave: hiperidrose; axila; procedimentos cirúrgicos dermatológicos; glândulas sudoríparas.

INTRODUCTION

Primary axillary hyperhidrosis is characterized by excessive sweating in physiologically larger quantities than that needed for thermoregulation, being considered most often of idiopathic etiology. It has a major impact on quality of life, with limitations on professional life, social interaction, physical activity, and leisure. Its prevalence varies from 1–3% in the population, with a slight predominance in people of Jewish and Asian origin.^{1–4}

The treatment of axillary hyperhidrosis may be carried out conservatively with topical products, medicaments, iontophoresis, and botulinum toxin. When the clinical options do not present satisfactory results, surgical procedures are indicated, with a preference for localized resection. Comparatively, transthoracic sympathectomy has a higher risk of complications, such as chest wall paresthesia (50%), pneumothorax (7%),

New Techniques

Authors:

Osório de Castro Alves Corrêa Lara¹
Ed Wilson Tsuneo Rossoe²

¹ Dermatology Resident Physician at Complexo Hospitalar Padre Bento de Guarulhos - Guarulhos (SP), Brazil

² Plastic Surgeon; Master in Health Sciences at the Hospital Civil Servants (HSPE) - Recife (PE), Brazil

Correspondence:

Dr. Osório Alves Corrêa de Castro Lara
Rua Terceiro Sargento Alcides de Oliveira,
101 apto. 31B
Cep: 07050-030 – Guarulhos – SP, Brazil
E-mail: osoriolar@hotmail.com

Received on: 21 July 2013

Approved on: 1 April 2014

The present study was carried out at Complexo Hospitalar Padre Bento de Guarulhos - Guarulhos (SP), Brazil.

Financial support: None
Conflict of interest: None

Horner's syndrome (<1%), and hemothorax (<1%), in addition to compensatory sweating in other body sites.³⁻⁶

Local resection of the skin and subcutaneous tissue was used for many years, since the complete exeresis of the sweat glands guaranteed the definitive solution to hyperhidrosis, however it frequently entailed scars with fibrosis and restriction of movement. On the other hand, the removal of the glandular tissue without resection of the skin can be performed through curettage or ablation in a "blind" way (without visual control) – as it is done in liposuction with curettage – or under visual control, usually with the eversion of the borders of the surgical wound in order to visualize the glandular tissue. These two techniques provide additional options for axillary hyperhidrosis resistant to clinical treatment, besides having less morbidity when compared with the already mentioned surgical techniques.^{3,6-9}

CASE REPORT

A 26-year-old mulatto female patient with a history of excessive axillary sweating for five years sought care at the dermatology service. She described noticing the onset of the condition after taking a daytime job as a keeper of an uncovered parking lot, where she had to wear a black-colored uniform. Due to the need for frequent changes of the uniform during the work shift because of excessive sweating, she decided to seek care. Once diagnosed with axillary hyperhidrosis, a treatment with aluminum hydrochloride associated with botulinum toxin was administered with excellent results during the first six months. Nevertheless, after one year of treatment the patient's condition worsened. She was then referred for local surgery, with procedures performed in each of the axillae during different months.

METHODS

The patient, who had suspended the use of topical products in the axillae for five days, was placed in the operating room in the supine position, at a room temperature of 21°C. The

demarcation of the hyperhidrotic area was carried out through the Minor iodine-starch test (Figure 1a), with subsequent local antisepsis with pyrrolidone iodine solution and local anesthesia of the affected area. An incision was performed in the axillary crease aligned with the tissue's tension lines (Figure 1b). The detachment of the skin was carried out in the subcutaneous plane, being followed by rigorous hemostasis with electrocoagulation. The borders of the wound were everted, and under direct visual observation, the shaving of the dermis was conducted with surgical scissors, (Figure 1c) with the material removed being sent for histological study (Figure 1d). After the procedure, the skin was sutured with 4-0 nylon, with the placement of a penrose drain. A dressing was applied until the following day.

On the first post-operative day, the penrose drain was removed, with no local complications – such as bleeding, hematoma, necrosis, infection, seroma, or dehiscence – being observed. The patient was instructed as to local care of the surgical wound, antibiotic therapy with cephalexin for 7 days, and restriction of vigorous exercise with the upper limbs for the same period.

The reassessment of the sweating was performed using the iodine-starch test after the procedure, at 14 months in the right axilla and at 16 months in the left axilla, with no sweating being observed in the right axilla (Figure 2a) and a discrete area of residual sweating in the left axilla (Figure 2b).

DISCUSSION

In axillary hyperhidrosis, 50% of the sweat is produced by apocrine glands and 50% by eccrine glands. Using the shaving technique with surgical scissors, the target is the deep dermis and the subdermis, which is the most superficial part of the subcutaneous. In this way, two types of glands are removed: the apocrine (that are located closely adjacent to the hair follicles) and the eccrine (that are partially removed, except for the complete removal of the dermis).⁷

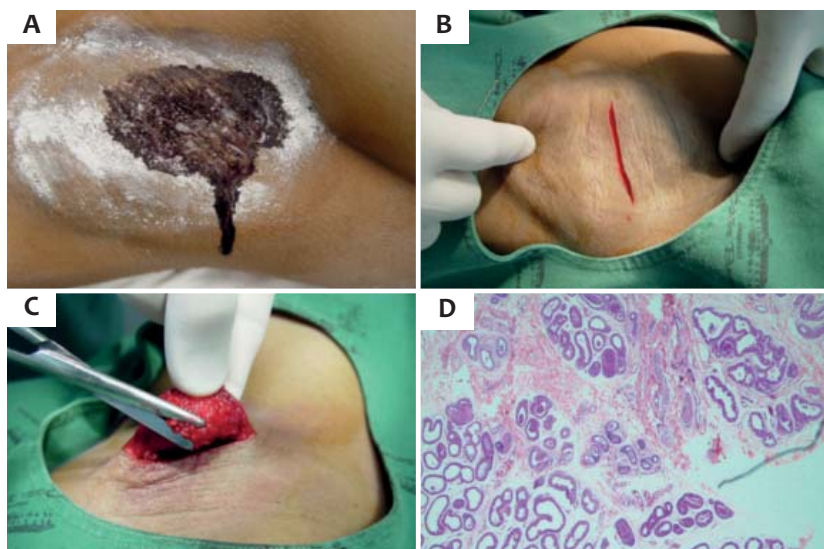

FIGURE 1: A - Intense sweating after 11 minutes into the test with iodine-starch. B - Incision of the skin in an axillary fold C - Internal shaving of the hair follicles and glandular tissue with surgical scissors under direct visualization. D - HE 40x, with the presence of eccrine and apocrine sweat glands

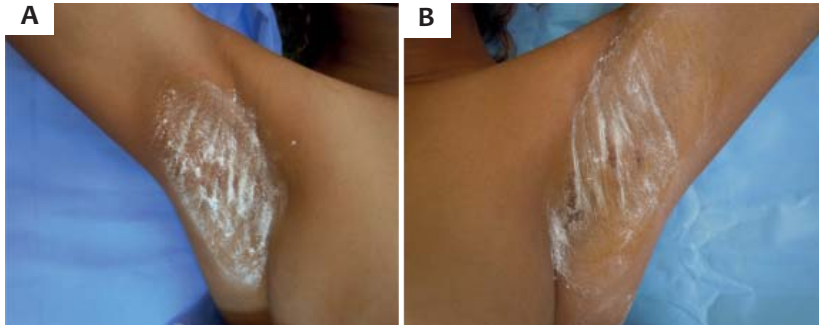


FIGURE 2: **A** - Absence of sweating at rest in the right axilla, after 15 minutes at a temperature of 21°C, with iodine-starch test. **B** - Presence of mild residual sweating in the left axilla.

Ideally, the permanent removal of axillary sweat glands results in permanent improvement of hyperhidrosis. However, the limited data regarding the results of curettages and the variations in surgical techniques do not allow definitive conclusions on the effectiveness of the procedure in the long run. Continued sweating may occur as a result of incomplete removal of eccrine glands in certain areas or due to local compensatory sweating. The skills of the surgeon performing the procedure can also influence the treatment's efficacy.

The final cosmetic result was considered good, showing no cicatricial retraction. The local sensitivity was preserved, and there was a decrease of the axillary hairs, which was not cause for dissatisfaction by the patient.

CONCLUSION

The authors consider the described surgical technique for axillary hyperhidrosis as a safe method, with low complication rates and an excellent additional option for cases where there is resistance to conservative treatments. Due to the fact that the study was carried out with only one case, the authors note that recurrences cannot be excluded for the method.●

Acknowledgements:

The authors would like to thank Dr. José Antonio Tebcherani (for the photograph of the histopathological examination) and Dr. Luiz Horta Cristiano de Lima Junior (for the examination's report).

REFERENCES

- Hornberger J, Grimes K, Naumann M, Glaser DA, Lowe NJ, Naver H, *et al*. Recognition, diagnosis, and treatment of primary focal hyperhidrosis. *J Am Acad Dermatol*. 2004;51(2):274.
- Fenili R, Fistarol ED, Delorenze LM, Demarchi AR, Matiello M. Prevalência de hiperidrose em uma amostra populacional de Blumenau-SC, Brasil. *An Bras Dermatol*. 2009;84(4):361-6.
- Gontijo GT, Gualberto GV, Madureira NAB. Atualização no tratamento de hiperidrose axilar. *An Bras Dermatol*. 2011;3(2):147-51.
- He J, Wang T, Dong J. Excision of apocrine glands and axillary superficial fascia as a single entity for the treatment of axillary bromhidrosis. *J Eur Acad Dermatol Venereol*. 2012;26(6):704-9.
- Haider A, Nowell S. Focal hyperhidrosis: diagnosis and management. *CMAJ*. 2005;172(1):69-75.
- Coelho MC, Lira EJT, Zanin AS, Gonçalves JL, Neto NB, Júnior WSS. Simpatectomia torácica por videotoracoscopia no tratamento da hiperidrose palmar e axilar. *An Bras Dermatol*. 2002;77(2):171-83.
- Odo MEY, Chichierchio A. Curetagem cirúrgica das glândulas sudoríparas (endoshave axilar). In: Hessel DA, Almeida ART. Hiperidrose e toxina botulínica. 2003. p.121-24.
- Bechara FG, Sand M, Hoffmann K, Altmeyer P. Aggressive shaving after combined liposuction and curettage for axillary hyperhidrosis leads to more complications without further benefit. *Dermatol Surg*. 2008;34(7):952-3.
- Stori WS, Neto NB, Coelho MS, Pizarro LDV, Guimarães PSF. Bloqueio por clipagem de gânglios simpáticos torácicos no tratamento da hiperidrose. *An Bras Dermatol*. 2006;81(5):425-32.