

Paramedian forehead flap for complex nasal defects following Mohs micrographic surgery

Retalho paramediano frontal na reconstrução de defeitos nasais complexos após cirurgia micrográfica de Mohs

ABSTRACT

Introduction: The paramedian forehead flap has been used for centuries in nasal reconstruction. It is a unique flap in terms of restoring complex nasal defects. It can adequately restore contour, texture, projection of the nasal tip and convexity of the ala, especially when combined with cartilage grafting.

Objectives: To evaluate the versatility of the paramedian forehead flap in nasal reconstruction following Mohs micrographic surgery, especially in an outpatient setting and under local anesthesia. Furthermore, to discuss traditional approaches versus more recent refinements on its design and execution.

Methods: Retrospective study of patients with surgical defects resulting from Mohs micrographic surgery that have been repaired using the paramedian forehead flap.

Results: Nineteen patients were included in the study. Restoration of the nasal mucosa was required for full thickness defects in 4 (22%) patients. Structural support provided by auricular cartilage graft was required in 12 (67%) patients. The flap pedicle was designed ipsilaterally to the defect in 14 (74%) patients. Complications were minimal and unusual.

Conclusions: The paramedian forehead flap is a valuable technique in the repair of extensive and deep nasal defects following Mohs micrographic surgery. With proper surgical planning, adequate measures for patient comfort, and meticulous technique, the paramedian forehead flap can be safely performed in an outpatient setting, achieving unique results in nasal reconstruction.

Keywords: Mohs surgery; surgical flaps; nose neoplasms.

RESUMO

Introdução: o retalho paramediano frontal (RPF) é utilizado há séculos em reconstrução nasal. É retalho único em termos de restauração de defeitos nasais complexos. Ele é capaz de restaurar contorno, textura, projeção da ponta nasal e convexidade da asa, principalmente quando combinado com enxerto de cartilagem.

Objetivos: avaliar a versatilidade do RPF na reconstrução nasal após cirurgia micrográfica de Mohs, sobretudo num ambiente ambulatorial e sob anestesia local, bem como discutir abordagens tradicionais e refinamentos recentes em seu design e execução.

Métodos: estudo retrospectivo de pacientes com defeitos cirúrgicos decorrentes de cirurgia de Mohs reparados com o RPF.

Resultados: 19 pacientes foram incluídos no estudo. Restauração da mucosa nasal foi necessária para defeitos de espessura total em quatro pacientes (22%). Suporte estrutural fornecido por enxerto de cartilagem auricular foi necessário em 12 (67%) pacientes. O pedículo do retalho foi desenvolvido ipsilateral ao defeito em 14 pacientes (74%). Complicações foram mínimas e incomuns.

Conclusões: o RPF é retalho valioso no reparo de defeitos nasais extensos e profundos após cirurgia de Mohs. Com planejamento cirúrgico adequado, medidas para conforto do paciente e técnica metódica, o RPF pode ser realizado ambulatoriamente com segurança, atingindo resultados exclusivos na reconstrução nasal.

Palavras-chave: Cirurgia de Mohs; retalhos cirúrgicos; neoplasias nasais.

Article Original

Autores:

Felipe Bochnia Cerci¹
Tri H Nguyen²

¹ Dermatologist Physician. Dermatology Fellowship from Wake Forest University - North Carolina, USA. Dermatologic Surgery and Mohs Surgery Preceptor at the Santa Casa de Curitiba - Curitiba (PR), Brazil

² Private Practice Dermatologist Physician. Previous Director of Mohs Surgery Fellowship at the MD Anderson Cancer Center - University of Texas, Houston (TX), USA

Correspondence:

Hospital Santa Casa de Misericórdia de Curitiba
Departamento de Dermatologia
A/C Dr. Felipe Bochnia Cerci
Praça Rui Barbosa, 245 - Centro
Cep: 80010-030 - Curitiba - PR, Brazil
E-mail: cercihc@hotmail.com

Received on: 2 March 2014
Approved on: 17 March 2014

This study was performed at Mohs & Dermatology Associates - Northwest Diagnostic Clinic - Houston (TX), USA.

Financial support: None
Conflict of interest: None

INTRODUCTION

The paramedian forehead flap (PFF) has been used for centuries in nasal reconstruction. It is a unique flap in terms of restoring complex nasal defects. Overtime, numerous modifications and refinements have been described to improve its outcome and versatility.¹ Adequate training, good surgical technique, and careful planning are necessary to achieve optimal results.

The PFF is classified as a staged interpolation flap for having the following features: vascular pedicle based on a named artery and/or its tributaries, donor location distant and noncontiguous from the defect, and more than one stage for completion. Its main indications are large and deep wounds located on the distal nose (tip and ala).² It can uniquely restore contour, texture, projection of the nasal tip and convexity of the ala, especially when combined with cartilage grafting. Due to its bulkiness, the PFF is less ideal for the upper nose (nasal sidewall, dorsum and root), which has thinner skin. Disadvantages related to the flap are the necessity for a multi-staged procedure and the forehead donor site scar, which is usually inconspicuous.

The purpose of this study is to evaluate the versatility of the PFF for nose reconstruction after Mohs micrographic surgery, especially in an outpatient setting under local anesthesia. Furthermore, the article will discuss traditional approaches versus more recent refinements on its design and execution.

METHODS

Patients

This was a retrospective study of 19 patients whose nasal defects were repaired with the PFF after Mohs micrographic surgery. Cases were identified from a private Mohs practice from 2010 to 2013. Through chart review and by analysis of photographic documentation, the following demographic and surgical data were examined: age, gender, tumor type, defect sizes and subunits involved, number of Mohs stages and repair stages, supplementary measures for patient comfort, lining restoration, cartilage grafts, pedicle design, donor site closure, postoperative complications, smoking habits, follow-up period and outcomes.

All patients signed an informed consent form prior to surgery allowing publication of photographs in scientific journals. All procedures (Mohs surgery for tumor clearance and subsequent reconstruction) occurred in an outpatient setting. Nerve blocks (supraorbital and supratrochlear) and or tumescent anesthesia supplemented local anesthesia. Prior to the procedure, patients received oral analgesics, benzodiazepines or antibiotics, if necessary. Most PFF repairs followed the Mohs surgery on the same day. Typically, the second stage took place 3 to 4 weeks after the first stage. For those that required a third stage, it was performed 3 to 4 weeks after the second.

Flap design and execution

The PFF requires a substantial knowledge of anatomy, surgical planning, and surgical skill for its correct design and execution. The primary vascular supply for the PFF is the supratrochlear artery, which is located at the medial border of the

eyebrow, 1.5 to 2 cm from the facial midline. Although a Doppler may help identify the artery, this is usually not necessary as the location is highly predictable. The artery emerges from the supratrochlear foramen and below the orbital rim lies deep to periorbital muscles (orbicularis oculi and frontalis). Above the rim, the artery pierces the frontalis muscle and gradually becomes more superficial, reaching the subcutis midway up the forehead. Therefore, dissection of the pedicle should be below deep fascia near the orbital rim. Secondary vascular supply to the PFF include branches from the dorsal nasal artery.³ Charts 1 and 2 describe a stepwise approach for the two-stage flap design and execution (Figures 1-6).

RESULTS

Nineteen patients were included in the study. Demographic and surgical data are shown in table 1. Age of the patients varied from 36 to 90 years (mean age, 67.1 years), with a predominance of men (12 men x 7 women). Basal cell carcinoma was the most common tumor (n=12), followed by squamous cell carcinoma (n=2), collision tumor (n=2) and basosquamous carcinoma (n=1). In two patients, the PFF was performed as a rescue flap to correct anatomic distortions and impaired nasal valve function from previous reconstructions. Most patients received either anxiolytics and or oral analgesics as adjuncts to local anesthesia during surgery (Table 2). Only one patient was a smoker.

The number of Mohs stages necessary to achieve clear margins varied from 1 to 5 (mean, 2.6). Defect sizes ranged from 2 cm x 1.9 cm to 4.5 cm x 4 cm (mean, 2.9 cm x 2.8 cm). Sixteen (84%) patients had defects that involved multiple subunits (Table 3). Tip (n=15) and ala (n=12) were the most frequent involved. Resection of an additional portion of a subunit was performed in 17 (90%) patients. The PFF was combined with other closures in four patients that had wounds extending beyond the nasal subunits.

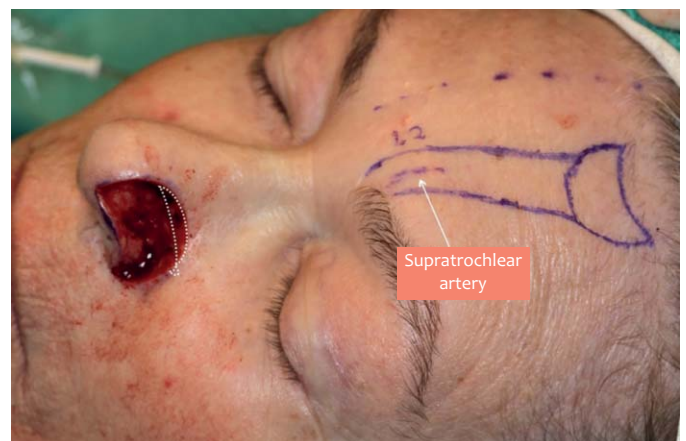


FIGURE 1: Ipsilateral pedicle (1.2 cm wide) positioned 1.5 to 2 cm from the midline. The left ala subunit was completely removed. The part of the defect that involved the nasal sidewall (dotted) was left to heal by second intention

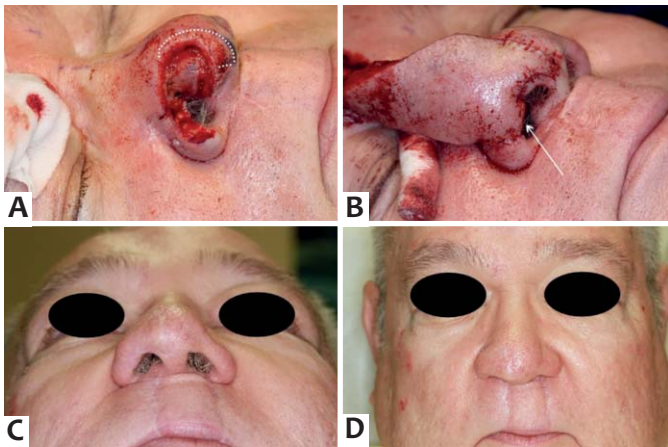


FIGURE 2: A) Full-thickness defect involving the nasal tip and right ala. The remaining portion of the hemitip subunit (dotted) was resected. B) Folded PFF (arrow) in place. C) 14 month follow-up. Alar contour preserved without nasal vestibule compromise. D) Preservation of alar creases. Upper lip scar due to prior Abbé flap

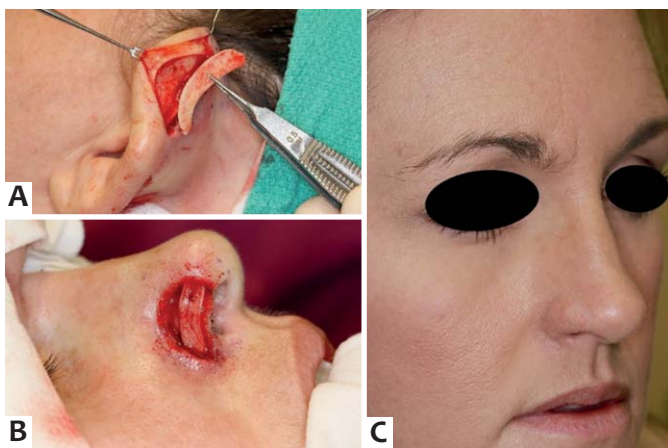


FIGURE 3: A) Cartilage graft harvested from the antihelix via posterior incision. B) Cartilage graft in place. C) 9 month follow-up with excellent functional and aesthetic results.

Mucosal restoration was required for full-thickness defects in 4 (22%) patients and was achieved by folded PFF (n=3) or primary closure (n=1). Structural support provided by ear cartilage was necessary in 12 (67%) patients. Cartilage was harvested from the conchal bowl (n=8) or scaphoid fossa/antihelix (n=4). A posterior incision to harvest the graft was used in 9 (75%) of the 12 patients.

The flap pedicle was designed ipsilateral to the defect in 14 (74%) patients (Figure 1) and contralateral in 2 (10%). The three remaining patients had defects centrally located. Closure of the forehead was most commonly accomplished by primary closure combined with bovine dermal collagen (n=15) or second intention healing (n=3). Only one patient had the forehead closed completely. Bovine dermal collagen was also used in 18

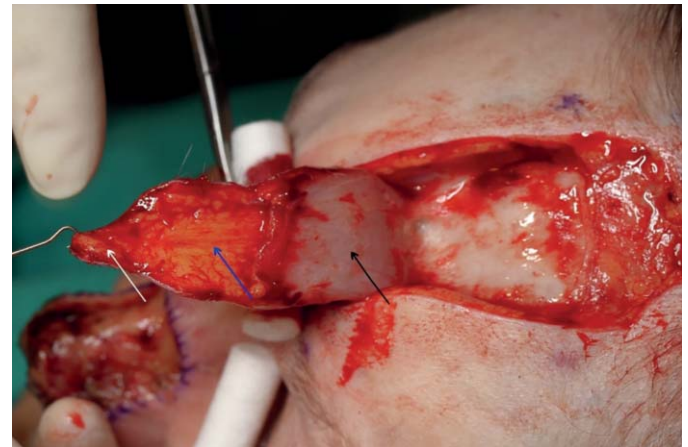


FIGURE 4: The flap is elevated in three different planes. Superficial subcutaneous (white arrow), deep subcutaneous (blue arrow), and subgaleal (black arrow)

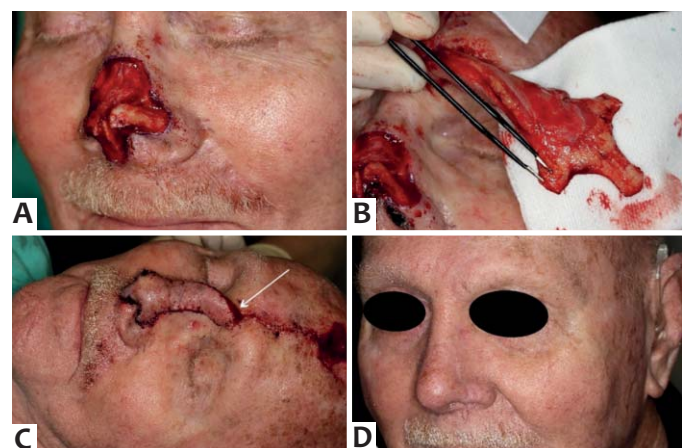


FIGURE 5: A) Extensive defect with cartilage grafts in place. B) Flap elevated in the superficial subcutaneous in its most distal portion. C) Bovine dermal collagen on the forehead and on the exposed pedicle (arrow). D) 6 month follow-up with restoration of the nasal contour

(95%) patients to cover the exposed surface of the pedicle (Figure 5).

Complications were minor and uncommon (Table 4). Three complications occurred following the first stage. One patient had post-operative bleeding immediately after surgery, which required additional hemostasis for control. This patient was taking two anticoagulants. Another patient developed infection on the cartilage donor site and one superficial tip flap necrosis (<5% of flap surface). The infection was treated with oral antibiotic whereas the necrosis was excised and the flap repositioned, which required an extra stage. Following the second stage, three patients had complications. Two had superficial and proximal necrosis (10 and 40% of flap surface) due to aggressive thinning. Both were treated with wound care and

CHART 1: Stage 1. Paramedian forehead flap - steps and comments

STEPS	COMMENTS
1 Outline natural landmarks prior to anesthesia.	Outline nasal subunits. If more than 50% are involved, consider resecting the remainder of the subunit. (Figure 1)
2 Create a template of anticipated repair (defect +/- adjacent subunits)	Use the suture foil as a template. The template should be based on the unaffected contralateral half, if possible. For deeper defects, cover the wound's deep portions with moist gauze and base the foil template on the more superficial dimensions (height x width, rather than height x width x depth). Create the template before excising any subunit to avoid artificially enlarged dimensions due to wound contraction. If repairing the mucosa with the flap, create separate templates: one for the mucosa portion and another for the surface portion.
3 Decide the pedicle's side (ipsilateral X contralateral).	An ipsilateral pedicle is preferable in most cases (Figure 1). Advantages: less torsion and twisting as the flap is rotated, shorter distance to defect (shorter length required), reduced postoperative visual obstruction.
4 Transfer the template to the forehead.	Rotate it 180°. Use suture or gauze to estimate the flap's range.
5 Outline pedicle.	Base it on the supratrochlear artery, located 1.5 to 2cm from the midline (Figure 1). The pedicle's width should be between 1 and 1.5cm. Wider pedicles restrict the flap's mobility compromising the blood flow during the movement of the flap. If possible, the pedicle's medial incision should run downwards to the glabella/nasal root (to recruit branches of the dorsal nasal artery). The lateral incision usually stops at the eyebrow.
6 Anesthesia	Local anesthesia with nerve blocks (supratrochlear and supraorbital) or tumescent anesthesia. Consider benzodiazepines and analgesics for patient comfort. Avoid anesthetizing all areas at the same time. Stage the anesthesia to maximize patient comfort. First, anesthetize the auricular cartilage donor site and then the forehead. Remove the cartilage and start to harvest the flap. Only after the flap has been partially elevated, anesthetize the nose. On the nose, consider supplementing with bupivacaine for a longer lasting action.
7 (#) - Repair of the nasal lining	Primary closure, hinge turnover flap, folded PFF (Figure 2), mucosa flaps.
8 (*) - Cartilage graft harvest	The antihelix or concha are ideal areas. Antihelix cartilage (Figure 3) is better for long, straight and flexible segments, whereas conchal cartilage is better for grafts that require more curvature, substance, and rigidity. The grafts must be longer than the horizontal extent of the defect in order to be properly fixed. If necessary, sculpt the cartilage to avoid sharp edges. Apply a temporary pressure dressing on the donor area.
9 (*) - Ear closure	The ear is a common site of hematoma after cartilage harvesting. Suture it first and place a bolster dressing before incising the forehead.
10 (*) Suture the cartilage to the nose.	Create "pockets" on each side of the defect with the scalpel blade. The cartilage will be inserted into these pockets. Figure of 8 suturing: helpful to secure one cartilage free edge to another. Horizontal mattress or interrupted sutures: they help to stabilize the graft over the underlying cartilage (e.g. graft for the nasal tip) or to stabilize the graft at alar rim (Figure 3).
11 - Incise the flap.	At the upper edge of the flap, hyperbevel the incision to create a delicate border (provides a better fit for the ala, infratip, and columella). At other borders, incise vertically.
12 - Harvest the flap.	The flap is elevated in three different planes. At the superior margin, elevate it in the superficial subcutaneous and gradually deepen into the deep subcutaneous and subgaleal plane as the dissection approaches the base of the pedicle in the eyebrow (Figure 4). At the inferior margin (at least 3cm above the orbital rim), undermining must be subgaleal to avoid transection of the supratrochlear artery.
13 - Prepare the defect.	Trim its edges, making them perpendicular, except for the infratip. The latter must have a beveled edge to provide a better fit for the hyperbeveled edge of the flap.
14 - Debulk the distal portion of the flap.	When necessary, remove the excess subcutaneous tissue from the distal portion of the flap, leaving a thin layer of subdermal fat. Evaluate the vascularization (bleeding at the flap's borders) as it gets "thinner".
15 - Suture the donor area.	The forehead is closed as much as possible, in 3 planes. Cover the remaining areas with bovine dermal collagen (Figure 5C) or leave them to heal by second intention. Subgaleal undermining provides additional laxity.
16 - Suture the flap to the nose.	Start from the tip with continuous or simple sutures. Dermal sutures are not necessary for most of it.
17 - Cover the pedicle.	The exposed surfaces of the pedicle are common sources of postoperative bleeding. If possible, cover them with bovine dermal collagen or Surgicel® to reduce this possibility (Figure 5C).
18 - Pedicle dressing	Wrap the pedicle with vaseline impregnated gauze, without excessive pressure.

Step 7: Required for full-thickness defects. * Steps 8, 9 and 10: cases that require cartilage graft.

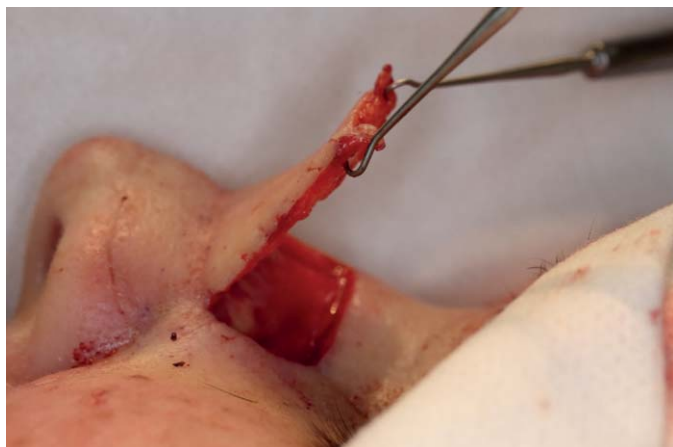


FIGURE 6: Flap elevated for “thinning” during the second stage. This is the appropriate thickness for this location

healed uneventfully. One patient had full-thickness necrosis (40%) associated with infection. He was treated with oral antibiotics and excision of the necrotic area, followed by flap repositioning (Figure 7). Complication after the third stage occurred in only one patient, who developed superficial necrosis (25% of flap surface) from aggressive thinning. None of the patients who had complications were current smokers. Despite complications, all patients had excellent functional and aesthetic results. No tumor recurrences occurred after follow-up period ranging from 4 to 49 months (mean, 29 months).

DISCUSSION

The nose is one of the most common locations for skin cancer and frequently represents a challenge for reconstruction after surgical defects. Closure options are individualized for each patient and defect. For large defects on the distal nose, however, options that achieve a good functional and aesthetic outcome are limited. When wounds are extensive, deep, and or involve missing cartilage or mucosal lining, no other repair can approach the consistency and predictability of the PFF.

The subunit principle is an important concept in reconstruction.⁴ If a defect involves greater than 50% of a subunit, excising the residual skin and resurfacing the entire subunit may

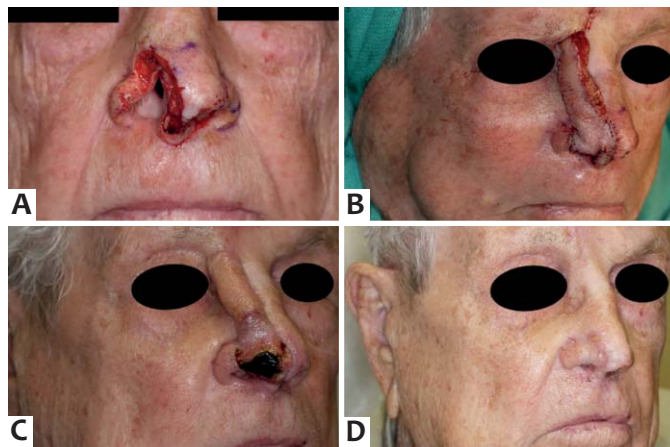


FIGURE 7: A) Full-thickness defect involving the right nasal ala, tip and columella. B) Folded PFF. C) Full-thickness necrosis of the distal portion of the flap. Necrotic area was later excised and flap repositioned. D) 3 month follow-up with good functional and aesthetic results.

yield better aesthetic outcomes (Figure 1). Just as a damaged fender or car door is completely replaced for better contour and camouflage, the nose also benefits from subunit repair. This principle, however, is not absolute.⁵ Excellent results may be achieved with partial subunit replacement. In this study, three (16%) patients had partial subunit resections (hemitip) with excellent results (Figure 2). Fourteen (74%) patients had complete subunit excision. Among those, seven (50%) also had partial excision of an additional subunit.

The PFF should be thought of as a robust surface covering that can provide soft tissue thickness but not structural support. Nasal lining and structural cartilage are the infrastructures that must be either intact, supplemented, and or restored prior to the PFF.⁶ Options to restore small mucosal defects (<1cm) include a turnover hinge flap, turndown of a forehead flap extension, a full-thickness skin graft (FTSG), and bipedicle vestibular skin advancement flap. Larger lining restoration may require a turnover forehead flap, FTSG vascularized by an overlying PFF, or intranasal lining flaps (septal mucoperichondrial hinge flap, composite septal chondromucosal pivotal flap).^{7,8} Intranasal mucosal flaps are difficult to perform without conscious sedation or general anesthesia. Other options above, however, may be successfully executed under local anesthesia.

CHART 2: Stage 2. Paramedian forehead flap – steps and comments

STEPS	COMMENTS
1 – Pedicle division. 2 – Suture the pedicle’s base.	Incise the pedicle in a V shape, 2 cm from its insertion on the forehead/eyebrow. The closure can be primary or using the proximal portion of the V-shaped pedicle. The repositioning of the eyebrow is crucial in all cases and may require a crescent excision above the eyebrow.
3 – Trim and thin the flap.	Elevate the proximal portion of the flap carefully, incising the suture lines of Stage 1. Outline the excess skin to be excised. Trim and thin the flap as needed (Figure 6).
4 – Suture the remaining flap.	Re-approximate the borders cautiously, in 2 planes.

When required, intermediate procedures (flap debulking and thinning, cartilage insertion), should occur prior to pedicle division.

Table 1: Demographic and surgical data

Age (years)	Gender	Tumor	Mohs stage	Defect (cm)
36 to 90	7 women 12 men	BCC (12) SCC (2) Collision (2) Basosquamous carcinoma (1) * revision (2)	1 to 5 (mean = 2.6)	2 x 1.9 to 4.5 x 4 (mean = 2.9 x 2.8)

* The PFF was performed as a rescue flap to correct anatomical distortions and nasal valve functionally compromised from previous reconstruction.

TABLE 2: Supplementary measures for patient comfort

	Tumescent anesthesia	Analgesics	Benzodiazepines
Number of patients	6 (32%)	7 (37%)	11 (58%)

* Some patients received combined measures

TABLE 3: Number of involved subunits

Subunits	Patients (N=19)
1	3
2	4
3	3
>3	9

Cartilage grafts are either structural (native cartilage present but additional needed for support) or restorative (replacing what was removed). Structural functions of cartilage include: 1) preventing tissue contraction and distortion, 2) bracing heavy flap tissue, 3) maintaining airway patency and augmenting the internal nasal valve, and 4) achieving contour support (i.e. nasal tip graft for better projection).² Donor sites for cartilage grafts

may include the antihelix (scaphoid fossa) and the conchal bowl from one or both ears.^{9,10} Other cartilage sources, such as a cadaveric or patient's rib and nasal septum are beyond the scope of this article.

Incisions for harvesting cartilage may be either anterior or posterior. Anterior incisions are easier for access, but scars are more noticeable. Antihelical cartilage is ideal for long, straight and flexible segments, whereas conchal cartilage is ideal for grafts that demand more curvature, substance, and rigidity. Conchal grafts work better to avoid nasal valve or lobule collapse, and for collumela and tip projection. Antihelical cartilage is better suited to avoid alar rim contraction (Figure 3).^{9,10} Sculpting and beveling of the graft is often necessary to achieve the desired thickness, contour, shape, and tapered edges. This should be carefully done since cartilage is a fragile structure and may break during the process. Traditionally, a number 15 blade is used for sculpting. However, a schick blade allows a more delicate sculpting and graft contour if properly used. Cartilage grafts may be safely harvested under local anesthesia.¹¹ Only one patient developed a postoperative infection, which resolved after oral antibiotics. Postoperative pain after PFF is variable. However, if cartilage grafting was performed then the auricular donor site is predictably more painful after surgery than the forehead flap donor site. Injecting long acting local anesthetic (Bupivacaine) after closing the ear donor site and postoperative analgesics (anti-inflammatory/narcotic combination) is advised for patient comfort.

Whether the PFF should be completed in two or three stages is a matter of debate. Folded PFFs that restore nasal lining absolutely require three stages (Figure 2). The first stage harvests

TABLE 4: Complications and management

Complications	1st Stage	2nd Stage	3rd Stage	Management
Bleeding	*1 (flap)			Additional hemostasis.
Infection (site)	1 (concha)	**1 (flap's tip)		Oral antibiotics; wound care.
Superficial necrosis (#)	1 (5%)	2 (10% and 50%)	1 (25%)	Wound care. For the case of the 1st stage, the necrosis area was excised and the flap repositioned.
Full-thickness necrosis (#)		**1 (40%)		The necrosis area was excised and the flap repositioned.

Flap's surface in percentage terms. * The patient was using two anticoagulants. ** Same patient.

the flap and folds it to provide both nasal lining and surface covering. The second stage (3 weeks) retains the pedicle, but opens the PFF margin at the alar rim to debulk excess tissue and to insert cartilage support. The third stage (6 weeks) divides the pedicle and sculpts the flap further for completion. PFFs that are not folded to restore lining may also be staged in 3 sessions.¹² The first stage incorporates cartilage support and PFF creation and inset. The second stage (3 weeks) elevates the flap partially and debulks excess tissue to improve contour. The third stage (6 weeks) then divides the pedicle. The main advantage of the three-stage PFF is the ability to sculpt a thin, supple contour in patients with delicate nose tips and ala. Two stage flaps in these patients often result in bulbous, thick contours. Disadvantages of the three-stage PFF are the delay in pedicle division and the extra procedure. However, the three-stage procedure is more reliable in smokers as the flap contains muscle and has a very robust blood supply. It may also be of benefit in cases where a profound underlying lining and cartilaginous reconstruction have been performed, as the frontalis provide an extremely rich anastomotic vascular network.¹³ Six patients (31%) required a three-stage PFF in this study. Three were submitted to folded PFFs, two required a more aggressive thinning, and one needed repositioning of the flap due to distal necrosis.

For most patients, the two-stage approach is safely performed by debulking the distal portion of the flap at the first stage. As long as a thin layer of subdermal fat is preserved, then the supratrochlear artery is protected.¹³ Thinning of the proximal portion of the flap is usually performed at the time of pedicle division and should be carefully done (Figure 6). If elevation and thinning are too aggressive, necrosis may result.

Pedicle side is an important consideration when designing the PFF. Traditionally, the pedicle has been designed contralateral to the defect to minimize its torsion. However, a narrow pedicle (1 to 1.5 cm) allows an ipsilateral design without concerns about significant torsion.¹⁴ Moreover, the ipsilateral design increases the flap reach. Further modifications that increase flap length include extending the incisions of the pedicle below the orbital rim,^{4,6,15} and extension of the flap into the anterior frontal scalp or in an oblique fashion.¹⁶ The oblique design, however, may affect the eyebrow position after donor site closure or contraction caused by second intention healing. The presence of scars within the donor site of the forehead should be assessed since it may affect the flap vascular supply.¹⁷

Attempting to completely close the forehead donor site is not advisable. The forehead is approximated as much as possible without tension. However, when significant tension is noted, the

remaining wound should heal by second intention.² Heroic measures such as bilateral forehead rotations or skin grafting only increases morbidity and pain without significant benefits. To facilitate second intention healing without the morbidity of additional procedures, bovine dermal collagen was used in 15 (79%) of our patients, an approach that has not been reported in other studies with PFF. We do not recommend the use of FTSG or STSG for the remaining donor site closure since it can result in a large “patchy scar”. Recently described for the PFF, however, is a delayed FTSG harvested from the pedicle on the stage II.¹⁸

Traditionally, the non-epidermal portion of the pedicle is left exposed. However, postoperative oozing is common as epinephrine from the local anesthetic wears off. Options that reduce bleeding from the pedicle include application of a hemostatic agent (Surgicel®),¹⁹ skin grafts¹² or bovine dermal collagen. The disadvantage of a skin graft is the extra procedure required. Regardless of the method chosen, adequate hemostasis of the pedicle is a critical step.

Defects that extend beyond the nasal subunit are best closed separately (Figure 1). For instance, cheek defects are typically reconstructed with primary closure or cheek advancement flap. The leading border of the cheek flap may be secured to the periosteum of the maxilla to prevent the flap from migrating laterally during the healing process.

Potential complications of the PFF include bleeding, pain, poor scarring, infection, dehiscence, distortion of free margins and flap necrosis.²⁰ In a recent study by Cook,²¹ the rate of complications associated with dermatologic surgeons performing PFF in an outpatient setting under local anesthesia was equal to or lower than published complication rates from other surgical specialties. In this study, despite the higher rate of complications compared to previous studies performed by dermatologic surgeons, complications were minor and treatable. Furthermore, all patients had optimal to excellent functional and aesthetic results.

CONCLUSION

The PFF is a valuable flap in the repair of large and deep nasal defects following Mohs micrographic surgery. Its reliable blood supply, color, and textural qualities and resultant contour warrant strong consideration for its application. Restoring the entire subunit should be considered. Optimal results, however, may be achieved with hemi subunit repair. With good surgical planning, measures for patient comfort, and meticulous technique, the PFF may be safely performed in an outpatient setting and can achieve unique restoration of the nose. ●

REFERENCES

1. Mazzola RF, Marcus S. History of total nasal reconstruction with particular emphasis on the folded forehead flap technique. *Plast Reconstr Surg.* 1983;72(3):408-14.
2. Nguyen TH. Staged interpolation flaps. In: Roher TE, Cook JL, Nguyen TH, Mellete Jr, JR, editors. *Flaps and grafts in dermatologic surgery.* New York: Elsevier, 2007. p. 91-105.
3. Shumrick KA, Smith TL. The anatomic basis for the design of forehead flaps in nasal reconstruction. *Arch Otolaryngol Head Neck Surg.* 1992;118(4):373-9.
4. Burget GC, Menick FJ. The subunit principle in nasal reconstruction. *Plast Reconstr Surg.* 1985;76(2):239-47.
5. Rohrich RJ, Griffin JR, Ansari M, Beran SJ, Potter JK. Nasal reconstruction beyond aesthetic subunits: a 15-year review of 1334 cases. *Plast Reconstr Surg.* 2004;114(6):1405-16; discussion 1417-9.
6. Burget GC. Aesthetic restoration of the nose. *Clin Plast Surg.* 1985;12(3):463-80.
7. Boyd CM, Baker SR, Fader DJ, Wang TS, Johnson TM. The forehead flap for nasal reconstruction. *Arch Dermatol.* 2000;136(11):1365-70.
8. Baker S. Internal lining. In: Baker S, Naficy S, editors. *Principles of nasal reconstruction.* St Louis: Mosby, 2002 p. 31-46.
9. Ratner D, Skouge JW. Surgical pearl: the use of free cartilage grafts in nasal alar reconstruction. *J Am Acad Dermatol.* 1997;36(4):622-4.
10. Byrd DR, Otley CC, Nguyen TH. Alar batten cartilage grafting in nasal reconstruction: functional and cosmetic results. *J Am Acad Dermatol.* 2000;43(5 Pt 1):833-6.
11. Sage RJ, Leach BC, Cook J. Antihelical cartilage grafts for reconstruction of mohs micrographic surgery defects. *Dermatol Surg.* 2012;38(12):1930-7.
12. Menick FJ. A 10-year experience in nasal reconstruction with the three-stage forehead flap. *Plast Reconstr Surg.* 2002;109(6):1839-55; discussion 1856-61.
13. Burget GC, Menick FJ. Nasal support and lining: the marriage of beauty and blood supply. *Plast Reconstr Surg.* 1989;84(2):189-202.
14. Menick FJ. Aesthetic refinements in use of forehead for nasal reconstruction: the paramedian forehead flap. *Clin Plast Surg.* 1990;17(4):607-22.
15. Burget GC, Menick FJ. Nasal reconstruction: seeking a fourth dimension. *Plast Reconstr Surg.* 1986;78(2):145-57.
16. Angobaldo J, Marks M. Refinements in nasal reconstruction: the cross-paramedian forehead flap. *Plast Reconstr Surg.* 2009;123(1):87-93; discussion 94-7.
17. Brodland D. Paramedian forehead flap reconstruction for nasal defects. *Dermatol Surg.* 2005;31(8 Pt 2):1046-52.
18. Kim SK, Park HS, Lee SC. A novel method for closing large donor defects when performing paramedian forehead flaps. *Dermatol Surg.* 2013;39(10):1549-50.
19. Christenson LJ, Otley CC, Roenigk RK. Oxidized regenerated cellulose gauze for hemostasis of a two-stage interpolation flap pedicle. *Dermatol Surg.* 2004;30(12 Pt 2):1593-4.
20. Little SC, Hughley BB, Park SS. Complications with forehead flaps in nasal reconstruction. *Laryngoscope.* 2009;119(6):1093-9.
21. Newlove T, Cook J. Safety of Staged Interpolation Flaps After Mohs Micrographic Surgery in an Outpatient Setting: A Single-Center Experience. *Dermatol Surg.* 2013;39(11): 1671-82.