

## Performing Mohs Micrographic Surgery in a university hospital

### *A experiência da implantação da cirurgia micrográfica de Mohs em um serviço universitário*

#### Authors:

Heliane Sanae Suzuki<sup>1</sup>  
Mauricio Shigueru Sato<sup>2</sup>

<sup>1</sup> Dermatology Resident Physician, Hospital Central da Universidade Federal do Paraná (UFPR) – Curitiba (PR), Brazil

<sup>2</sup> Specialist (accredited by the Brazilian Society of Dermatology); Collaborator Physician, Mohs Surgery Outpatient Clinic, Hospital Central, UFPR.

#### Correspondence:

Dra. Heliane Sanae Suzuki  
Rua General Carneiro, 181 SAM 4  
80060-150 -Curitiba – PR

#### ABSTRACT

**Introdução:** Mohs Micrographic Surgery is a surgical technique that produces the greatest cure rates and the lowest recurrence in the treatment of skin cancer. This article describes the experience of performing micrographic surgery in a university hospital, with the aim of introducing the process and disseminating the technique.

**Keywords:** skin neoplasms; mohs surgery; ambulatory surgical procedures; hospitals, university.

#### RESUMO

**Introdução:** A cirurgia micrográfica de Mohs é a técnica cirúrgica com as melhores taxas de cura e a menor recorrência no tratamento do câncer de pele. Relatamos a experiência da implantação da cirurgia micrográfica em hospital universitário com o objetivo de apresentar o processo e difundir a técnica.

**Palavras-chave:** neoplasias cutâneas; cirurgia de mohs; procedimentos cirúrgicos ambulatoriais; hospitais universitários.

#### INTRODUCTION

Mohs micrographic surgery (MMS) is a surgical technique that presents the best cure rates and the lowest recurrence rates in the treatment of skin cancer – which is the cancer with the highest worldwide prevalence.

The technique is based on the exeresis of the tumor with a very narrow margin and the histological assessment of the lateral and deep margins during the procedure – which distinguishes this procedure from other approaches. The margins are evaluated by freezing the removed tissue and making horizontal sections for analysis. Unlike standard vertical sectioning through sampling,<sup>1-7</sup> MMS allows the histological control of 100% of the surgical margins, and the maximum preservation of healthy skin.<sup>2-4</sup> Given that it ensures free margins during the procedure, it allows better preservation of important anatomical structures, making the reconstruction less complicated and safer and producing in better cosmetic and functional results.<sup>3,5</sup>

MMS was developed at the University of Wisconsin in the 1930s by Frederic Mohs, and was first described in 1941. It was referred to as chemosurgery due to the use of a zinc chloride paste for the in vivo fixation of the tissue, which was painful and lasted for 24 hours. The tumor would then be removed and all margins were examined microscopically. If there was any compromise of the tissue, the surgical margins were widened and

Received on: 20 August 2010

Approved on: 19 February 2012

This study was carried out at the Universidade Federal do Paraná – Curitiba (PR), Brazil.

Conflict of interest: None  
Financial support: None

subjected to a new cycle of fixation with the zinc chloride paste. In 1953, the analysis of margins started to be made in fresco, with less discomfort to patients and equivalent results as evidenced by Tromovitch and Stegman in 1974.<sup>1,4-7</sup>

MMS is mainly recommended for non-melanoma skin cancers such as basal cell carcinomas (BCCs), squamous cell carcinomas, and other uncommon lesions, such as adnexal tumors, dermatofibrosarcoma protuberans, and extramammary Paget's disease. The indication of MMS for melanomas is still controversial.<sup>2,7</sup> Also, it offers the highest cure rates in primary and recurrent tumors.<sup>3,5-7</sup> Despite its many benefits, there are still restrictions related to the duration of the surgery, costs, and the infrastructure needed to perform it.<sup>7</sup> For these reasons, few practices offer this treatment option.

The classical indication criteria – which correspond to cases in which MMS is demonstrably superior to conventional surgery – are the following: topographical areas with a higher risk of recurrence (e.g., the "H" of the face and areas of brachial clefts), lesions larger than 2 cm, tumors with imprecise limits, recurrent tumors, more aggressive histological types of tumors (e.g., sclerodermiform, infiltrative, and micronodular BCC), tumors with perineural invasion, and tumors in areas in which tissue preservation is essential (such as eyelids, nose, hands and feet, and genitals).

This article reports the experience of performing micrographic surgery in a university hospital, which acquired the MMS equipment through a partnership with the Department of Anatomical Pathology. It describes the first 14 patients who underwent MMS at the Dermatology Department of the da Universidade Federal do Paraná, in the Brazilian State of Paraná, between April 2009 and December 2009. The patients were previously screened in the surgical oncology outpatient clinic for the classical indications for MMS. Fifteen lesions were operated on 14 patients, of whom 64% were female. The mean age was 60.4 years. Of all the lesions (all of which measured less than 1.5 cm in diameter), 14 were BCCs (93%) and one was a metastypical carcinoma (7%). Most BCCs were of the "solid" histological type and only one was of the sclerodermiform type.

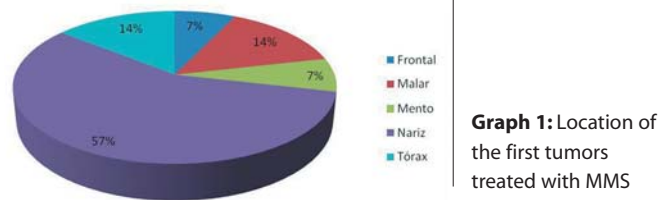
The most common location was the nasal region, followed by the chest, malar, frontal, and mentum areas (Figure 1). One of the neoplasias located in the nose was recurrent. There was a previous history of other skin cancers in 57% of the patients.

The procedure was carried out in only one stage in 60% of cases; the remaining patients required two stages (Figure 2). In some cases it was not possible to analyze the slide until the following day. In those cases, there was no need for further surgical intervention.

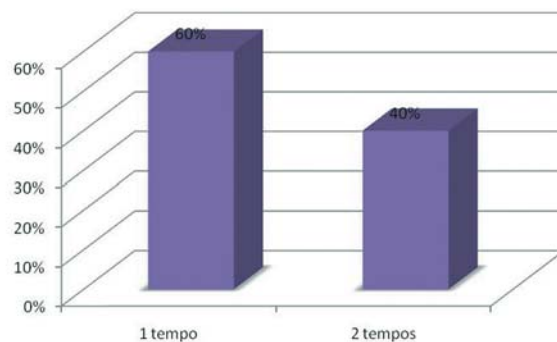
Only one case presented compromised margins, requiring adjuvant therapy with Imiquimod to treat the cancerization field. That female patient presented basal cell nevus syndrome (Gorlin-Goltz Syndrome).

## CONCLUSION

In the authors' experience, the number of micrographic surgeries performed is limited by the restrictions on the use of



**Graph 1:** Location of the first tumors treated with MMS



**Graph 2:** Proportion of surgical stages required in the first MMS performed

the Department of Anatomical Pathology's cryostat (twice a month). In order to provide higher quality care to dermatological patients, and in view of the availability of skilled human resources to perform more MMS procedures, the authors request the creation of a dedicated MMS laboratory in the Dermatology Department. This project was approved by the government in 2011 with a view to performing two procedures weekly. Notwithstanding the initial difficulties of implementing this surgical technique, the Department of Dermatology has the capacity to carry out the project, even if (under some specific conditions) its progression shall occur gradually. ●

## REFERENCES

- Kopke LFF, Gouvêa OS, Bastos JCF. Dez anos de experiência com cirurgia micrográfica pelo método de Munique: relato de 93 casos operados. *An Bras Dermatol.* 2005;80(6):583-90.
- Cumberland L, Dana A, Liegeois N. Mohs micrographic surgery for the management of nonmelanoma skin cancers. *Facial Plast Surg Clin N Am.* 2009;17(3):325-335.
- Cook Joel, Zitelli JA. Mohs micrographic surgery: A cost analysis. *J Am Acad Dermatol.* 1998;39(5 pt 1):698-703.
- Smeets NWJ, Kuijpers DIM, Nelemans P, Ostertag JU, Verhaegh ME, Krekels GA, et al. Mohs' micrographic surgery for treatment of basal cell carcinoma of the face - results of a retrospective study and review of the literature. *Br J Dermatol* 2004; 151(1):141-47.
- Terzian LR, Nogueira VMA, Paschoal FM, Barros JC, Machado-Filho CAS. Cirurgia micrográfica de Mohs para preservação tecidual nas cirurgias oncológicas da face. *Surg Cosmet Dermatol.* 2010; 2(4):257-63.
- Alonso T, Sánchez P, González A, Ingelmo J, Ruiz I, Delgado S, Rodriguez MA. Mohs micrographic surgery: our first 100 patients. *Actas Dermosifiliogr.* 2008;99(4):275-80.
- Lang PG Jr. The role of Mohs' micrographic surgery in the management of skin cancer and perspective on the management of the surgical defect. *Clin Plastic Surg.* 2004;31(1):5-31.