

## Case Report

# Reconstruction of the lower lip using Karapandzic and Gilles flaps after the excision of squamous cell carcinoma

*Reconstrução do lábio inferior com retalhos de Karapandzic e Gilles após excisão de carcinoma espinocelular*

## ABSTRACT

Squamous cell carcinomas located on the lower lip represent 20–30% of all oral cancers, and present good prognosis when diagnosed early. Cervical lymph node metastases occur in 5–20% of cases. The case of a female patient with a nodular-ulcerated infiltrating lesion affecting one-third of the lower lip is described. The examination of lymph nodes yielded normal results. The excision of the lesion was carried out and the labial reconstruction performed using a Karapandzic flap on the right side and a Gilles flap on the left, with a commissuroplasty carried out in a second operation. The procedure produced a cosmetically acceptable result, with good recovery in speech and swallowing. No recurrences or metastases were observed within the years of follow-up.

**Keywords:** carcinoma, squamous cell; lip; surgical flaps.

## RESUMO

Carcinomas de células escamosas do lábio inferior representam 20-30% de todos os cânceres orais, que apresentam bom prognóstico quando diagnosticados precocemente. Metástases em linfonodos cervicais ocorrem em 5-20% dos casos. Relata-se caso de paciente do sexo feminino com lesão nódulo-ulcerada infiltrativa, acometendo um terço do lábio inferior. Os linfonodos analisados foram normais. Foram realizadas excisão da lesão e reconstrução labial utilizando técnica do retalho de Karapandzic à direita e Gilles à esquerda, e comissuroplastia em segundo tempo. Houve resultado aceitável cosmeticamente e boa recuperação na fala e deglutição. Não foram observadas recidivas ou metástases em dois anos de seguimento.

**Palavras-chave:** carcinoma de células escamosas; lábio; retalhos cirúrgicos.

## INTRODUCTION

Squamous cell carcinomas (SCCs) located on the lips account for 20–30% of all oral cancers. A higher frequency is observed in patients over 50, predominantly in men and in patients who are exposed to the sun, tobacco, and alcohol. When diagnosed early, the prognosis is good, with cure rates of around 90% in five years. Nevertheless, cervical lymph node metastases occur in 5–20% of cases.<sup>1</sup> Even defects affecting less than one-third of the upper or lower lip require a carefully executed repair, which takes into account the local anatomy and preserves the sphincter function that is required to chew and speak.<sup>2</sup> Among the reconstruction techniques described for the lower lip, the primary closures most often used are the “Y,” “W,” “M,”

## Authors:

Leticia Arsie Contin<sup>1</sup>  
Mário Marques de Carvalho<sup>2</sup>  
Carlos D. Aparecida S. Machado Filho<sup>3</sup>  
Marcos Eiji Hayashida<sup>4</sup>  
Thais Serrano Ferraz<sup>4</sup>  
Bones Ferreira Gonçalves Jr.<sup>4</sup>

- <sup>1</sup> Dermatologic Surgery Resident Physician, Faculdade de Medicina do ABC (FMABC) – Santo André (SP), Brazil
- <sup>2</sup> Dermatologist Physician; Dermatologic Surgery Preceptor, FMABC
- <sup>3</sup> PhD from the Universidade Federal de São Paulo (UNIFESP) – São Paulo (SP), Brazil; Preceptor, Dermatology Department, FMABC.

## Correspondence:

Leticia Arsie Contin  
Alameda Lorena, 1157 ap 35.  
01244-005 – São Paulo-SP.  
E-mail: lecontin@hotmail.com

Received on: 16 April 2011  
Approved on: 2 April 2012

This study was carried out at the Faculdade de Medicina do ABC (FMABC) – Santo André (SP), Brazil.

Financial support: None  
Conflict of Interest: None

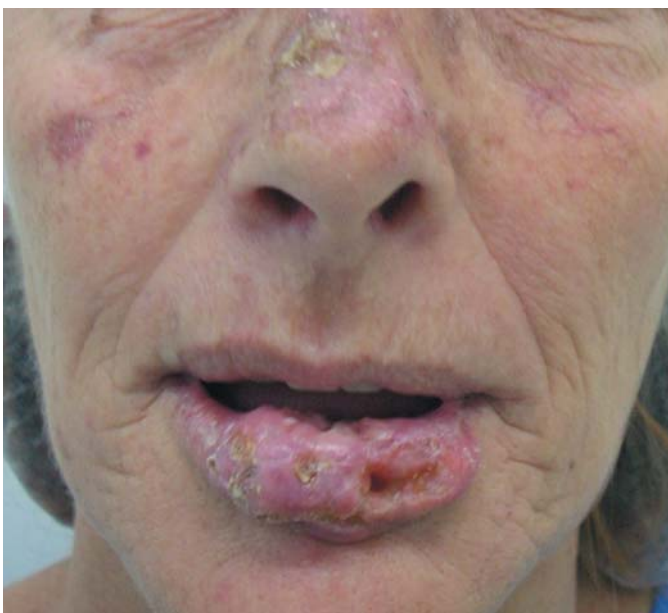or Zplastia for defects affecting less than one-third of the lip. In addition, the Abbé, Karapandzic, Estadler, Gilles Bernard-Burow flaps – or combinations thereof – can deal with more extensive defects.<sup>2,3</sup>

### CASE REPORT

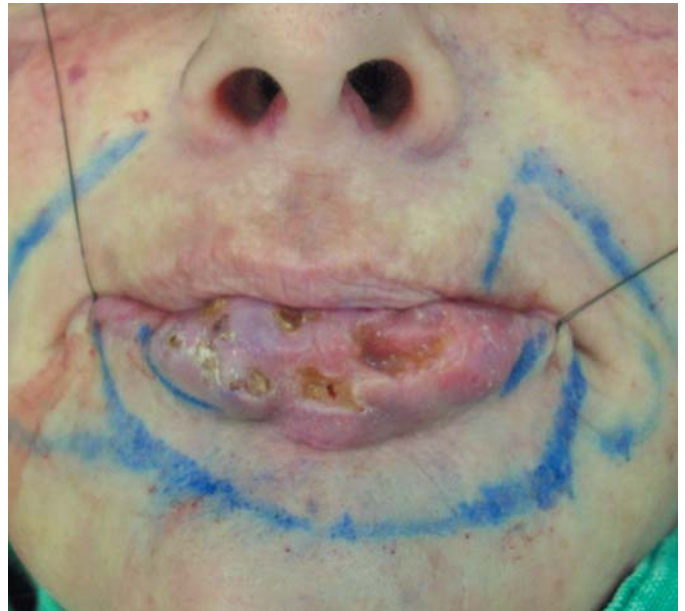A 50-year-old white female patient, who is a smoker (half a pack per day for 27 years) but has no history of constitutional symptoms, alcohol, or illicit drug use, visited the Dermatology outpatient clinic of the Faculdade de Medicina do ABC in São Paulo, Brazil. The patient presented with nodular-ulcerative infiltrative lesions, which at the time of the first visit affected one-third of the lower lip. Cervical chain lymph nodes were impalpable on clinical examination. The histologic examination of the lower lip biopsy presented a moderately undifferentiated SCC. Ultrasounds of the cervical, submandibular, and supra/infraclavicular chain of lymph nodes were carried out, with no abnormalities detected (Figure 1).

The patient also presented a nasal lesion with the same development timeline and histological diagnosis of nodular and micronodular basal cell carcinoma (BCC); the surgery was postponed at the patient's request.

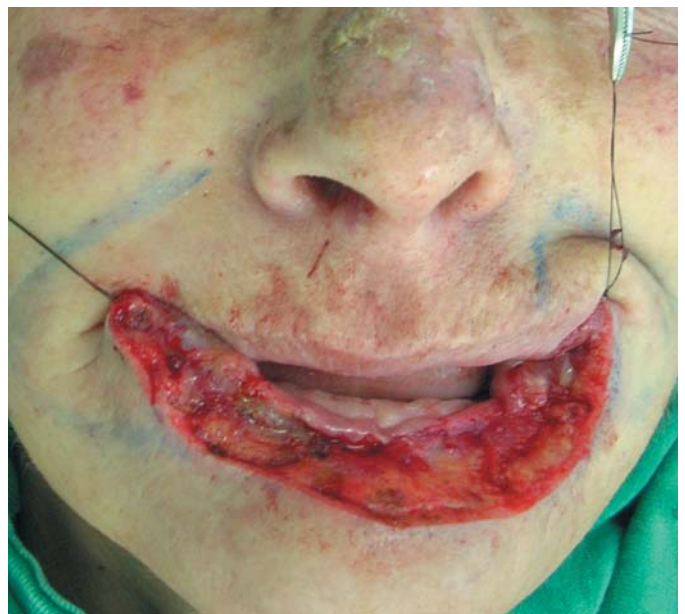The complete exeresis of the tumor was carried out with a 0.6 cm margin, and a lower lip reconstruction using a Karapandzic flap on the right side of the lip was conducted. A Gilles flap was used on the left side of the lip to allow greater mobility (Figures 2–6). The histologic examination of the specimen demonstrated a well-differentiated SCC, ulcerated in the skin of the lower lip; the absence of perineural, angiolymphatic, or vascular blood invasion; and free surgical margins. A review of the flap and a commissuroplasty for the correction of asymmetry on the left side of the lip were carried out during a second surgery (Figure 7).



**Figure 1:** Tumor in the lower lip



**Figure 2:** Schematic drawing showing flaps to be performed



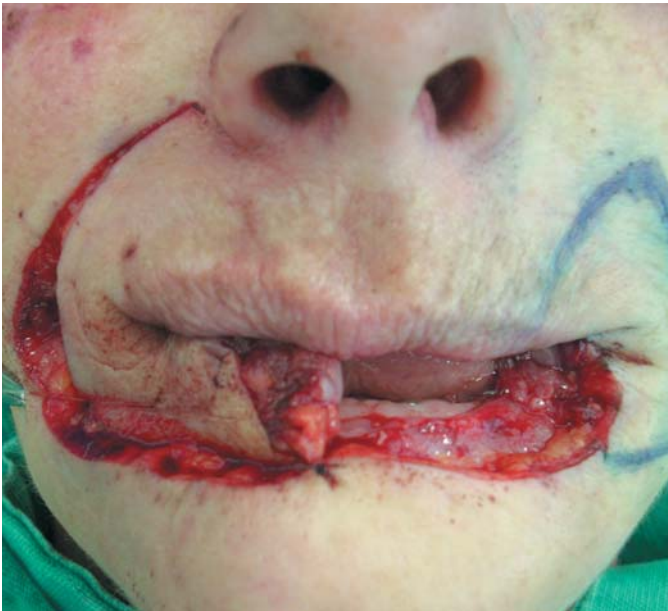**Figure 3:** Tumor excision with 0.5 cm margin

### DISCUSSION

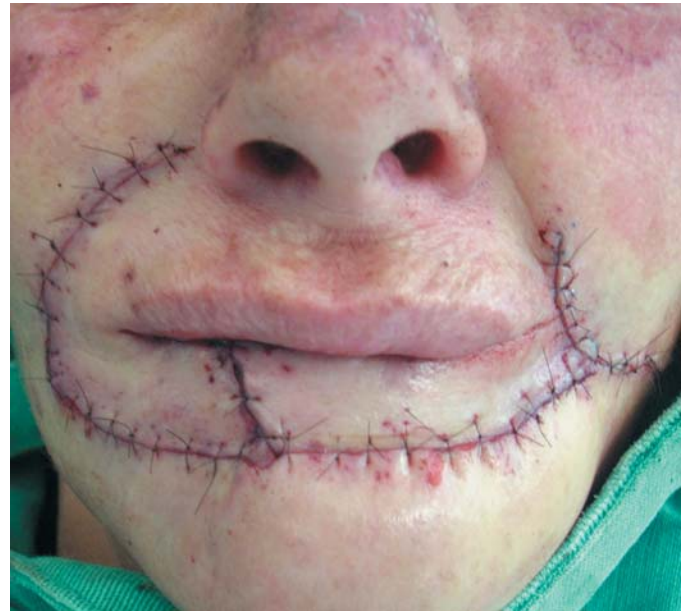The treatment for lip cancers is surgical and involves the complete excision of the tumor with 0.4–0.6 cm safety margins (margins of up to 1 cm can be used in high-risk tumors on the trunk and limbs) or micrographic Mohs surgery.<sup>4</sup>

It also involves clinical and imaging research of the cervical chains. If the lymph nodes are clinically palpable or if an alteration is detected in complementary examinations, puncturing with a thin needle is recommended. In negative cases, re-evaluation or an open biopsy must be considered. In positive cases, regional lymph node dissection is recommended (unilateral or bilateral, depending on the number of metastatic lymph nodes

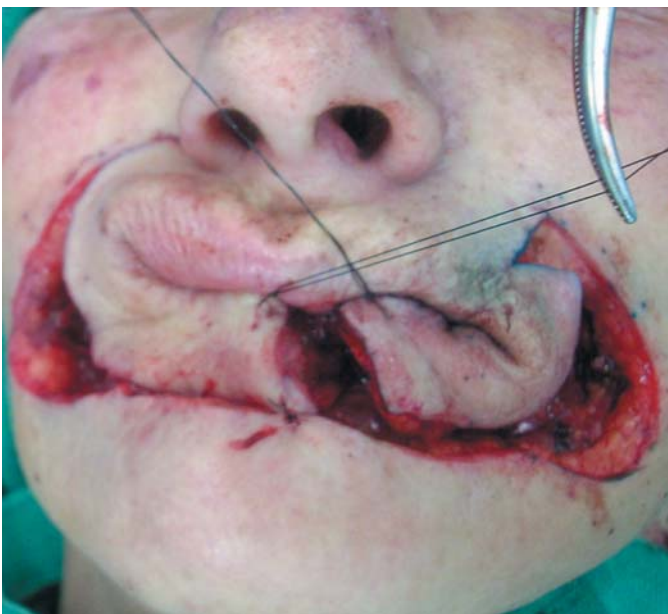



**Figure 4:** Right side Karapandzic flap



**Figure 6:** Appearance in the immediate post-operative period



**Figure 5:** Left side Gilles flap

and their location), combined with adjuvant radiation and chemotherapy, depending on the clinical situation. Although its clinical benefits are not yet sufficiently confirmed, sentinel lymph node research is also recommended in high-risk tumors even if the lymph nodes are not clinically palpable.<sup>4,5</sup> Altinyollar and colleagues advocate the prophylactic cervical resection of cervical lymph nodes even if they are not clinically detectable, due to the high risk of metastasis.<sup>6</sup>

Prophylactic radiation therapy may be considered for tumors with a diameter less than 15 mm located in high-risk areas (e.g., the “H” of the face) and for those with a diameter less than 20 mm located in medium-risk areas (malar and fron-

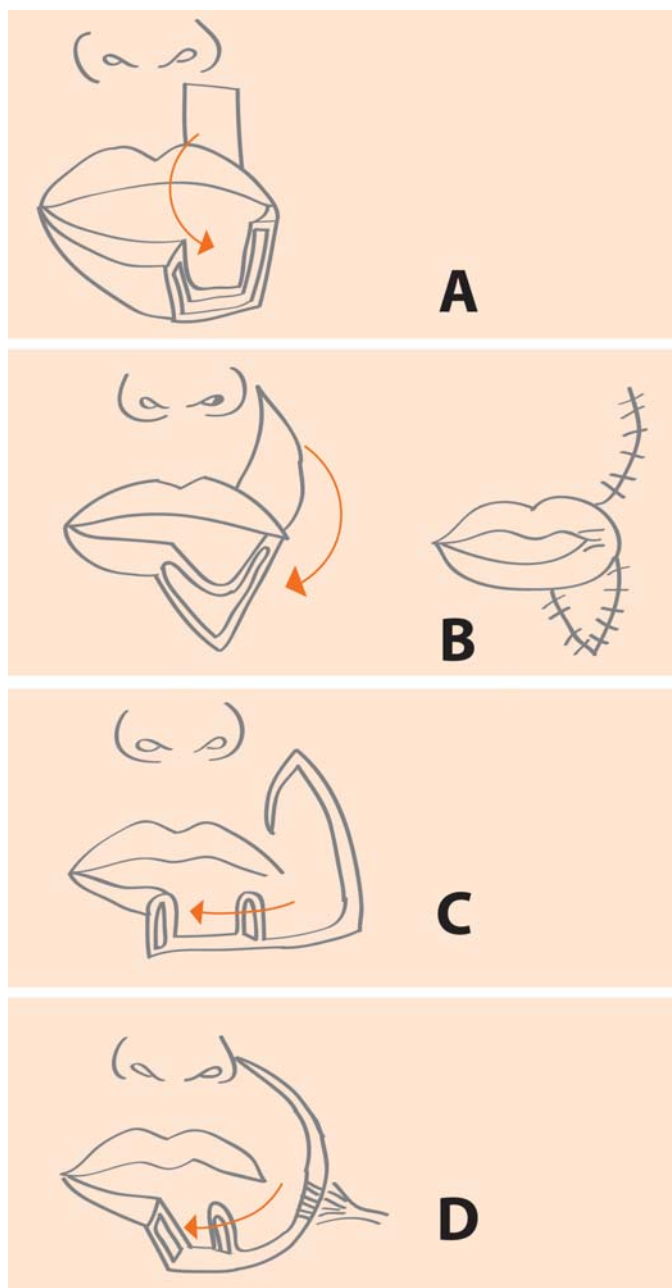
tal regions, scalp, and neck). Isolated radiation therapy is an option for patients at high risk of surgery, usually elderly patients with comorbidities. Adjuvant radiation therapy is considered in cases with positive margins after Mohs surgery or when there is substantial perineural involvement, for patients with head and neck lymph node involvement, and for those who underwent a resection of the lymph nodes after the excision of tumors on the trunk and limbs.<sup>4,6</sup> Chemotherapy can be combined with adjuvant radiation therapy in cases of incomplete lymph node resection or in patients with tumors of extracapsular extension.<sup>4</sup>

The reconstruction of the lower lip is based on the features of the affected region, which can be divided into small (30% or less), medium (30–60% of involvement), or large defects (60%). If only the vermilion area is involved (*in situ* SCC, actinic cheilitis), it can be treated with vermillionectomy followed by primary closure, advancement flaps, and mucosa grafts.<sup>2,3</sup> Small tumors can be excised and the area reconstructed with primary closure using a “V” or “W.” In that option, however, if the tumors are located on the sides of the lip, there is the risk of progression with lateral infiltration.

Medium-sized tumors can be reconstructed with elliptical excisions, edge-to-edge/border-to-border sutures, M-plasty, or flaps.<sup>2</sup>

In patients with defects affecting large areas, removing the vermilion area completely and performing a reconstruction should be considered, in addition to the use of dental prostheses and the feasibility of inserting them during the post-operative period.

The Abbé flap, the correction of a defect in the lower lip using a flap originating from the upper lip, is among the most frequently cited options for reconstruction (Figure 8A). Ideally, the flap is made by connecting the middle and lateral thirds of the upper lip. The flap's height should be similar to that of the receiving area, and the width of the donor area should be half



**Figure 8: A.** Abbé flap: upper lip flap is used to reconstruct defect in the lower lip

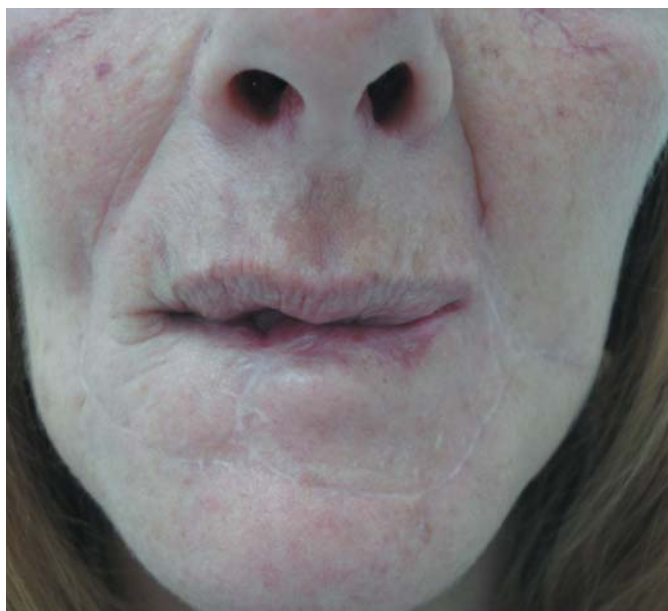**B.** Estlander flap: a triangle from the upper lip is used to correct a defect in the lower lip; commissuroplasty may be required later

**C.** Gilles flap: commissure and lateral projection of the lower lip to cover a lesion in the lower lip; full-thickness flap

**D.** Karapandzic flap: myocutaneous flap; the neurovascular pedicle is untouched

that of the receiving area, in order for the defect to be evenly distributed between the two lips.

For defects affecting the full thickness of the lip, one option is the full thickness Estlander flap, involving the preparation of a triangle in the upper lip, which is transferred to reconstruct the



**Figure 7:** Second month post-operative, left side commissuroplasty

lower lip and the commissure. Commissuroplasty may be required in a second surgery (Figure 8B).<sup>7</sup> The Gilles flap, an extended version of the Estlander flap, is also used to correct such lesions (Figure 8C). It is a full-thickness flap that consists of projecting the lower lip's lateral commissure to cover the lesion located in the lower lip. There may be distortion and shortening of the lower lip's commissure.<sup>1,2,7-9</sup>

Karapandzic modified this technique in order to reconstruct central lower lip defects measuring 3.5-7 cm from which tumors have been removed (Figure 8D). It is a myocutaneous flap that keeps the neurovascular supply untouched in order to preserve the functions of the lip. It can be carried out bilaterally, and there is the possibility of combining it with the reconstruction of the vermillion with a tongue flap.<sup>1,2,9</sup>

The main complications in these reconstructions are functional alterations and microstomia. In the present case, the authors chose to use a Karapandzic flap on the right side and a Gilles flap on the left side, in order to provide more mobility.

Commissuroplasty can be carried out in a second surgery to improve the lip's symmetry, as in the case described. Satisfactory aesthetic and functional results were obtained (Figure 7).

There were no clinical signs of recurrence or metastasis in the two years after surgery; the patient was still enrolled in clinical follow-up at the dermatologic surgery outpatient clinic. Semiannual or annual observation is recommended, especially during the first two years, given that 70-80% of recurrences are observed during that period. Long-term observation must be maintained.<sup>4</sup>

Lesions in the lip are a therapeutic challenge, and even small lesions should be approached carefully due to the risk of metastases and functional alterations following the excision of the tumor. ●

## REFERENCES

1. Hasson O. Squamous Cell Carcinoma of the lower lip. *J Oral Maxillofac Surg.* 2008;66(6):1259-62.
2. Ishii LE, Byrne PJ. Lip reconstruction. *Facial Plast Surg Clin N Am.* 2009;17(3): 445-53.
3. NCCN. Clinical practice Guidelines in Oncology. Basal cell and squamous cell skin cancers. Vol 1, 2010. MS 8.
4. Altinyollar H, Berberoglu U, Çelen O. Lymphatic mapping and sentinel lymph node biopsy in squamous cell carcinoma of the lower lip. *Eur j Surg Oncol.* 2002. 28(1): 72-4.
5. Bucur A, Stefanescu L. Management of patients with squamous cell carcinoma of the lower lip and N0 neck. *J Craniomaxillofac Surg.* 2004;32(1):16-8.
6. Faulhaber J, Gérald C, Goerdts S, Koenen W. Functional and Aesthetic Reconstruction of Full Thickness Defects of the Lower lip after Tumor Resection: Analysis of 59 Cases and Discussion of a Surgical Approach. *Dermatol Surg.* 2010; 36(6): 859-67.
7. Zide BM. Deformities of the Lips and Cheeks. In: McCarthy JG. *Plastic Surgery.* Philadelphia: Saunders Elsevier; 1990. p. 2015-25.
8. Petres J, Rompel R, Robins P. Head and Neck in Dermatologic text book and atlas Surgery. New York: Springer; 1996. p. 277-305.
9. Moreno-Ramirez D, Ferrandiz L, Vasquez-Chinchay F, Camacho FM. Uncompleted Fan Flap for Full-Thickness Lower Lip Defect. *Dermatol Surg.*