

Versatility of the Limberg flap in reconstructions after resection of facial tumors

Versatilidade do Retalho de Limberg nas reconstruções pós-resssecção de tumores em face

ABSTRACT

Introduction: Alexander Limberg created the Limberg flap in 1946 to repair rhomboid defects. The great advantage of using local flaps on the face is the similarity of color and texture of the tissues to the location of the defect to be repaired.

Objective: To evaluate the advantage of using a Limberg flap to reconstruct facial defects created by the resection of tumors.

Methods: Retrospective analysis of 12 cases in which Limberg flaps were used to reconstruct defects resulting from tumor resections in the face.

Results: There were two epitheliosis cases; one developed partial necrosis of the flap, and both patients healed well with conservative treatment and daily changes of dressing. In one of the cases, the patient developed a post-operative hematoma requiring surgical drainage and flap repositioning, which resolved well, with only minor scar retraction.

Discussion: The design of the flap requires precision. The main difficulty is the need to draw equal sides with accurate angles of 60 and 120 degrees.

Conclusions: Limberg flaps are versatile and can produce good results in several areas of the face.

Keywords: face; surgical flap; skin neoplasm; reconstruction

RESUMO

Introdução: O retalho de Limberg foi criado em 1946 por Alexander Limberg, para cobertura de defeitos rombóides. A grande vantagem da utilização de retalhos locais na face é a similaridade de cor e textura dos tecidos vizinhos com o local do defeito a ser reparado.

Objetivo: Avaliar a vantagem do retalho de Limberg na face para reconstrução de defeitos gerados após ressecção tumoral.

Métodos: Análise retrospectiva de 12 casos de retalho de Limberg realizados para reconstrução de defeitos gerados após ressecção de tumores na face, no primeiro semestre de 2011, no Serviço de Cirurgia Plástica do HSPE-SP.

Resultados: Houve 2 casos de epiteliólise, um deles evoluindo com necrose parcial do retalho, sendo que ambos os casos evoluíram bem com tratamento conservador e troca de curativos diários. Em 1 caso a paciente evoluiu com hematoma no pós-operatório necessitando drenagem cirúrgica e reposicionamento do retalho, evoluindo bem, com apenas pequena retração cicatricial.

Discussão: O desenho do retalho requer precisão, sendo a maior dificuldade a necessidade de desenhar lados iguais com ângulos precisos de 60 e 120 graus.

Conclusões: O retalho de Limberg apresentou bons resultados nos pacientes operados, e devido à sua versatilidade estes resultados podem ser reproduzíveis em várias regiões da face.

Palavras-chave: face; retalhos cirúrgicos; neplasias cutâneas; reconstrução

Authors:

Tiago Sarmento Simão¹
Felipe Rodrigues Máximo¹
Rafael Ribeiro Pinheiro¹
Fellipe Emanuel Amorim Santos Barbosa¹
Débora Nassif Pitol¹
Leão Faiwchow²

¹ General Surgeon; Plastic Surgery Resident Physician, Hospital do Servidor Público Estadual de São Paulo – São Paulo (SP), Brazil

² Plastic Surgeon; Head of Plastic Surgery and Burns Department, Hospital do Servidor Público Estadual de São Paulo

Correspondence:

Dr. Tiago Sarmento Simão
R. Capitão Macedo, 171
04021-020 – São Paulo – SP
E-mail: tiagossimao@yahoo.com.br

Received on: 17 March 2012

Approved on: 9 May 2012

This study was carried out at the Plastic Surgery and Burns Department of the Hospital do Servidor Público Estadual de São Paulo – São Paulo (SP), Brazil.

Financial support: None
Conflict of interest: None

INTRODUCTION

Alexander Limberg created the Limberg flap in 1946¹ to repair rhomboid defects. The great advantage of using local (single, double or triple^{2,3}) flaps on the face is that the similarity of color and texture of the tissues to the location of the defect to be repaired produces better aesthetic outcomes. There is also a lower risk of contracture compared to grafts. However, increased scarring and tissue mobilization are drawbacks.^{4,5} Limberg flaps are mainly used in facial reconstruction, particularly for medium-sized defects when primary repair with sutures is not possible.^{6,7}

OBJECTIVE

To evaluate the versatility and final aesthetic result of using Limberg flaps in patients who underwent reconstruction of defects resulting from the resection of facial tumors.

METHODS

This study was a retrospective analysis of 12 cases in which Limberg flaps were used for reconstructing defects resulting from the resection of facial tumors. It was conducted in the first half of 2011 at the Plastic Surgery Department of the São Paulo State Hospital do Servidor Público Estadual in Brazil. All patients signed an informed consent form regarding the execution of the procedure and the publication of photographs in scientific journals.

After a pre-operative clinical examination and laboratory tests were carried out, all patients underwent resection of facial tumors. All lesions were resected with a safety margin that protected the muscular plane, and specimens were sent for frozen biopsy.

FLAP PREPARATION

The Limberg flap is prepared from the border of a rhomboid defect with equal sides: 60° angles in the extremities of its longer axis (AC) and 120° angles in the extremities of its shorter axis (BD); (BD = AB = BC = CD = AD). (Figure 1).^{1,2,7}

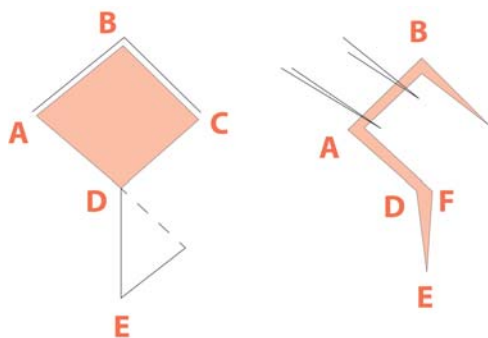


Figure 1: Preparation of the Limberg flap

The Limberg flap (CDEF) is formed from the border of the defect by extending its shorter axis up until point E, so that point D is equidistant from points B and E (BD = DE). An incision parallel to side DC or side AD, with a length similar to that of the other sides of the defect, is carried out from point E, forming a 60° angle with side DE.

ter axis (BD); (BD = AB = BC = CD = AD). (Figure 1).^{1,2,7}

The Limberg flap (CDEF) is formed at the edge of the defect by extending the shorter axis (BD) towards point E, by a distance similar to that of BD (BD = DE). An incision with a length similar to that of the other sides of the defect is carried out from point E, parallel to side DC of the defect, forming a 60° angle with side DE.^{1,2,7}

The closure is completed by transposing the flap towards the defect, using a 60° rotation, approximating points D and F.

OPERATIVE TECHNIQUE

1. Patient lies down with head slightly elevated.
2. Preliminary drawing of the flap with marking pen.
3. Antisepsis with 2% chlorhexidine alcoholic solution.
4. In the absence of contraindication, infiltration anesthesia with lidocaine and epinephrine (1:200,000 IU).
5. Resection with safety margins up until the deep plane, followed by rigorous electrocautery-based hemostasis.
6. Material sent for frozen biopsy.
7. Preparation and positioning of the flap towards the defect.
8. Skin suture carried out with nylon 5.0.
9. Sterile dressing applied.

RESULTS

Patients were aged 60–87 years (mean 71.8), with a predominance of men (8 men and 4 women). The size of the defect generated by resection ranged from 1.2–2.6 cm (average 1.70 cm). The primary location of the lesions was in the right zygomatic region, and the most frequently found histopathological diagnosis was basal cell carcinoma (Table 1). All patients had free resection margins and there were no recurrences within 6 months.

There were 2 epitheliolysis cases, one of which involved the partial necrosis of the flap. Both patients healed with conservative treatment and daily changes of dressings (Table 2). One patient developed a post-operative hematoma that required surgical drainage and the repositioning of the flap, which resulted satisfactorily, with only minor scar retraction.

DISCUSSION

The Limberg flap has great versatility and good applicability in the face, especially for the correction of medium-sized defects (1.5–3.0 cm). The technique produces good aesthetic results, especially when scars are positioned at the junction of the aesthetic units of the face. The preparation of the Limberg flap is straightforward to perform, does not require the major mobilization of tissues, and presents few complications. The design of the flap must be carried out precisely; the main challenge is drawing equal sides with accurate angles of 60° and 120°. Correctly marking the angles and providing adequate intra-operative hemostasis are instrumental in reducing the rate of complications.

Table 1: Characteristics of patients and lesions

| Patient | Sex | Age (years) | Defect (cm) | Pathology | Location |
|---------|-----|-------------|-------------|-----------|------------------|
| 1 | F | 87 | 1.8 | BCC | Right Zygomatic |
| 2 | M | 65 | 1.6 | BCC | Left Malar |
| 3 | F | 60 | 1.9 | BCC | Left Cheek |
| 4 | M | 80 | 2.0 | SCC | Right Zygomatic |
| 5 | M | 73 | 1.5 | BCC | Right Zygomatic |
| 6 | F | 76 | 2.6 | BCC | Right Malar |
| 7 | M | 64 | 1.2 | BCC | Left alar groove |
| 8 | M | 73 | 1.7 | BCC | Right Frontal |
| 9 | F | 62 | 1.8 | SCC | Left Zygomatic |
| 10 | M | 83 | 1.5 | BCC | Right Malar |
| 11 | M | 68 | 1.3 | SCC | Left Malar |
| 12 | M | 71 | 1.6 | BCC | Right Zygomatic |

BCC = basal cell carcinoma; SCC = squamous cell carcinoma

Table 2: Complications

| | Complications | Number of Cases |
|---|------------------|-----------------|
| 1 | Epitheliolysis | 2 |
| 2 | Infection | 0 |
| 3 | Partial Necrosis | 1 |
| 4 | Total Necrosis | 0 |
| 5 | Hematoma | 1 |

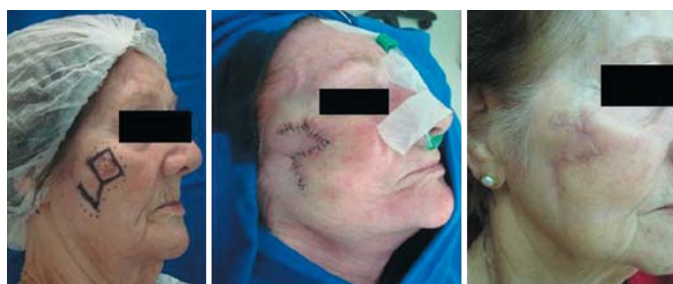

Figure 2: Pre-operative, immediate post-operative, and 30 days post-operative.

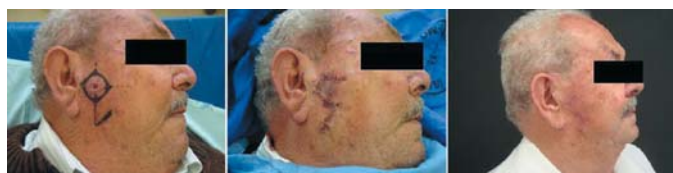

Figure 3: Pre-operative, immediate post-operative, and 30 days post-operative.

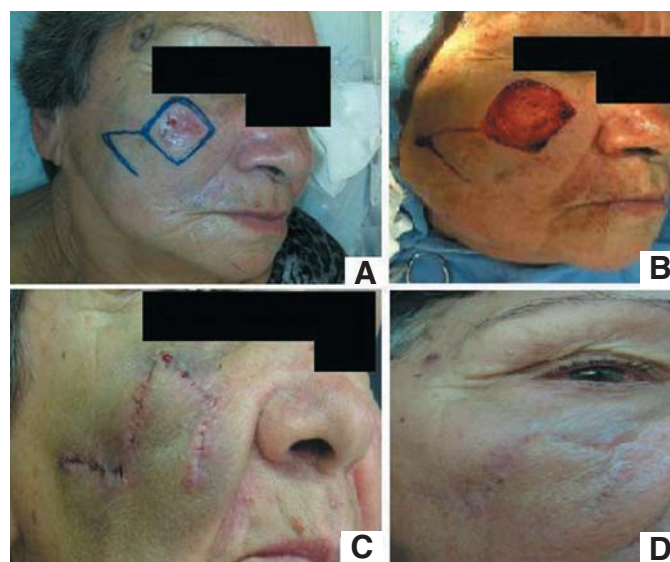

Figure 4: A: Surgical marking; B: Defect area after resection; C: 15 days post-operative after drainage of hematoma; D: Satisfactory appearance after 30 days.

CONCLUSION

The Limberg flap demonstrated good results. The technique's versatility, when combined with good pre-operative planning, precise marking and careful handling of the flap during the surgical procedure, allows such results to be reproduced in several areas of the face. ●

REFERENCES

1. Limberg AA. Mathematical Principles of Local Plastic Procedures on the Surface of the Human Body. Leningrad: Medgis, 1946.
2. Jovanovic MD, Colic MM. Design of the Limberg Flap by a Specially Designed Ruler: A Personal Approach. *Plast Reconstr Surg.* 2004; 113(2):653-58.
3. Borges AF. The rhombic flap. *Plast Reconstr Surg.* 1981; 67(4):458-66.
4. Schmid MH, Meuli-Simmen C, Hafner J. Repair of cutaneous defects after skin cancer surgery. *Recent Results Cancer Res.* 2002; 160:225-33.
5. Becker FF. Local tissue flaps in reconstructive facial plastic surgery. *Clin Plast Surg.* 1995; 22(1):79-89.
6. Jun-Hui L, Xin X, Tian-Xiang O, Ping L, Jie X, En-Tan G. Subcutaneous Pedicle Limberg Flap for Facial Reconstruction. *Dermatol Surg.* 2005; 31(8 pt 1):949-52.
7. Lister GD, Gibson T. Closure of rhomboid skin defects: The flaps of Limberg and Duforentel. *Br J Plast Surg.* 1972; 25(3): 300-14.