

Untouched Strip: a technique to increase the number of follicular units in hair transplants while preserving an untouched area for future surgery

Untouched Strip: técnica para aumentar o número de unidades foliculares em transplante capilar preservando área intocada para futura cirurgia

ABSTRACT

In hair transplants, the donor area can supply only a limited number of follicular units in each procedure. In the treatment of more advanced degrees of baldness, removing both a scalp strip and follicular units, one by one, is an option that allows more units to be harvested in a single session, thus providing a better density and coverage of the bald area. This article describes a technique called Untouched Strip, which, in addition to increasing the number of follicular units with the combined procedure, preserves the donor area for a possible future transplant.

Keywords: hair; transplantation; alopecia.

RESUMO

A área doadora em um transplante capilar pode fornecer quantidade limitada de unidades foliculares em cada procedimento. No tratamento de graus mais avançados de calvície, o uso combinado da retirada de uma faixa de couro cabeludo e de unidades uma a uma é opção para expandir o número de unidades obtidas em sessão única, proporcionando assim melhores densidade e cobertura da área calva. Os autores apresentam a técnica denominada untouched strip (faixa intocada) que, além de ampliar o número de unidades com o procedimento combinado, preserva a área doadora para possível futuro transplante.

Palavras-chave: cabelo; transplante; alopecia.

INTRODUCTION

Modern hair transplants provide excellent, natural-looking results. They rely on the principle that hair harvested from the posterior and lateral areas of the head (donor areas) is more resistant, and maintains that characteristic when transplanted to another region.¹ In the classic technique (CT), a strip of scalp is removed from the donor area and subdivided into follicular units (FUs) that contain one to four hairs each.¹ The follicular unit extraction technique (FUE) is an alternative to the CT² that prevents the formation of a linear scar in the donor area. In FUE, follicular units are removed one by one using punches with a diameter of approximately one millimeter.² As FUE is done manually and are much more labor intensive than the CT, fewer FUs are obtained during a single surgery.³

In more advanced cases of baldness, such as in Norwood grades V-VII, a second or even a third surgical procedure is usually required to achieve good density in an extensive area (Figure 1). Even in surgeries with large numbers of FUs, such as in mega and giga sessions, patients usually need further hair density.^{4,5}

New techniques

Authors:

Márcio Rocha Crisóstomo¹
Marília Gabriela R. Crisóstomo²
Denize Campos Cavalcanti Tomaz³
Manoela C. C. Crisóstomo⁴

- ¹ Masters in Surgery, Universidade Federal do Ceará – Fortaleza (CE), Brazil
- ² Dermatology Post-graduate Degree Candidate, Centro de Dermatologia Dona Libânia –Fortaleza (CE), Brazil
- ³ Dermatology Post-graduate Degree Candidate, Instituto Superior de Medicina – São Paulo (SP), Brazil
- ⁴ Post-graduate Degree, Dermatology, Instituto de Dermatologia Prof. Rubem David Azulay – Rio de Janeiro (RJ), Brazil

Correspondence:

Marcio Crisóstomo
Ed. Harmony Medical Center
Av. Dom Luis, 1233, 21º andar - Meireles
Cep: 60160-230 Fortaleza (CE) - Brazil
Fone/fax: (85) 3267.6804
e-mail: marcio@implantecapilar.med.br

Received on: 7 November 2011
Approved on: 10 December 2011

This study was carried out at the Centro de Transplante Capilar Márcio Crisóstomo – Fortaleza (CE), Brazil.

Financial support: None
Conflicts of interest: None

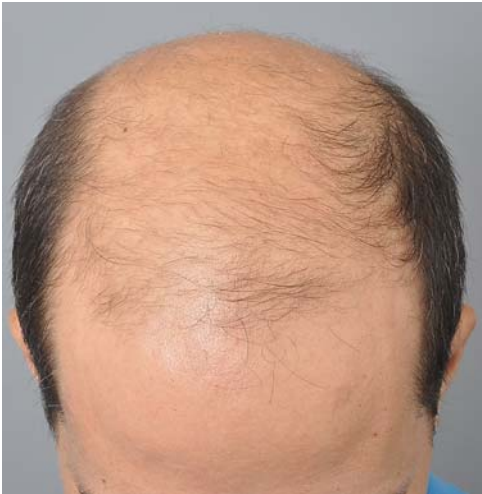


Figure 1 - Advanced baldness (Norwood grade VI) that requires more than one surgery

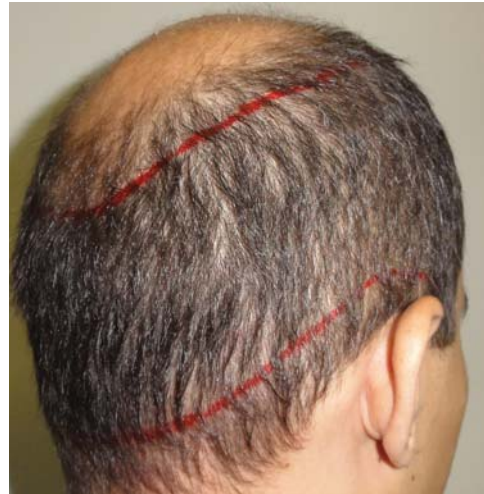

Figure 3 - Determination of the Safe Donor Area, the hairs of which will not fall out over the years

In order to increase the number of transplanted FUs, especially in large bald areas or in cases with unfavorable donor areas, both techniques (CT and FUE) can be combined in a single surgery.⁶ In such cases, the area where FUE is performed is left with a follicular density that is 20–40% lower and small puncture scars, which add local fibrosis and might change the natural anatomy of the hair growth (Figure 2). These factors interfere with the preparation of units in this area in future transplantations, either using CT or FUE.⁷

This paper describes a new standard for the combination of CT and FUE, which allows more FUs to be obtained in a single procedure, preserves an untouched strip in the donor area for a possible second transplant, and maintains a natural appearance.

SURGICAL TECHNIQUE: the untouched strip

The Safe Donor Area – the hairs of which will not fall out with the progression of baldness⁸ – is marked while the hair is a normal length. This is the patient’s potential donor area (Figure 3). Once that area is determined, the hair in the donor area is

shaved to allow the implementation of the FUE. The strip where the CT will be performed is then marked in the Safe Donor Area; immediately below, an area of 1.5 cm is also marked – the area where the FUE will not be performed. This area is called the “untouched strip” (Figure 4). The authors perform the procedure using intravenous sedation and local injection (donor and recipient areas) with 0.2% lidocaine solution combined with 0.1% ropivacaine and 1:200,000 adrenaline.

Next, the range marked for CT is excised in the supragaleal plane and sutured on two levels: deeply with separated absorbable Monocryl® 3.0 sutures, and superficially with continuous Mononylon® 5.0 sutures. It is important to assess the skin’s local elasticity to ensure the closure can be made without tension or the necessity of detachment.

Subsequently, FUE is carried out with 0.9 or 1 mm punches in the Safe Donor Area, above the CT’s suture and below the untouched strip⁹ (Figure 5). The implantation of the FUs in the bald area is made according to the surgeon's preference.

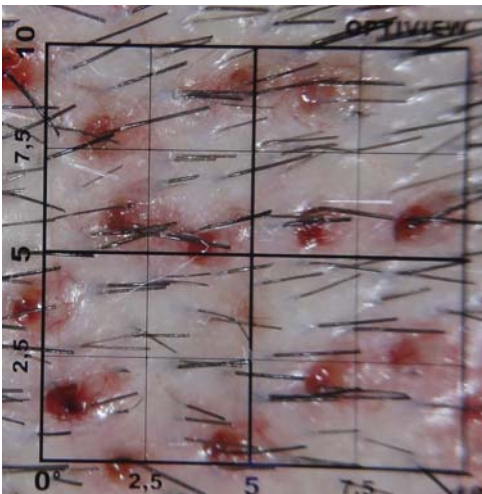


Figure 2 - 1 cm² detail after the extraction of follicular units, which will reduce local density and cause only small puncture scars

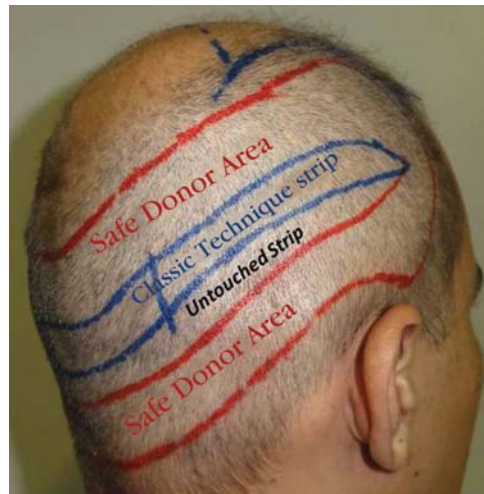


Figure 4 - Marking the band for the classic technique, the untouched strip and the area for extraction of follicular units, in the Safe Donor Area

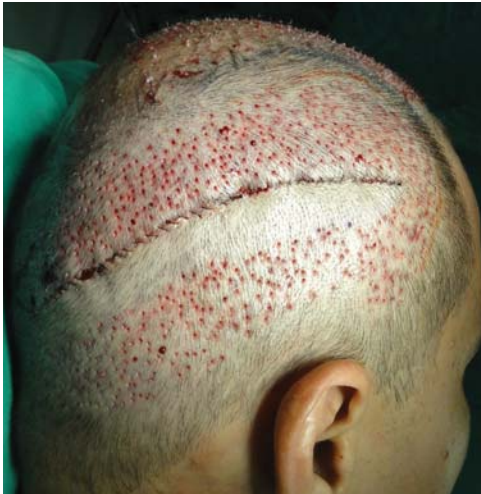

Figure 5 - Extraction of follicular units above the classic technique's suture and below the untouched strip performed in the Safe Donor Area

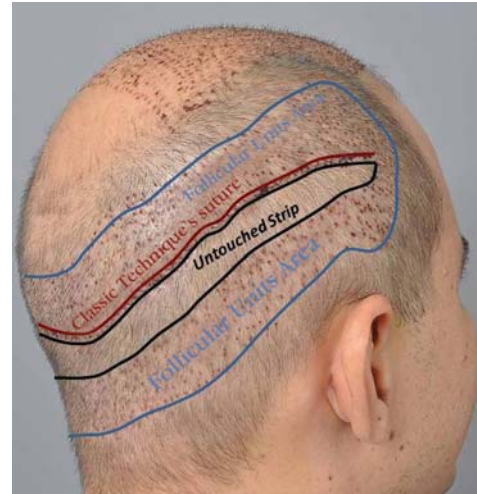


Figure 7 - Schematic drawing of the untouched strip technique over the donor area on the fourth day after the procedure

DISCUSSION

The principle behind the untouched strip is to avoid harming an important area that could possibly be used in future procedures. This approach will preserve the normal follicular density of the area and prevent fibrosis caused by FUE scars^{7,9} (Figure 6). The authors use the FUE and CT combination in patients with advanced levels of baldness (Norwood grades V – VII) and/or in patients with low density or low elasticity in the donor areas.⁶ Great caution should be used to perform the FUE only in the Safe Donor Area described by Unger,⁸ in order to prevent the extracted and transplanted FUs from being lost over the patient's life. In order to avoid this long-term inconvenience, the author recommends the procedure only if the following three criteria are met: (1) careful analysis of family history, verifying the likelihood of progression into a Norwood grade VII, (2) aged older than 40 – even though baldness may increase, only 16% of male patients present Norwood grade VII baldness at 80 – and, more importantly, (3) presence of a well-established degree of baldness, especially in the vertex – usually Norwood grade V and VI, with some grade VII cases. Exception

indications must be studied with great caution. When determining the Safe Donor Area, there must be no underestimation of the donor area's true potential.

In more advanced baldness, a second procedure is necessary even when using the combined technique. In such cases, the untouched strip method is used to avoid decreasing the FU density in the donor area and to prevent fibrosis, which can compromise the second procedure.⁷ The untouched strip can be marked above or below the suture, however the authors suggest marking it below the suture (Figure 7), because the area above usually has better productivity for FUE.

The second procedure is carried out 10–12 months later – to give the donor area time to recover its elasticity. The surgeon will perform another FUE session or, more frequently, CT – with or without excising the previous scar. The technique used in this second procedure is at the surgeon's discretion, after discussion with the patient. In the untouched strip, the key point is to preserve its natural features for any later procedures. The authors' preference is for another harvest, similar to that obtained by CT in the first surgery⁹ (Figures 5, 6 and 7).

The authors prefer performing an FUE after the removal and closure of the CT strip and after the implantation of the FUs obtained in this step, since the FUs obtained using FUE are generally thinner and thus more susceptible to ischemia and reperfusion.¹⁰ Performing the FUE at the end of the procedure allows a reduction in the time the FUs are out of the body.⁹

One of the advantages of the combined procedure is the possibility of decreased tension on the wound closure after completion of the FUE, which leads to a better quality scar. Nevertheless, the main benefit is the increase in the number of FUs transplanted in a single surgical procedure. Tsilosani reported an increase of 14–42% (average 29.5%) with the combined technique.⁶ The increase is slightly lower when using the untouched strip approach, as FUE is not performed in the preserved area. Nonetheless, the benefits of the absence of scar tissue, the presence of normal (or near normal) follicular density, and the

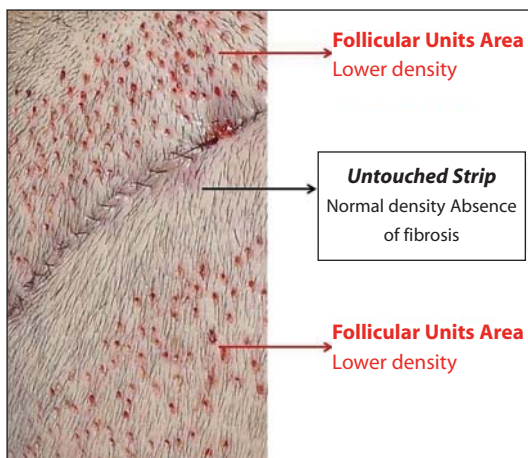


Figure 6 - Detail showing the decrease in the density of follicular units, preserving normal density in the untouched strip

absence of distortion in the anatomy of the follicles in that area make possible future procedures more successful.⁹

The combined use of CT and FUE can expand the number of FUs transplanted in a single session, thus providing better coverage and density in the first procedure in patients with an advanced degree of hair loss and/or with a suboptimal donor area. The technical standardization of the untouched strip protects the donor area, which will not be damaged by the FUE scars or a decrease in the follicular density in this region, in case future procedures are required. ●

REFERÊNCIAS

1. Uebel CO. Micrografts and minigrafts: a new approach for baldness surgery. *Ann Plast Surg.* 1991; 27(5):476-87.
2. Rassman WR, Bernstein RM, McClellan R, Jones R, Worton E, Uyttendaele H. Follicular unit extraction: minimally invasive surgery for hair transplantation. *Dermatol Surg.* 2002; 28(8):720-28.
3. Dua A, Dua K. Follicular Unit Extraction Hair Transplant. *J Cutan Aesth Surg.* 2010; 3(2):76-81.
4. Crisóstomo MR. Gigasessions - Larger Sessions for Baldness Grades IV to VI. Presented at the XIII International Congress of Italian Society for Hair Restoration; 2010 May 20-22; Capri, Italy.
5. Wong J. Preoperative Care for Super Mega-Sessions. In: Pathomvanich D, Imagawa K. *Hair Restoration Surgery in Asians.* Springer; 2010. p.81-2.
6. Tsilosani A. Expanding graft numbers combining strip and FUE in the same session: effect on linear wound closure forces. *Hair Transplant Forum Int´l.* 2010; 20(4):121-23.
7. Bernstein RM, Rassman WR, Anderson KW. FUE Megasessions - Evolution of a Technique. *Hair Transplant Forum Int´l.* 2004; 14(3):97-99.
8. Unger WP, Cole J. Donor Harvesting. In: Unger WP, Shapiro R. *Hair Transplantation.* 4th Ed. New York: Marcel Dekker; 2004. p. 301-48.
9. Crisóstomo, MR. Untouched Strip: Técnica para aumentar a área doadora potencial em um transplante capilar. Apresentado no XVII Encontro da Associação dos Ex-Alunos do Prof. Pitanguy; 2011 Outubro 24-26; Rio de Janeiro, Brasil.
10. Crisóstomo MR, Guimarães SB, de Vasconcelos PR, Crisóstomo MG, Benevides AN. Oxidative stress in follicular units during hair transplantation surgery. *Aesthetic Plast Surg.* 2011; 35(1):19-23.