

# Efficacy of lycopene, beta-carotene and Lactobacillus johnsonii in the maintenance treatment of melasma during the summer

*Avaliação da eficácia do licopeno, beta-caroteno e Lactobacillus johnsonii no tratamento de manutenção do melasma durante o verão: um estudo comparativo*

## ABSTRACT

**Introduction:** Melasma, a very frequent acquired hypermelanosis can be treated topically, however some studies have shown that oral antioxidants could reduce the deleterious effects of ultraviolet radiation on the skin.

**Objective:** To evaluate the effects of oral antioxidants and UVA/UVB sunscreen on the development of melasma during the summer months in Rio de Janeiro (RJ), Brazil – a period when the condition recurs more frequently.

**Methods:** Patients (n = 68) with melasma were randomized to receive one capsule/day of the nutri-concentrate (containing lycopene, beta-carotene and Lactobacillus johnsonii) and apply sunscreen every 3 hours (Group A) or sunscreen only (Group B). The patients were photographed and evaluated according to the Taylor Hyperpigmentation Scale and the Melasma Area Severity Index.

**Results:** The study was conducted from December 2010 to March 2011. Group A presented reductions in melasma of 8.5% on the Taylor scale and 19.5% on the Melasma Area Severity Index ( $p < 0.001$ ). In Group B, the melasma worsened on the Taylor scale and improved 4.6% on the Index. **Conclusions:** The use of a nutri-concentrate containing beta-carotene, lycopene and Lactobacillus johnsonii combined with an SPF 60 sunscreen was an effective treatment for melasma during the summer. The treatment had a statistically significant reduction according to the Melasma Area Severity Index.

**Keywords:** melanosis; carotenoids; lactobacillus; clinical protocols.

## RESUMO

**Introdução:** O melasma, hipermelanose adquirida bastante freqüente, pode ser tratado com medicamentos tópicos, porém, alguns estudos têm demonstrado que os antioxidantes orais poderiam diminuir os efeitos deletérios da radiação ultravioleta sobre a pele.

**Objetivo:** Avaliar o resultado da evolução do melasma com o emprego de antioxidantes orais e fotoprotetor anti-UVA/UVB durante os meses do verão no Rio de Janeiro - (RJ), Brasil – época em que a doença recidiva com mais freqüência.

**Métodos:** Foi realizado um estudo com 68 pacientes com melasma que concordaram em substituir o tratamento anterior pelo proposto. Foram divididas em 2 grupos aleatoriamente: o grupo A fez uso de 1 cápsula/dia do nutricaoconcentrado, além do fotoprotetor 3/3 horas; o grupo B fez uso apenas do fotoprotetor. Foram fotografadas e avaliadas com base da Escala de Hiperpigmentação de Taylor e no MASI, e os dados submetidos à análise estatística. **Resultados:** O estudo teve início em dezembro/2010 e término em março/2011. O grupo A apresentou redução de 8,5% do melasma pela escala de Taylor e de 19,5% pelo MASI ( $p < 0,001$ ). No grupo B, houve piora do melasma em relação à Escala de Taylor e melhora de 4,6% pelo MASI.

**Conclusões:** O uso de um nutricaoconcentrado contendo beta-caroteno, licopeno e Lactobacillus johnsonii associado à FPS 60 foi eficaz como tratamento do melasma durante o verão, com significância estatística em relação à redução do Índice de Gravidade e Área do Melasma.

**Palavras-chave:** melanose; carotenóides; lactobacillus; protocolos clínicos.

## Original Article

### Authors:

Fabiana Braga França Wanick<sup>1</sup>  
Beatrix Sabóia Zink<sup>2</sup>  
Raquel Ferreira Lopes<sup>3</sup>

- <sup>1</sup> Preceptor, Medical Residency Program and Coordinator, Cosmetic Dermatology Outpatient Clinic, Hospital Federal de Bonsucesso (HFB) – Rio de Janeiro (RJ), Brazil
- <sup>2</sup> Dermatologist Physician and Preceptor, Medical Residency Program in Dermatology, Hospital Federal de Bonsucesso
- <sup>3</sup> Resident Physician in Dermatology, Hospital Federal de Bonsucesso

### Correspondence:

Fabiana Braga França Wanick  
Rua Cel. Moreira Cesar, 229/1505  
Icaraí - Niterói  
Cep: 24230-051 – Rio de Janeiro – RJ – Brazil

Received on: 8 November 2011  
Approved on: 10 December 2011

This study was carried out at the Cosmetic Dermatology Outpatient Clinic of the Hospital Federal de Bonsucesso

Financial support: Medication provided by La Roche Posay (Brazil) and INNÉOV (France).  
Conflicts of interest: None

## INTRODUCTION

Melasma is an acquired hypermelanosis that occurs more frequently in women and is characterized by brownish stains located mainly on the face. It has a multifactorial pathogenesis and can be influenced by genetic predisposition, exposure to ultraviolet radiation, pregnancy, hormone therapy and phototoxic drugs.<sup>1</sup> Melasma can be classified according to the affected area or the depth of deposition of melanin.

Melasma can also be classified according to its topography, and can be extra-facial or facial; the latter category is subdivided into centrofacial, malar and mandibular. Of those subtypes, the most common is centrofacial, which consists of stains on the cheeks, nose, upper lip, chin and forehead regions.<sup>1,2</sup>

In order to assess the location of the pigment, the affected skin can be analyzed through histopathological examination, Wood light and dermoscopy.<sup>3</sup> Through histopathology it is possible to observe the distribution of melanic pigment in the following regions: basal and/or suprabasal (epidermal melasma), epidermis and superficial or medium dermis and inside melanophages (dermal melasma). With Wood light, melasma can be categorized as more evident (epidermal melasma), less evident (dermal melasma) or irregular (mixed melasma). Using dermoscopy, epidermal melasma is characterized by a brownish color and regular pigmented network, dermal melasma by a bluish-gray color and irregular network, and mixed melasma contains both of these features.<sup>3</sup>

Melasma can be treated topically with acid-based medications, bleaching agents, steroids and sunscreens, in addition to changes in patients' sun exposure habits. The most studied and successful treatment is a combination of retinoic acid, hydroquinone and corticosteroids.<sup>4</sup> Nonetheless, not all patients respond satisfactorily to these treatments, and even those who may have improved can experience a recurrence of the condition – especially during the summer, when the intensity of ultraviolet radiation is greater.

Some recent studies have demonstrated that the use of oral antioxidants could reduce the harmful effects of ultraviolet radiation on the skin.<sup>5</sup> Different substances with antioxidant activity have yielded this result and a nutri-concentrate compound with lycopene, *Lactobacillus johnsonii* and beta-carotene have also been used for this purpose.<sup>6</sup> Given the clear correlation between solar radiation and the worsening of melasma, we hypothesized that taking a nutri-concentrate with that composition could help stabilize the condition during periods with more intense ultraviolet radiation – especially during the summer in cities such as Rio de Janeiro.

This study evaluates the development of melasma with the use of oral antioxidants and UVA/UVB sunscreen during the summer months in Rio de Janeiro, the time with the highest levels of ultraviolet radiation.

## METHOD

This prospective, randomized, controlled study involved 68 melasma patients who were being monitored and treated at the

Cosmiatry Outpatient Clinic of the Dermatology Clinic of the Hospital Federal de Bonsucesso, Rio de Janeiro (RJ), Brazil. All patients signed a term of free and informed consent. The study protocol was approved by the Ethics and Research Committee of the hospital. The study began in December 2010 and ended in March 2011.

The inclusion criteria were: women aged 30–60, phototype III, IV or V (according to the Fitzpatrick scale), with facial melasma, who had been treated for at least 3 months. Study participants agreed to: replace their previous treatment with the study therapy, take the nutri-concentrate capsules as recommended, avoid excessive sun exposure and apply sunscreen as directed, and attend the control visits. The exclusion criteria were: patients with a known allergy or intolerance to the study substances proposed, those who were not willing or unable to use sunscreen during the study, patients who could not attend the control visits, and pregnant or breastfeeding women.

The nutri-concentrate used in this study was Inneov Solar<sup>®</sup>, supplied by the company Inneov (INNÉOV, France). The sunscreen used was Anthelios 60 Cream<sup>®</sup>, supplied by the company La Roche Posay (La Roche Posay, Brazil).

Patients were randomized into two groups of 34 cases each. Patients in Group A were treated with 1 nutri-concentrate capsule/day and applied sunscreen every 3 hours. Patients in Group B only used the sunscreen, in the same frequency. The patients were photographed and asked to answer a questionnaire at the first visit (D0) and every 4 weeks until the end of the study (D4, D8 and D12). The melasma's severity was assessed by the researcher physician using the Taylor Hyperpigmentation Scale 7 (Figure 1) at all consultation visits. The Melasma Area and Severity Index (MASI) 8 was calculated using the pictures taken at each consultation visit by two researcher physicians who were unaware of the classification of patients into groups (blind analysis). All data were subjected to statistical analysis.

Table 1 shows how the degree of each characteristic must be determined when calculating the MASI. The MASI value was calculated using the following formula:

$$\text{MASI} = 0.3 A (D F + H F) + 0.3 A (D RM + H RM) + 0.3 A (D LM + H LM) + 0.1 (D M + H M)$$

where:

"A" = area

"D" = degree of darkening

"H" = homogeneity of the melasma

"F" = forehead

"RM" = right malar

"LM" = left malar

"M" = mentum

The statistical analysis included an exploratory data analysis using summarized descriptive statistics (mean, standard deviation, minimum, median, maximum, frequency and percentage) and graphs (lines and bars). The between-group comparisons of the MASI scores was conducted using an ANOVA model for repeated measures. For each group, time points were compared



**Figure 1-** Taylor Hyperpigmentation Scale

using ANOVA models followed by the Tukey's multiple comparison test. The Taylor Hyperpigmentation Scale comparison between the groups was carried out for each of the follow-up visits using the non-parametric Mann-Whitney U test due to a violation in the normality assumption of the data. The differences between weeks 4, 8 and 12 results compared to week 0 results were used in the analysis. The time points were compared using the non-parametric Friedman test. The Nemenyi test was applied in multiple paired comparisons between weeks. The variables' normality was assessed using the Shapiro-Wilk test. A 95% confidence level was used in the analysis. The statistical software used in the analysis was XLSTAT 2011.

**RESULTS**

Three patients in Group A left the study due to vacations taken during the study period. Therefore, the statistical analysis was conducted on 65 patients. Patients were classified according to age as follows: 30-40 years old (19% in Group A and 30% in Group B), 41-50 years old (42% in Group A and 32% in Group B);

and 51-60 years old (39% in Group A and 38% in Group B). Most patients were classified as phototype III (55% in Group A and 50% in Group B) or phototype IV (45% in Group A and 41% in Group B). Almost all patients had had melasma for more than 2 years (97% in both groups) and all had undergone some type of treatment. Patients in both groups reported an improvement in their melasma (61% of Group A and 53% of Group B). In addition to improvement of the melasma, patients also reported improvements in other characteristics of the skin, such as resistance to sunlight (52% of patients in Group A), skin brightness (26% in Group A and 50% in Group B) and firmness (9% in Group A and 11% in Group B) (Graph 1). Group A showed a decrease in their melasma of 8.5% according to the Taylor Hyperpigmentation Scale and of 19.5% according to the MASI; the latter was statistically significant (Graph 2). In Group B, there was a worsening of the melasma according to the Taylor Scale and an improvement of 4.6% according to the MASI (Graph 3).

Among the 31 Group A patients who completed the study, one reported suffering from nausea and another from diarrhoea – sporadic episodes in both cases. In Group B, one patient had comedonal acne due to the use of sunscreen.

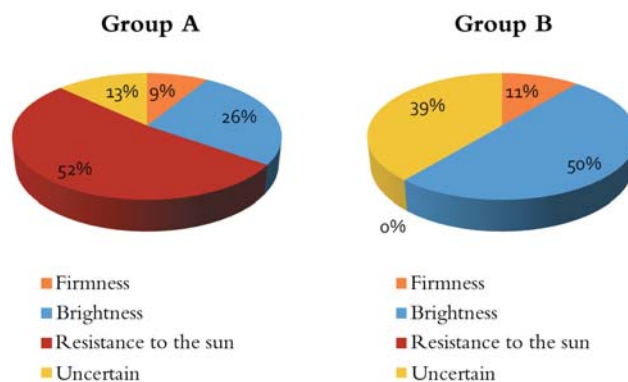
Figures 2 to 4 demonstrate the clinical development of 3 patients in Group A who presented improvement in their melasma during the course of the study.

**DISCUSSION**

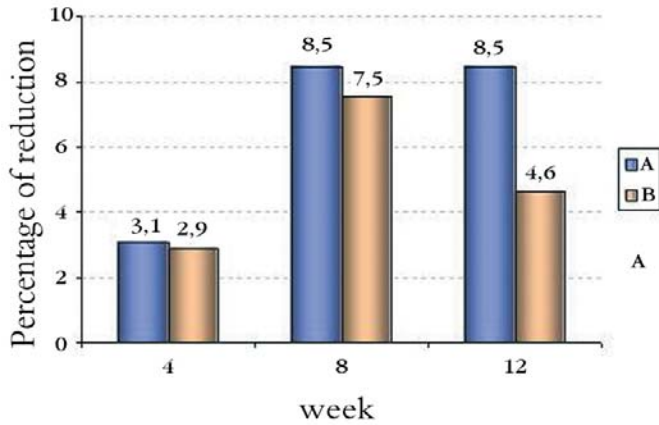
Melasma is a considerably frequent and stigmatizing dermatosis. Although it is widely studied – given the large number of publications on the subject in recent years – its exact pathogenesis is not yet fully determined, and there is no effective treatment for its control and cure.<sup>4</sup> Even in cases that present good clinical results following treatment, recurrences are frequent. More recently, treatments with oral antioxidants that decrease the harmful effects of ultraviolet radiation on the skin have been proposed.<sup>5-9</sup> Several substances have shown such a result, and a nutri-concentrate comprised of lycopene, the probiotic *Lactobacillus johnsonii* and beta-carotene has been used with this purpose.<sup>10</sup>

**Table 1- Gradation Scale for MASI calculation**

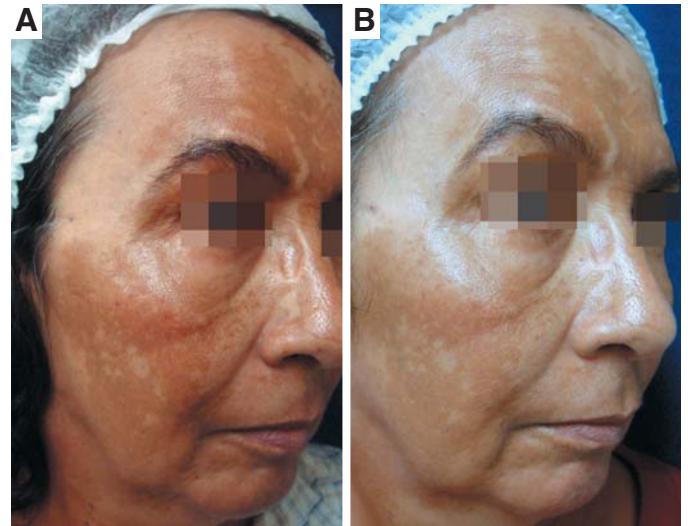
Grade	Darkening	Homogeneity	Area
0	Absent	Minimum	Not affected
1	Mild	Mild	< 10%
2	Moderate	Moderate	10 to 29%
3	Intense	Intense	30 to 49%
4	Very intense	Very intense	50 to 69%
5			70 to 89%
6			90 to 100%



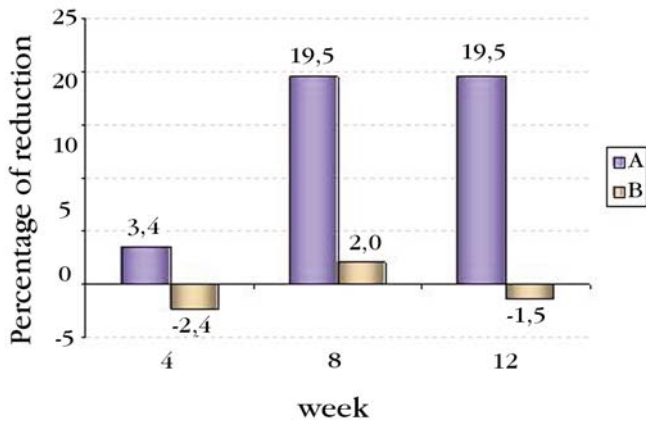
**Graph 1 -** Results reported by patients



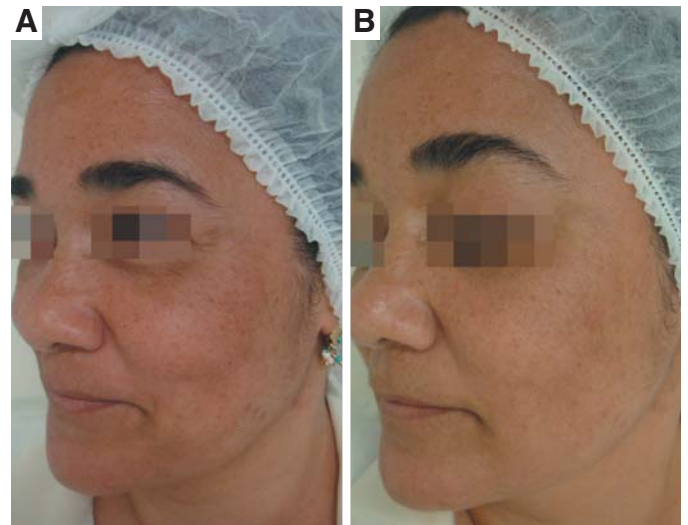**Graph 2** - Percentage of average reduction of melasma based on the Taylor Hyperpigmentation Scale (compared to Week0, by Group)



**Figure 2 - A:** Group A, patient 1, at baseline (D0)  
**B.** Group A, patient 1, at the end of the study (D12)



**Graph 3** - Percentage of average reduction of melasma based on the MASI (compared to Week0, by Group)



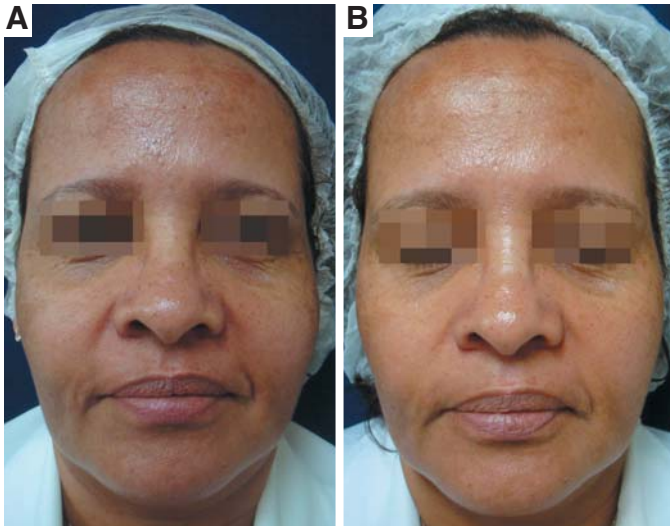
**Figure 4 - A.** Group A, patient 3, at baseline (D0)  
**B.** Group A, patient 3, at the end of the study (D12)

Probiotics are defined as live microorganisms that, when consumed in adequate amounts, benefit the health of their host. The lactic acid bacteria species, including lactobacilli and bifidobacteria, are part of the human natural intestinal microbiota. It is known that endogenous intestinal microbiota play a crucial role in the development of the immune system, intestinal integrity and defence of the body against pathogens.<sup>6,9</sup> Some studies have demonstrated that probiotics are able to modulate the immune system at the local and systemic levels, influencing the immunological defence mechanisms and/or assisting in the control of immunological diseases such as bowel inflammations or allergies.<sup>9</sup> In that same study, the authors demonstrated that *Lactobacillus johnsonii* can decrease UV irradiation-induced depletion of Langerhans cells in the epidermis of mice.<sup>9</sup> Bouilly-Gauthier and others described a reduction in skin damage and skin aging caused by UV exposure with a nutritional supplement containing probiotics and carotenes.<sup>10</sup>

In their article on nutritional supplementation, Stahl and colleagues highlight beta-carotene's photoprotection properties, based on evaluating the skin's response to sun exposure in a group of patients who took beta-carotene, lycopene and lutein for 12 weeks. The degree of erythema after sun exposure was analyzed at 6 and 12 weeks, and the use of carotenoids was proven to reduce solar radiation-induced erythema.<sup>11</sup>

In the present study, due to the high incidence of ultraviolet radiation in the city of Rio de Janeiro, we attempted to verify whether the topical use of a nutri-concentrate composed of lycopene, beta-carotene and *Lactobacillus johnsonii* would provide additional photoprotection for patients undergoing





**Figura 4 - A.** Paciente 3 do grupo A, no início do estudo (D0).  
**B.** Paciente 3 do grupo A, no final do estudo (D12).

maintenance treatment for melasma. These patients usually present a worsening of the condition during the months with the highest intensity of solar radiation. As previously mentioned, we observed that most patients who used the supplement presented clinical improvement in or stability of their melasma during the study period.

Therefore, we conclude that the use of beta-carotene, lycopene and *Lactobacillus johnsonii* was effective as an adjunct treatment in the maintenance of patients with melasma during the summer months. ●

## REFERÊNCIAS

1. Pandya AG, Guevara IL. Disorders of hyperpigmentation. *Dermatol Clin*. 2000; 18(1): 91-9.
2. Gupta A, Gover M, Nouri K, Taylor S. The treatment of melasma: A review of clinical trials. *J Am Acad Dermatol*. 2006;55(6): 1048-65.
3. Tamler C, Fonseca RMR, Pereira FBC, Barcauí CB. Classificação do melasma pela dermatoscopia: estudo comparativo com lâmpada de Wood. *Surg Cosmet Dermatol*. 2009;1(3):115-9.
4. Rajaratnam R, Halpern J, Salim A, Emmett C. Interventions for melasma. *Cochrane Database Syst Rev*. 2010; 7(7):CD003583.
5. Handog EB, Galang DA, de Leon-Godinez MA, Chan GP. A randomized, double-blind, placebo-controlled trial of oral procyanidin with vitamins A, C, E for melasma among Filipino women. *Int J Dermatol*. 2009;48(8):896-901.
6. Guéniche A, Philippe D, Bastien P, Blum S, Buyukpamukcu E, Castiel-Higounenc. Probiotics for photoprotection. *Dermato-endocrinol*. 2009;1(5):275-9.
7. Taylor S, Westerhof W, Im S, Lim J. Noninvasive techniques for the evaluation of skin color. *J Am Acad Dermatol* 2006; 54(5 suppl 2): S282-90.
8. Pandya AG, Hynan LS, Bhole R, Riley FC, Guevara IL, Grimes P, et al. Reliability assessment and validation of the Melasma Area and Severity Index (MASI) and a new modified MASI scoring method. *J Am Acad Dermatol*. 2011; 64(1): 78-83.
9. Pequet-Navarro J, Dezutter-Dambuyant C, Buetler T, Leclaire J, Smola H, Blum S, et al. Supplementation with oral probiotic bacteria protects human cutaneous immune homeostasis after UV exposure-double blind, randomized, placebo controlled clinical trial. *Eur J Dermatol*. 2008;8(5):504-11.
10. Bouilly-Gauthier D, Jeannes C, Maubert Y, Duteil L, Queille-Roussel C, Piccardi N, et al. Clinical evidence of benefits of a dietary supplement containing probiotic and carotenoids on ultraviolet-induced skin damage. *Br J Dermatol*. 2010;163(3):536-43.
11. Stahl W, Sies H. Photoprotection by dietary carotenoids: concept, mechanisms, evidence and future development. *Mol Nutr Food Res*. 2011 Sep 23. [Epub ahead of print].