

## Original Article

# Laserlipolysis experience: findings from 120 cases studied from 2004 to 2010

*Experiência em laserlipólise: casuística de 120 casos no período de 2004 a 2010*

### Authors:

Sandra Tagliolatto<sup>1</sup>  
 Vanessa Barcellos Medeiros<sup>2</sup>  
 Patrícia Cristiane de Sousa Teresani<sup>2</sup>  
 Oriete Gerin Leite<sup>2</sup>  
 Janaína Vilela Filipe<sup>2</sup>  
 Carla Bassanezi Mazzaro<sup>2</sup>  
 Patrícia Accione Rover<sup>2</sup>  
 Renata Rita Oliveira Fernandes<sup>3</sup>

<sup>1</sup> Masters in Science, Surgical and Clinical Dermatology Department, Universidade Federal de São Paulo (Unifesp) – Campinas (SP), Brazil

<sup>2</sup> Dermatologist Physician – Campinas (SP), Brazil

<sup>3</sup> Plastic Surgeon Physician – Campinas (SP), Brazil

### Correspondence:

Sandra Tagliolatto  
 Rua Luzitana, 740 4. andar - Bosque  
 13015-121 - Campinas – SP  
 E-mail: dermoclinica@dermoclinica.med.br

Received on: 28 November 2011

Approved on: 6 December 2011

This study was carried out at a private practice in Campinas (SP), Brazil.

Financial support: None  
 Conflicts of interest: None

### ABSTRACT

**Introduction:** Laserlipolysis is an emerging technique in the treatment for localized fat and Skin tightening. This therapy has a shorter post-operative recovery time and fewer adverse effects than conventional liposuction.

**Objective:** This study describes the authors' experience in laserlipolysis and evaluates the technique's safety and efficacy.

**Methods:** Retrospective study of 120 patients who underwent laserlipolysis, which was administered via two devices with different wavelengths: 1064-nm Nd:YAG laser and 924 nm/975 nm diode laser.

**Results:** According to clinical and photographic follow up, there was a significant improvement in localized fat in the definition of the body's contour and in the skin tightening in all studied patients; 108 patients were satisfied with the technique. There were no cases of atrophic scars, hyperpigmentation, hypopigmentation or infection.

**Conclusions:** If properly recommended and carefully carried out, laserlipolysis is a safe and highly satisfactory option for the treatment localized fat and sagging skin.

**Keywords:** lasers; lipectomy; subcutaneous fat; collagen.

### RESUMO

**Introdução:** A laserlipólise é técnica emergente no tratamento da gordura localizada e na retração cutânea. Essa opção terapêutica tem demonstrado vantagens em relação à lipoaspiração convencional, com menor tempo de recuperação pós-operatória e menores efeitos adversos.

**Objetivo:** Relatar experiência em laserlipólise e avaliar a técnica quanto a sua segurança e eficácia.

**Métodos:** Estudo retrospectivo de 120 pacientes submetidos a laserlipólise através do uso de dois aparelhos, com diferentes comprimentos de onda, o laser de 1064-nm Nd:YAG e o laser de diodo 924nm/975nm.

**Resultados:** Houve significativa redução da gordura localizada, definição do contorno corporal e retração da pele em todos os pacientes analisados, segundo seguimento clínico e fotográfico. Cento e oito pacientes revelaram satisfação com o uso do método. Não ocorreram casos de cicatrizes atróficas, hiperpigmentação, hipopigmentação ou infecção.

**Conclusões:** A laserlipólise realizada com indicação criteriosa oferece aos médicos e pacientes opção terapêutica segura e com alto grau de satisfação no tratamento da gordura localizada e flacidez da pele.

**Palavras-chave:** lasers; lipectomia; gordura subcutânea; colágeno.

## INTRODUCTION

Laserlipolysis is a new technique. The US Food and Drug Administration (FDA) approved the first device for use in subcutaneous tissue, the 1,064 nm Nd:YAG laser, in October 2006. The procedure entails applying the laser directly to the adipose tissue in order to melt the fat and stimulate the production of dermal collagen.<sup>1</sup>

Laserlipolysis is currently seen as an effective method for removing fat and improving the shape of the body and face.<sup>2</sup> Although not intended as a replacement for conventional liposuction,<sup>3,4</sup> laserlipolysis offers similar clinical results and has the additional benefit of stimulating cutaneous retraction – skin tightening – and has a fast recovery time, with less pain than the classic technique.<sup>5,6</sup>

Laserlipolysis' mechanism of action is based on the classic principle of selective photothermolysis, in which the energy liberated by the laser is transformed into heat when it reaches its target tissue or chromophores (fat and collagen). Subsequently, the thermolipolysis and denaturation of the collagen fibers occur, with the preservation of the septal architecture, which contributes to the increase in cutaneous retraction.<sup>2</sup> It is important to note that the use of laser also promotes the coagulation of small subcutaneous vessels, which reduces blood loss and ecchymoses.<sup>1</sup> Additionally, it is important to highlight that the aspiration of the liquefied fat is often carried out after the passing of the laser.<sup>11,16</sup>

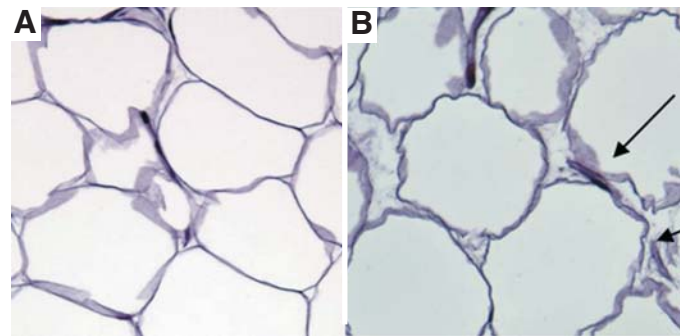
The fatty tissue's optic coefficient has been estimated at 400–1500 nm; the irreversible damage to adipocytes appears to be similar in wavelengths of 920–1320 nm. As a result, there are currently a number of lasers with different wavelengths that can be used in laserlipolysis procedures.<sup>7</sup> Many published studies evaluating those different lasers have demonstrated that the removal of small volumes of fat, combined with cutaneous retraction, can be carried out safely and effectively, with the additional benefits of excellent tolerance and fast recovery times.<sup>2,5,8–10</sup>

The optimization of the adipocytolysis and the stimulation of collagen fibers depend on the amount of thermal energy accumulated in the tissue. This energy is delivered through the slow and sustained application of an internal cannula fitted with fiber optics, which can maintain a local temperature of 40–42° C.<sup>7,11</sup>

Histological studies suggest that the benefits of laser include the destruction of fat cells, the retraction of the skin and a reduction in intra-operative bleeding (Figure 1). Nevertheless, some authors remain skeptical about the high efficacy of laserlipolysis, due to uncertainties about the ideal wavelength.<sup>13</sup>

With the use of the 1,064 nm wavelength Nd:YAG laser, clinical and histological studies describe a significant contraction in the skin three months after the procedure and an increase in collagen fibers. A coagulation of the blood vessels and lysis of the adipocytes were also observed.<sup>14,15</sup>

The efficacy and safety of the 924 nm diode laser (the wavelength that targets fat) combined with the 975 nm wavelength (to



**Figura 1 - A.** corte histológico demonstrando as células de gordura com membranas intactas. **B.** corte histológico demonstrando as células de gordura com membrana destruída

provide dermal heating) were evaluated in the treatment of fat reduction and promotion of cutaneous retraction in several areas of the body. High tolerability to the treatment (with minimal and transient side effects such as erythema, ecchymoses and edema) and a high level of patient satisfaction were described.<sup>9</sup>

The treatment's efficacy in decreasing fat and improving cutaneous elasticity, independently of the wavelength used, is described by many authors as being more apparent three months after the procedure.<sup>6,9,14–16</sup>

The most frequently observed side effects of laserlipolysis are discomfort, ecchymoses, erythema and edema, all of which resolve in up to one week after the procedure. Patients are usually able to resume their daily activities after 24 hours.<sup>5,15,14</sup> No systemic complications were described in the literature; the few local complications were infections and cutaneous burns.<sup>1,17</sup>

This study describes the surgical technique and evaluates the safety and efficacy profile of laserlipolysis in different areas of the body, based on the use of two different lasers, in 120 patients who underwent the procedure over a 7-year period.

## METHODS

A retrospective study was carried out to evaluate the medical records of 120 patients (10 men and 110 women, aged 22–68) who underwent laserlipolysis at private practices between 2004 and 2010. A 1,064 nm Nd:YAG laser (SmartLipo®, Deka, Italy), was used in 60 cases, while a 964 nm/975 nm diode laser (SlimLipo®, Palomar, USA) was used in the other 60 cases. It is important to note that comparing the two lasers was not one of the study's primary objectives.

## LASERS

According to the orientation of the manufacturer, in the 1,064 nm Nd:YAG laser, the energy parameters were kept constant (6 W – 40 Hz – 150 mJ), with variations in the amount of accumulated energy. An average accumulated energy of 2000 J per each approximate area of 20 cm<sup>2</sup> was kept constant in the subcutaneous region.

For the 924 nm/975 nm diode laser, the parameters (power

and accumulated energy) were chosen according to the treated area, ranging from at least 10 KJ of accumulated energy (in the case of small submental fat deposits) to up to 80 KJ (in the case of large abdomens). In extreme cases, the minimum standards of energy of the 924 nm/975 nm lasers were used (around 10 W/12 W in the case of small submental fat deposits and high parameters – 20 W/20 W – for the larger abdomens). In general, however, the choice of parameters was based on a table supplied by the manufacturers of the equipment. In both lasers, the amount of accumulated energy was adjusted according to the size of the treated area and the patient's tolerance.

### BODY AREAS TREATED

A total of 218 procedures were carried out in different parts of the body. Some patients were treated in multiple areas, however not always in the same surgery. The procedures were distributed as follows: abdomen (28 cases with Nd:YAG laser and 44 cases using diode laser), hips (24 cases with Nd:YAG laser and 30 cases using diode laser), outer thigh (six cases using Nd:YAG laser and eight cases with diode laser), inner thigh (two cases with Nd:YAG laser and six cases using diode laser), infra-gluteal region (two cases with Nd:YAG laser and 12 cases with diode laser), anterior region of the thighs and knees (two cases with diode laser), gluteal region (four cases using Nd:YAG laser and four cases with diode laser), back (six cases with Nd:YAG laser and four cases with diode laser), triceps (four cases using Nd:YAG laser and six cases with diode laser), submental region (ten cases with Nd:YAG laser and 12 cases using diode laser), gynecomastia (two cases with diode laser), lower eyelids (two cases with Nd:YAG laser) (Graph 1).

### PRE-OPERATIVE CARE

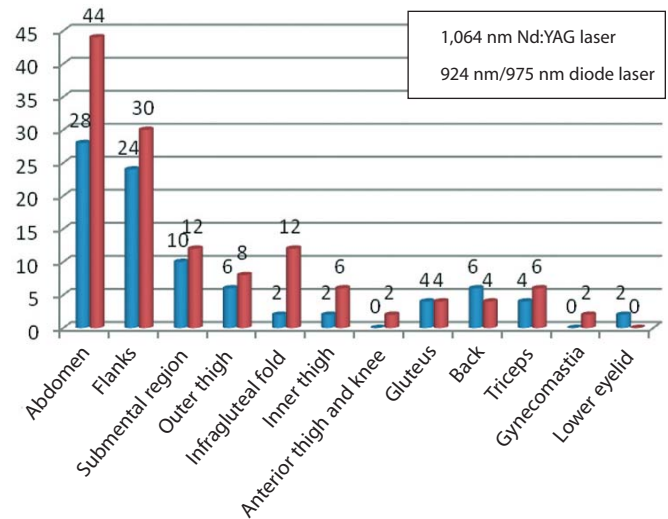
All patients submitted a detailed medical history and were asked about comorbidities and their use of medications. The following laboratorial tests were requested: complete blood count, coagulogram, hCG, fasting plasma glucose test and protein electrophoresis when appropriate; specific examinations were conducted in particular cases, such as viral serology, cholesterol and triglycerides, renal and/or hepatic function, abdominal ultrasound, cardiological evaluation, etc.

A term of informed consent and pre- and post-treatment guidance were supplied to the patients. These documents explained the procedures and instructed patients on the use of medications (prophylactic antibiotics and analgesics, if necessary), compressive garments, and the need to limit sun exposure and rigorous physical activity. It also described the expected recovery process.

All patients were weighed, measured and documented photographically, with the demarcated areas under the same illumination and positioning parameters.

### SURGICAL TECHNIQUE

The procedure was carried out in an outpatient operating room. Each patient was fitted with a pulse oximeter to monitor vital signs, and had his or her blood pressure taken before,



**Graph 1:** Patients' distribution according to the treated site and the type of laser used

during and after the procedure.

In all cases, the anesthetic point and subsequent micropuncture were carried out using a number 15 scalpel blade in the most appropriate site in order to allow good access to the demarcated area. All procedures used Klein's tumescent anesthesia (1,000 ml of 0.9% saline solution + 1 ml of 1/1,000 epinephrine + 25 ml of 2% lidocaine without vasoconstrictor + 10 ml of 10% sodium bicarbonate), injected through infusion pump, controlled for maximum volume according to the patient's weight.<sup>18</sup> The highest volume of Klein's anesthetic used in our cases, was 2,000 ml, which is below the maximum dose of 35 mg/kg used when liposuction is performed.<sup>18</sup>

The preparation of the laser – assembly of fibers and adjustment of parameters – was adjusted for each patient, while waiting for the anesthesia to take effect.

After obtaining local vasoconstriction with the tumescent anesthesia, the fiber optic microcannula was inserted in the subcutaneous in the same micropuncture as the anesthesia. The cannula was then slowly moved forwards and backwards, promoting a uniform distribution of energy in the treated area. Cutaneous temperature was monitored using an external optic thermometer.

When the established parameters were reached and the fat was felt to "soften" in the treated area, the application of the laser was halted. In most cases, the melted fat was aspirated using thin liposuction cannulas and low pressure, with a fluid fatty substance being observed; in general there was less bleeding and, consequently, greater ease in removing the fat. It is important to note that the decision about whether to aspirate was based on each patient's psychological characteristics and amount of excess fat, and their degree of urgency for results. In patients with cutaneous sagging without considerable amounts of localized fat, no aspiration was carried out after the laser application.

In each patient, the remaining accumulated liquid was drained from the subcutaneous up until the insertion puncture

and the wound was sutured. At the end of the procedure, a compression bandage was applied at the site of the puncture and the patient was discharged if accompanied.

### POST-OPERATIVE CARE

After 24 hours, all patients had resumed their routines, except for those that involved vigorous physical activity or sun exposure. They were instructed to use commercially available compressive garments made for specific parts of the body for two weeks (submental region) to four weeks (abdominal region, hips and outer thighs). After seven days they returned for the first photographic evaluation and the removal of sutures.

Drainage and use of 3 Mhz ultrasound (Manthus®, KLD) in the post-operative period were recommended, and the follow-up visits were scheduled (for seven days, and one, two, three and six months). The follow-up visits were aimed at monitoring the regression of the inflammatory process (marked by edema and fibrous areas), and the gradual improvement of the body contour through clinical examination and standardized pictures.

### RESULTS

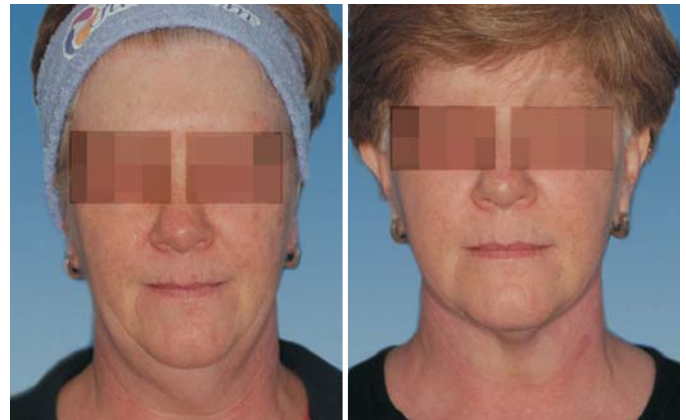Patients ( $n = 120$ ) were treated between 2004 and 2010; 218 procedures were carried out in different areas of the body. The areas that underwent laserlipolysis most frequently were the abdomen, hips, infragluteal region, outer thighs and submental region (Graphic 1).

In the subsequent follow-up visits, a significant reduction of fat and the correction of the contour and retraction of the skin were observed in the treated areas in the clinical examinations and comparison of pictures. Most patients expressed satisfaction with the outcome in the first follow-up visit, with the number of positive feedbacks increasing in the following months – especially after the third month, when improvement was observed in all patients (Figures 2 to 6).

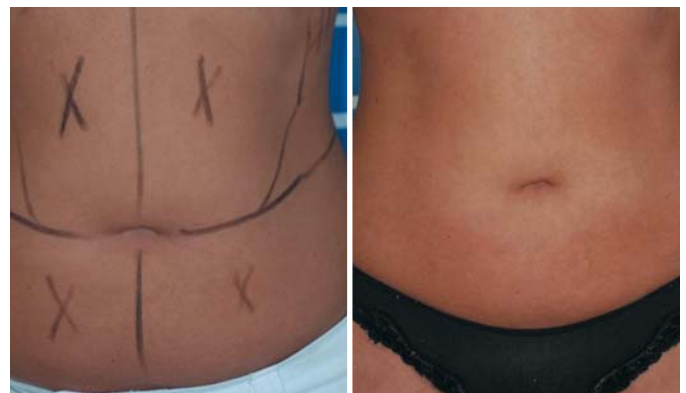Regarding adverse effects, no scars, infections, hypo or hyperpigmentation were observed. Edema and ecchymoses (with spontaneous resolution in one to four weeks) were observed in all patients, in different intensities and proportionally to the procedure's magnitude. Small areas with fibrosis (which resolved spontaneously or after the use of local ultrasound) were observed in most patients in the first months after the procedure.

Ninety percent (108 patients) were satisfied with the results (Graph 2). All 12 patients who expressed dissatisfaction nevertheless described some degree of improvement. Of the dissatisfied patients, it was concluded that in four cases, liposuction should not have been recommended, due to the excess fat and sagging of the skin. The patients' psychological profiles were not favorable to the type of procedure in three cases. In the remaining five cases of dissatisfaction there were unrealistic expectations regarding the technique and the results after a single application (Graph 3).

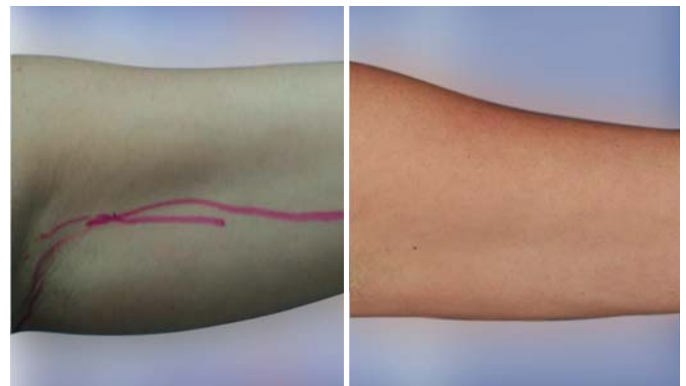
Except for four cases, complementary procedures were carried out using the same technique, with improvement of the final outcome. The use of complementary techniques, such as a low potency diode laser (Tri-active®, Deka, Italy) or radiofre-



**Figure 2** - Pictures before and 60 days after laserlipolysis and aspiration carried out in the submental region with 924 nm/975 nm diode laser

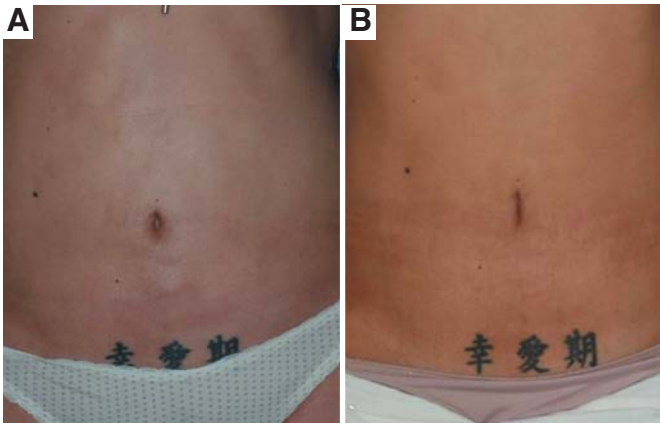


**Figure 3** - Pictures before and six months after treatment in the abdomen with 1,064 nm Nd:YAG laser + aspiration

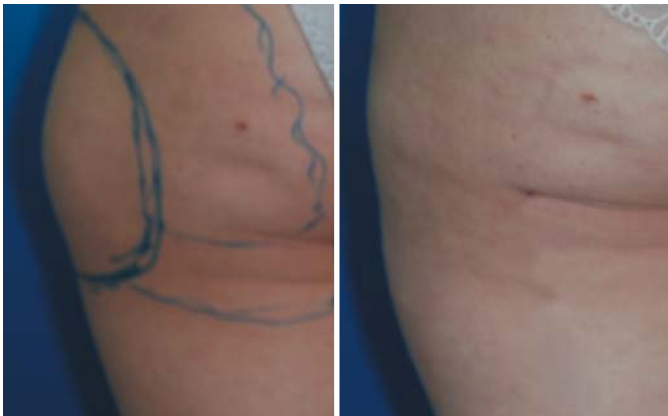

**Figure 4** - Pictures before and three months after treatment in the arms with 1,064 nm YAG laser + aspiration

quency (Reaction®, Viora, USA) was suggested in two cases, with improvement in the final outcomes. Two of the patients who were dissatisfied with the final outcome did not attend the follow-up. Finally, it is important to note that the number of patients dissatisfied with the procedure's outcome was similar between the two lasers used.



**Figure 5** - Pictures before and six months after the use of the 924 nm/975 nm diode laser (without aspiration) in the abdomen region, with sequelae from conventional liposuction (residual fibroses) carried out five years before, at another clinic. **A.** Note the retraction in the umbilical region **B.** There was no change in the patient's weight



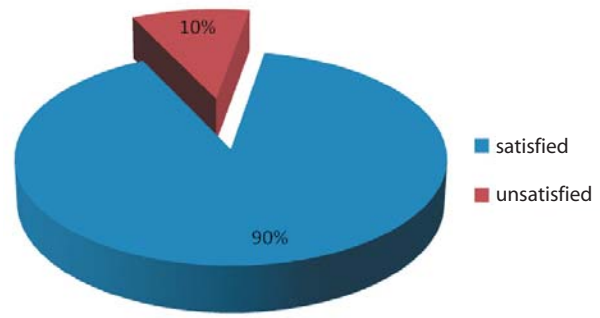
**Figure 6** - Pictures before and seven days after treatment for removing localized fat in the outer thigh (1,064 nm YAG laser and aspiration) and gluteal (1,064 nm YAG laser) regions.

**DISCUSSION**

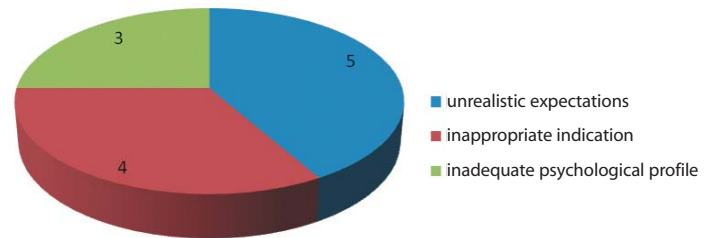
The laserlipolysis application technique requires specific training and constant attention in its execution, and when carried out carefully usually reaches its objectives, providing physicians and patients a high degree of satisfaction.<sup>9,15,17</sup>

The two devices used in this retrospective study were shown to be effective and safe. However, peculiarities were observed between them. For example, the 924 nm/975 nm diode laser's fiber optic cannula is more flexible and facilitates the execution of the procedure, but it cannot be reused, which increases the cost of the procedure.

Although there are few studies on laserlipolysis in the literature, the technique has demonstrated results similar to those of conventional liposuction in several areas of the body. The advantages of this new technique are: the promotion of cutaneous retraction, a shorter recovery time and less physical exertion for the surgeon, since the thermal action makes the sliding of the



**Graph 2** - Percent distribution of patient satisfaction after a single laserlipolysis session



**Graph 3** - Causes of therapeutic failure in the 12 patients who were unsatisfied after the procedure

cannula easier.<sup>9,13,19</sup> The decrease in post-operative trauma is probably associated with the capacity of coagulation of the small vessels of the adipose tissue and the smaller diameter of the cannulas used in the procedure.<sup>19</sup>

The findings of this study are in line with data found in the literature regarding the degree of satisfaction with laserlipolysis. Katz and colleagues<sup>1</sup> evaluated 537 laserlipolysis procedures and concluded that it is a safe and effective technique for the removal of localized fat. DiBernardo<sup>4</sup> found statistical significance in the superiority of the cutaneous retraction obtained using laserlipolysis compared with conventional liposuction.

It is also important to highlight the absence of systemic or serious complications in the cases studied, as well as a lack of other adverse effects that are typical of lasers, such as burns, bleedings or infections – which also supports the findings in the literature.<sup>1,5,15-17</sup>

This technique's efficacy and safety seem to be correlated to the amount of accumulated energy in the target tissue and, consequently, to variation in the local temperature, which must be kept constant at 40-42° C.<sup>7,11,13,14,17</sup>

Further studies regarding the definition of the ideal final temperature will help achieve better results with laserlipolysis, a procedure that already provides a high degree of patient satisfaction.

**CONCLUSIONS**

Based on our accumulated experience with the use of lasers in laserlipolysis treatments and the related literature, we can assert that laserlipolysis is an effective and safe procedure to

be used in the reduction of localized fat and cutaneous retraction treatment.

A precise surgical indication and the correct orientation of the patient regarding the technique and its limitations are fundamental for a high degree of satisfaction among physicians and patients.

Further prospective controlled studies on laserlipolysis are necessary to improve the technique and optimize the parameters in order to increase the efficacy and safety of the procedure. ●

## REFERENCES

- Katz B, McBean J. Laser-assisted lipolysis: a report on complications. *J Cosmet Laser Ther.* 2008;10(4):231-33.
- Sasaki GH, Tevez A. Laser-assisted liposuction for facial and body contouring and tissue tightening: a 2-year experience with 75 consecutive patients. *Semin Cutan Med Surg.* 2009;28(4):226-35.
- Martinez MAR, Okajima RMO, Proto RS, Lourenço LM, Machado CDSF. Estudo de 543 pacientes submetidos à lipoaspiração tumescente. *Surg Cosmet Dermatol.* 2010;2(3):155-58.
- Borges J, Cotrim CMMP, Dacier B. Segurança em lipoaspiração usando a anestesia local tumescente : relato de 1107 casos no período de 1998 a 2004. *Surg Cosmet Dermatol.* 2011;3(2):117-121.
- Llanos Olmedo S, Danilla S, Cavada G, Searle S, Ponce, D, Navarrete L, Navarrete S, et al. Comparación del dolor secundario a lipoaspiración tradicional versus lipolisis láser. Estudio prospectivo/ Postoperative pain in suction assisted lipoplasty versus laser lipolysis. *Cir Plast Ibero-latinoam.* 2007;33(4):221-32.
- Dibernardo BE. Randomized, blinded split abdomen study evaluating skin shrinkage and skin tightening in laser-assisted liposuction versus liposuction control. *Aesthet Surg J.* 2010;30(4):593-602.
- Wassmer B, Zemmouri J, Rochon P, Mordon S. Comparative study of wavelengths for laser lipolysis. *Photomed Laser Surg.* 2010;28(2):185-88.
- Forman TA, Friedman A. Laser lipolysis with a 980 nm diode laser. *J Drugs Dermatol.* 2010;9 (5 Suppl ODAC Conf Pt 1):s58-s61.
- Weiss RA, Beasley K. Laser-assisted liposuction using a novel blend of lipid- and water-selective wavelengths. *Lasers Surg Med.* 2009;41(10):760-66.
- Woodhall KE, Saluja R, Khoury J, Goldman MP. A comparison of three separate clinical studies evaluating the safety and efficacy of laser-assisted lipolysis using 1,064, 1,320 nm, and a combined 1,064/1,320 nm multiplex device. *Lasers Surg Med.* 2009;41(10):774-78.
- Mazer JM. Lipolysis lasers. *Ann.Dermatol.Venereol.* 2009;136 (Suppl 6):S359-S362.
- Mordon S, Eymard-Maurin AF, Wassmer B, Ringot J. Histologic evaluation of laser lipolysis: pulsed 1064-nm Nd:YAG laser versus cw 980-nm diode laser. *Aesthet Surg J.* 2007;27(3):263-68.
- Seckel BR, Doherty ST, Childs JJ, Smirnov MZ, Cohen RH, Altshuler GB. The role of laser tunnels in laser-assisted lipolysis. *Lasers Surg Med.* 2009;41(10):728-37.
- Sasaki GH. Quantification of human abdominal tissue tightening and contraction after component treatments with 1064-nm/1320-nm laser-assisted lipolysis: clinical implications. *Aesthet Surg J.* 2010;30(2):239-45.
- Sadick NS, Diktaban T, Smoller BR. New clinical outcomes utilizing a 1064-nm Nd:YAG laser for lipolysis of the torso oblique region. *J Cosmet Laser Ther.* 2010;12(4):170-75.
- Dudelzak J, Hussain M, Goldberg DJ. Laser lipolysis of the arm, with and without suction aspiration: clinical and histologic changes. *J Cosmet Laser Ther.* 2009;11(2):70-3.
- Reynaud JP, Skibinski M, Wassmer B, Rochon P, Mordon S. Lipolysis using a 980-nm diode laser: a retrospective analysis of 534 procedures. *Aesthetic Plast Surg.* 2009;33(1):28-36.
- Klein JA. Tumescent technique for regional anesthesia permits lidocaine doses of 35 mg/kg for liposuction. *J Dermatol Surg Oncol.* 1990;16(3):248-63.
- Goldman A. Submental Nd:YAG laser-assisted liposuction. *Lasers Surg Med.* 2006;38(3):181-4.