

Dermoscopic findings of radial streaming, blue hue and vascular structures as a tool to differentiate doubtful nevi and early melanomas: a comparative study

Achados dermatoscópicos com estrias radiadas, tonalidade azulada e estruturas vasculares como ferramenta na diferenciação entre nevos duvidosos e melanomas precoces: um estudo comparativo

Authors:

Michelle Alvarenga Mansur¹
Gisele Gargantini Rezze²
Maria do Rosário Dias de Oliveira Latorre³
João Pedreira Duprat Neto⁴

- ¹ Dermatologist Physician in private practice – São Paulo (SP), Brazil
² Dermatologist Physician, Skin Cancer and Dermatology Center, Hospital AC Camargo da Fundação Antonio Prudente – São Paulo (SP), Brazil
³ Cutaneous Oncology Department, Universidade de São Paulo (USP) – São Paulo (SP), Brazil
⁴ Oncologic Surgeon, Skin Cancer and Dermatology Center, Hospital AC Camargo da Fundação Antonio Prudente

Correspondence:

Gisele Gargantini Rezze
Rua Barata Ribeiro, 380 cj. 34
01308-000 - São Paulo - SP
Email: ggrezze@hotmail.com

Received on: 10 October 2011
Approved on: 1 December 2011

This study was carried out at the Skin Cancer and Dermatology Center, Hospital AC Camargo – São Paulo (SP), Brazil.

Financial support: None
Conflicts of interest: None

ABSTRACT

Introduction: One of the most challenging dermoscopic situations is to distinguish between early melanomas and doubtful benign nevi. At times, suspicious melanocytic lesions have dermoscopic features similar to melanomas, thus leading to excessive excisions of lesions.

Objective: To develop a dermoscopic model that helps to differentiate the doubtful nevus from the early melanoma.

Material and methods: A total of 219 histopathologically confirmed dermoscopic images were analyzed and a comparison between doubtful nevi and early melanomas was then performed.

Results: The final model was based on three dermoscopic features: radial streaming, blue hue and vascular structures. If all three features were absent, it was most likely a nevus; if one dermoscopic feature was present, it could be a nevus or melanoma; if two features were present, there was a greater probability of melanoma diagnosis; if three features were present, it was melanoma.

Conclusion: This model could help for the surgical decision.

Keywords: dermoscopy; melanoma; nevus, pigmented;

RESUMO

Introdução: Um dos maiores desafios em dermatoscopia é diferenciar melanomas precoces e nevos benignos duvidosos. Lesões melanocíticas suspeitas algumas vezes possuem características dermatoscópicas similares às dos melanomas, induzindo a excisões excessivas.

Objetivo: Desenvolver um modelo dermatoscópico que auxilia na diferenciação entre o nevo duvidoso e o melanoma precoce.

Métodos: Um total de 129 imagens confirmadas histopatologicamente foram analisadas, seguindo-se uma comparação entre nevos duvidosos e melanomas precoces.

Resultados: O modelo final baseou-se em três características dermatoscópicas: estrias radiadas, tonalidade azulada e estruturas vasculares. Na ausência das três características, havia grande probabilidade da lesão tratar-se de um nevo; se uma das características dermatoscópicas estivesse presente, a lesão poderia ser classificada como nevo ou melanoma; se duas das características estivessem presentes haveria maior probabilidade de diagnóstico de melanoma; se as três características estivessem presentes, então se tratava de um melanoma.

Conclusão: O modelo desenvolvido pode auxiliar na decisão cirúrgica.

Palavras-chave: dermatoscopia; melanoma; nevo pigmentado;

INTRODUCTION

Cutaneous melanoma has been increasing over the last few decades;¹ it represents 4% of all dermatologic cancers and accounts for 80% of deaths from skin cancer.² Since there is an inverse correlation between survival rate and tumor thickness, early diagnosis is essential.³ Dermoscopy was introduced as an auxiliary clinical examination method, which allows the visualization of structures located under the stratum corneum that are not clearly visible to the naked eye. It has greatly improved the early diagnosis of melanoma during the initial stages of evolution and infiltration. When compared with clinical criteria alone, dermoscopy produces a significant improvement in the diagnostic accuracy of pigmented skin lesions.^{4,5,6}

However, dermoscopy is not 100% accurate, and some tumors can be misdiagnosed.⁷ The challenge for clinicians who examine patients with pigmented skin lesions in daily practice is to distinguish between early melanomas and doubtful benign nevi. Occasionally, those difficult melanocytic lesions have common dermoscopic characteristics, thus leading to the misdiagnosis of melanomas and the excessive excision of benign lesions.⁸ Therefore, this study developed a dermoscopic model to help differentiate the doubtful nevi (common compound and atypical nevi) from the early melanomas (in situ and thin melanomas – Breslow thickness " 1 mm).

MATERIAL AND METHODS

This cross-sectional study analyzed dermoscopic images of 219 melanocytic lesions (56 common compound nevi, 79 atypical nevi, 40 *in situ* melanomas and 44 thin melanomas – all superficial spreading melanomas) from 137 patients. The images were created using a digital imaging device (Fotofinder dermoscope® TeachScreen Software, Bad Birnbach, Germany) from 2003–2010 at the Cutaneous Oncology Department of Hospital A. C. Camargo in São Paulo, Brazil. Lesions with a histopathologic diagnosis confirming either melanoma or nevi from the anatomy pathology archives (those with histopathologic confirmation) and nevi that changed following long-term (6–12 months) digital monitoring (and hence diagnosed as doubtful nevi), which were of a good quality and were inside the full field of view (13.00 x 9.75 cm) were included in this study. Lesions on the scalp, face, and palmoplantar regions were excluded. The lesions were then described by two observers trained in dermoscopy (MAM and GGR), who were blinded as to the diagnosis, using the following dermoscopic features:^{9,10} regular pigmented network; irregular pigmented network; black dots; brown globules; scar-like depigmentation; multiple colors (>3 colors); pseudopods; radial streaming (RS); hyperpigmentation/blotch; hypopigmentation; vascular structures (VS); blue hue (BH); multiple blue-grey dots (peppering); and negative network. The blue hue was defined as a whitish-blue veil and/or diffuse blue homogeneous areas.^{11,12} The variety of vessels considered were: arborizing, dotted, linear-irregular, comma, polymorphous/atypical, hairpin, glomerular, crown, milk-red areas and erythema.¹³

All glass slides were diagnosed by an experienced der-

matopathologist (GL). Melanomas were classified according to the institutional protocol of the Department of Anatomical Pathology, following the Brazilian Melanoma Group histopathology consensus.¹⁴ Atypical nevi were diagnosed using major and minor criteria according to Naeyaert and Brochez (2003). Major criteria included atypical proliferation of melanocytes at the basement membrane that extended over at least 3 rete ridges beyond the dermal component and intraepidermal lentiginous or epithelioid melanocytic proliferation with focal atypia. Minor criteria included concentric eosinophilic fibrosis surrounding rete ridges or lamellar fibroplasia, neovascularisation, dermal inflammatory response and fusion of rete ridges. Nevi were designated atypical if they had at least two major and two minor criteria.¹⁵

The study population was analyzed using descriptive statistics. The comparative analysis between the dependent (dermoscopic features) and independent (doubtful nevi and thin melanomas) variables was conducted using the chi-squared test. The comparative analysis between dependent variables used the multiple binary logistic regression model. The Hosmer-Lemeshow test was used to validate adherence to the model.

RESULTS

The median age of the 137 patients was 45 years; the majority were males (53.3%) with pale skin (92.0%). Of the 219 studied melanocytic lesions, 56 were common compound nevi, 79 were atypical nevi, 40 were *in situ* melanomas and 44 were thin melanomas (median Breslow thickness = 0.53 mm).

Analysis of the Dermoscopic Findings between Nevi and Melanoma

The chi-squared test showed high significance for the following parameters: the presence of a regular pigmented network ($p = 0.005$), the presence of an irregular pigmented network ($p = 0.013$), the presence of scar-like depigmentation ($p = 0.000$), the presence of pseudopods ($p = 0.220$), the presence of radial streaming ($p = 0.000$), the presence of hyperpigmentation ($p = 0.053$), the presence of vascular structures ($p = 0.000$) and the presence of a blue hue ($p = 0.000$) (Table 1).

The chi-squared test showed no significance for the following parameters: the presence of black dots ($p = 0.166$), the presence of multiple colors ($p = 0.400$), the presence of peppering ($p = 0.340$) and the presence of a negative network ($p = 0.914$).

MULTIPLE BINARY LOGISTIC REGRESSION MODEL

The multiple binary logistic regression model was used to examine factors that were statistically significant in the univariate analysis, considering both nevus and melanoma lesions as dependent variables. Based on the odds ratio of the variables that were statistically significant in the logistic regression, a final model was developed (Table 2). In the final model, three dermoscopic features were used: radial streaming, blue hue and vascular structures (Figure 1).

- Absence of all three features: 80.8% were nevi and 19.2% were melanomas (Figure 2).

Table 1. Comparative analysis of dermoscopic findings between nevus and melanoma

Dermoscopy	Category	Nevus N° (%)	Melanoma N° (%)	Total	P value
Regular pigmented network	No	95 (56.5)	73 (43.5)	168	0.005
	Yes	40 (78.4)	11 (21.6)	51	
Irregular pigmented network	No	43 (75.4)	14 (24.6)	57	0.013
	Yes	92 (56.8)	70 (43.2)	162	
Black dots	No	56 (67.5)	27 (32.5)	83	0.166
	Yes	79 (58.1)	57 (41.9)	136	
Brown globules	No	61 (70.1)	26 (29.9)	87	0.036
	Yes	74 (56.1)	58 (43.9)	132	
Scar-like depigmentation	No	121 (67.6)	58 (32.4)	179	0.000
	Yes	14 (35.0)	26 (65.0)	40	
Multiple colors	No	17 (54.8)	14 (45.2)	31	0.400
	Yes	118 (62.8)	70 (37.2)	188	
Pseudopods	No	134 (62.9)	79 (37.1)	213	0.220
	Yes	1 (16.7)	5 (83.3)	6	
Radial streaming	No	128 (67.7)	61 (32.3)	189	0.000
	Yes	7 (23.3)	23 (76.7)	30	
Hyperpigmentation/blotch	No	93 (66.4)	47 (33.6)	140	0.053
	Yes	42 (53.2)	37 (46.8)	79	
Hypopigmentation	No	93 (68.9)	42 (31.1)	135	0.005
	Yes	42 (50.0)	42 (50.0)	84	
Vascular structures	No	110 (69.2)	49 (30.8)	159	0.000
	Sim	25 (41.7)	35(58.36)	60	
Blue hue	No	126(72.0)	49(28.0)	175	0.000
	Yes	9(20.5)	35(79.5)	44	
Peppering	No	78 (64.5)	43(35.5)	121	0.340
	Yes	57(58.2)	41(41.8)	98	
Negative network	No	118(61.8)	73(38.2)	191	0.914
	Yes	17(60.7)	11(39.3)	28	
TOTAL		135 (61.6)	84 (38.4)	219	

- Presence of one dermoscopic feature: 50.7% were nevi and 49.3% were melanomas.
- Presence of two dermoscopic features: 12% were nevi and 88.0% were melanomas.
- Presence of three dermoscopic features: 100% were melanomas (Figure 3).

The sensibility of the final model using the three features was 100% and the specificity was 80%.

DISCUSSION

This study was motivated by the lack of a useful dermoscopic algorithm to help dermatologists examine doubtful melanocytic lesions in their daily practice. Although this study presented a final model based on dermoscopic features that have already been described for malignancy diagnosis, including pattern analysis, ABCD rule, 7-point checklist, and Menzies method, it introduced a new approach. The presence of radial streaming, blue hue or vascular structures was sufficient to diagnose melanoma. Interestingly, in the absence of these three features a lesion was highly likely to be a nevus, whereas in the presence of the three features, it was certainly a melanoma. Thus this model can be a useful tool to help decide whether a surgical excision is required.

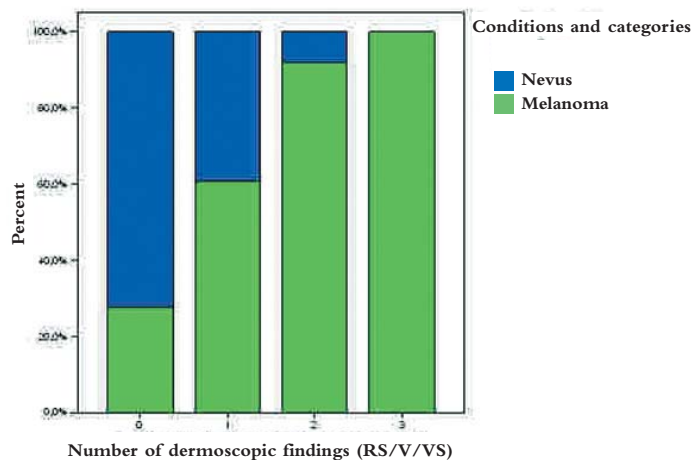
RADIAL STREAMING

Radial streaming was characterized dermoscopically by radial and parallel linear strands at the periphery of the lesion, which are frequently seen in melanoma (irregularly distributed) and Reed nevus (regularly distributed all around the periphery).^{16,17,18} Histologically, it is characterized by confluent nests of pigmented melanoma cells toward the periphery.^{16,18} The neoplastic cells were confined to the epidermis, in agreement with the concept that these dermoscopic features are associated with melanoma’s radial growth phase. Our group described this feature in transverse sections, where it consisted of pigmented neoplastic melanocytes distributed in a radial arrangement outlining the parallel lines seen on dermoscopy, resembling the treelike pattern proposed by Kenet and others.⁶ Argenziano and co-workers hypothesized a sequence of events in the melanoma lesions: the enlargement of the pigmented network (broadened network) followed by centrifugal melanoma proliferation (radi-

Table 2. Final multiple logistic regression model

Dermoscopy	Category	O Raj	P value
Radial streaming	Não	(baseline)	0.003
	Sim	4.6	
Vascular structure	Não	1.0	< 0.001
	Sim	3.7	
Blue hue	Não	1.0	< 0.001
	Sim	7.7	

Hosmer-Lemeshow test: 0.890



Graphic 1: Final model

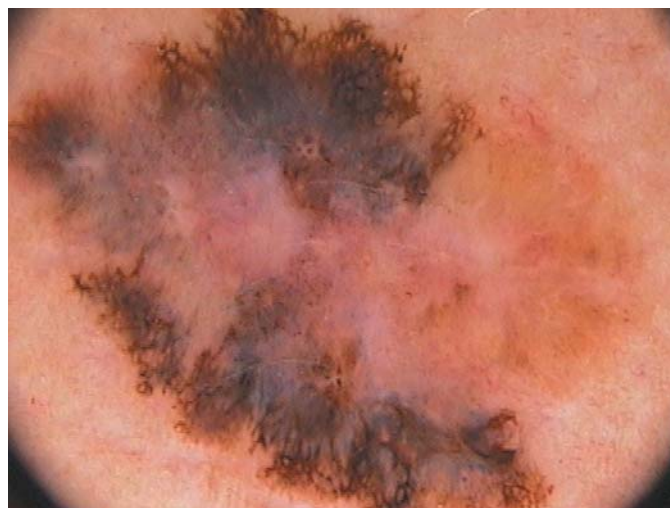

Figure 3: Dermoscopy (10X) of cutaneous melanoma showing the presence of all three features (RS, V and VS)

al streaming and pseudopods).¹⁹ Panasiti and colleagues showed the importance of the pigment network for diagnosing benign and malignant melanocytic lesions and called the radial streaming “linear extensions.”²⁰ They observed that this criterion was not only strongly related to the histopathological diagnosis of melanoma but also to dysplastic nevus.²⁰

In this study, radial streaming was present in 23 melanomas and 5 atypical nevi out of 30 melanocytic lesions with this feature. Our data confirmed that radial streaming is strongly related to melanoma lesions, but can also be found in atypical nevi lesions.

BLUE HUE

The blue hue is frequently found in melanoma lesions and is characterized dermoscopically as a blue-white veil (an irregular, structureless area of confluent blue pigmentation with an overlying white “ground-glass” film) and blue areas (diffuse

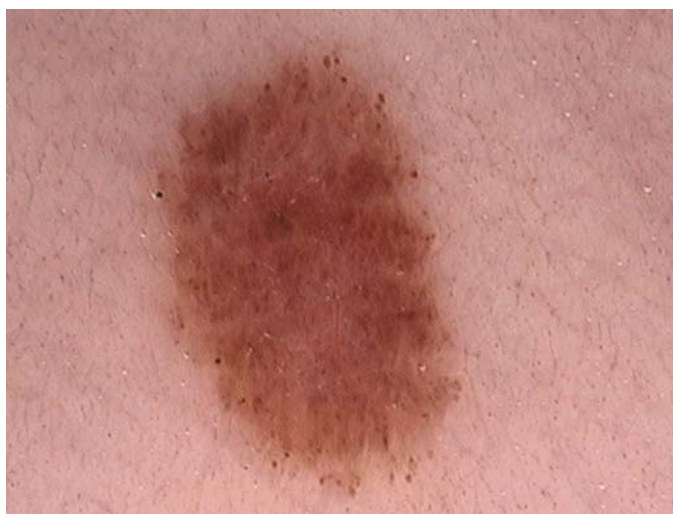

Figure 2: Dermoscopy (10X) of compound nevus showing none of the three features (RS, V and VS)

blue-gray pigmentation).^{11,12} The whitish blue veil is histologically defined as the presence of a compact orthokeratosis overlying large amounts of melanin in the dermis. Such melanin was found not only within compact aggregates of melanocytes but also in clusters of melanophages in the dermis.^{16,21,22} Conversely, the blue areas are related to the presence of a fibrosis and melanin pigment, either within melanophages or within pigmented melanocytes in the superficial dermis. In 2001 De Giorgi and colleagues described the difference between whitish blue veil and blue areas (blue homogeneous pattern); the former occur frequently in melanomas and the latter in benign lesions such as blue nevi.²³ These authors published a case of melanoma in 2003 that presented dermoscopically a blue hue characterized as a “homogeneous blue pigmentation” (pathognomonic of blue nevus), and histopathologically presented an epidermal orthokeratosis and a extensive regression phenomena in the dermis. It has demonstrated that occasionally the whitish blue veil and blue areas are mistakenly recognized. In addition, in the Consensus Net Meeting on Dermoscopy, the whitish blue veil did not exhibit sufficient interobserver reproducibility.¹⁰ In our study, a blue hue was present in 44 melanocytic lesions out of 219. The correlation was significant ($p < 0.000$): 79.5% (35 out of 44) of all pigmented lesions with a blue hue were melanomas. Pellacani and colleagues described the presence of a blue hue in 66.7% of melanomas and in 24% of acquired nevi, confirming that the presence of a blue hue suggests a melanoma diagnosis.¹² Among nevi lesions, we found four compound nevi and five atypical nevi with this feature. Thus, we believe a blue hue may be considered a single dermoscopic parameter (whitish blue veil and/or blue areas) and could help improve the accuracy of malignancy diagnoses.

VASCULAR STRUCTURES

The vascular structures in dermoscopy are due to the presence of hemoglobin in the vessels within the dermis, and they can assume different morphologies on dermoscopic examina-

tion. The recognition of distinctive vascular structures may help achieve a correct diagnosis, especially when classic pigmented dermoscopic structures are lacking.¹³ This finding is considered a strong sign of malignancy.²⁴ Our study showed that the presence of vascular structures occurred in almost 60% of the lesions, and it was statistically significantly associated with melanomas ($p < 0.001$). Argenziano and colleagues found the linear-irregular pattern the most common vascular structure in melanoma, exhibiting a positive value of 67.6% ($p = 0.001$).¹³ In contrast, we observed that the predominant type was the milky-red area that was considered by Braun and co-workers to be a predictive factor for melanoma.²⁵ The milky-red area is also known as a pink veil; it is dermoscopically defined as a pink area, ill defined within or at the periphery of the lesion.²⁵ In this study, 50% of lesions with this feature were melanomas. Interestingly, only three melanocytic nevi presented comma and/or crown vessels, while the remaining nevi presented milky-red areas (6 nevi), polymorphic irregular vessels (1 nevus) and glomerular vessels (1 nevus). Of the atypical nevi, 12 presented milky-red areas and two had polymorphic irregular vessels. Argenziano and co-workers interpreted erythema as a single vascular structure in a Clark nevus with a predictive value of 42.7%; the difference between the later and melanoma was statistically significant ($p = 0.001$).¹³ Thus, we believe that the presence of vascular structures can indicate suspected lesions.

CONCLUSION

The final model showed a good specificity using three features for diagnosing melanomas (100%) and good specificity (80%). Thus it can be considered a useful tool for deciding whether surgical excision is required. In addition, we believe that further studies are necessary to distinguish difficult benign melanocytic lesions from melanomas; *in vivo* confocal reflectance microscopy could be helpful. ●

ACKNOWLEDGMENTS

We would like to thank Dr. Gilles Landman for the histopathologic assessment and Dr. Bianca Costa Soares de Sá and Dr. Harold Rabinovitz for their critical review of the manuscript.

REFERENCES

- Rahnama Z, Meymandi SS, Nasiri N. Cutaneous melanoma in a desert climate zone: a retrospective study of 125 cases. *Int J Dermatol*. 2010;49(4):406-9.
- Miller AJ, Mihm MC Jr. Melanoma. *N Engl J Med*. 2006;355(1):51-65.
- Bafounta ML, Beauchet A, Aegerter P, Saiag P. Is dermoscopy (epiluminescence microscopy) useful for the diagnosis of melanoma? Results of a meta-analysis using techniques adapted to the evaluation of diagnostic tests. *Arch Dermatol*. 2001; 137(10):1343-50.
- Menzies SW, Gutenev A, Avramidis M, Batrac A, McCarthy WH. Short-term digital surface microscopic monitoring of atypical or changing melanocytic lesions. *Arch Dermatol* 2001; 137(12):1583-9.
- Haenssle HA, Krueger U, Vente C, Thoms KM, Bertsch HP, Zutt M. Results from an Observational Trial: Digital Epiluminescence Microscopy Follow-Up of Atypical Nevi Increases the Sensitivity and the Chance of Success of Conventional Dermoscopy in Detecting Melanoma. *J Invest Dermatol* 2006;126(5):980-5.
- Rezze GG, Scramim AP, Neves RI, Landman G. Structural Correlations Between Dermoscopic Features of Cutaneous Melanoma and Histopathology Using Transverse Sections. *Am J Dermatopathol*. 2006;28(1):13-20.
- Puig S, Argenziano G, Zalaudek I, Ferrara G, Palou J, Massi D, et al. Melanomas that failed dermoscopic detection: a combined clinicodermoscopic approach for not missing melanoma. *Dermatol Surg*. 2007;33(10):1262-73.
- Scope A, Dusza SW, Halpern AC, Rabinovitz H, Brawn RP, Zalaudek I, et al. The "Ugly Ducking" Sign. *Arch Dermatol*. 2008; 144(1):58-64.
- Malvehy J, Puig S, Argenziano G, Marghoob AA, Soyer HP; International Dermoscopy Society Board members. Dermoscopy report: proposal for standardization: results of a consensus meeting of the International Dermoscopy Society. *J Am Acad Dermatol* 2007; 57(1):84-95.
- Argenziano G, Soyer HP, Chimenti S, Talamini R, Corona R, Sera F, et al. Dermoscopy of pigmented skin lesions: results of a consensus meeting via the Internet. *J Am Acad Dermatol*. 2003;48(5):679-93.
- De Giorgi V, Massi D, Trez E, Salvini C, Quercioli E, Carli P. Blue hue in the dermoscopy setting: homogeneous blue pigmentation, gray-blue area, and/or whitish blue veil? *Dermatol Surg*. 2003;29(9):965-7.
- Pellacani G, Bassoli S, Longo C, Cesinaro AM, Seidenari S. Diving into the blue: in vivo microscopic characterization of the dermoscopic blue hue. *J Am Acad Dermatol*. 2007;57(1):96-104.
- Argenziano G, Zalaudek I, Corona R, Sera F, Cicale L, Petrillo G, et al. Vascular structures in skin tumors: a dermoscopy study. *Arch Dermatol*. 2004;140(12):1485-9.
- Landman G, Muller H, Fillus Neto J, Maceira JMP, Marques M, Costa MB, et al. Consenso para o laudo anatomopatológico do melanoma cutâneo. Grupo Multicêntrico e Multidisciplinar Brasileiro para Estudo do Melanoma (GBM)/ Pathology report consensus for cutaneous melanoma. Brazilian Multicentric and Multidisciplinary Group for the Study of Melanoma (GBM). *Acta Oncol Bras*. 2003;23(3): 504-10.
- Naeyaert JM, Brochez L. Clinical practice: dysplastic nevi. *N Engl J Med*. 2003; 349(23):2233-40.
- Menzies SW, Crotty KA, McCarthy WH. The morphologic criteria of the pseudopod in surface microscopy. *Arch Dermatol*. 1995;131(4):436-40.
- Katz B, Rabinovitz HS. Introduction to dermoscopy. *Dermatol Clin*. 2001; 19(2):221-58.
- Kenet RO, Kang S, Kenet BJ, Fitzpatrick TB, Sober AJ, Barnhill RL. Clinical diagnosis of pigmented lesions using digital epiluminescence microscopy: grading protocol and atlas. *Arch Dermatol*. 1993;129(2):157-74.
- Argenziano G, Fabbrocini G, Carli P, De Giorgi V, Delfino M. Epiluminescence microscopy: criteria of cutaneous melanoma progression. *J Am Acad Dermatol*. 1997; 37(1):68-74.
- Panasiti V, Devirgillis V, Curzio M, Roberti V, Gobbi S, Masciangelo R, et al. The reticular point of view in dermoscopy. *J Am Acad Dermatol* 2009; 61(4):605-10.
- Nachbar F, Stolz W, Merkle T, Cognetta AB, Vogt T, Landthaler M, et al. The ABCD rule of dermatoscopy. High prospective value in the diagnosis of doubtful melanocytic skin lesions. *J Am Acad Dermatol*. 1994;30(4):551-9.
- Massi D, De Giorgi V, Carli P, Santucci M. Diagnostic significance of the blue hue in dermoscopy of melanocytic lesions: a dermoscopic-pathologic study. *Am J Dermatopathol*. 2001; 23(5):463-9.
- Braun RP, Rabinovitz H, Tzu JE, Marghoob AA. Dermoscopy research--an update. *Semin Cutan Med Surg*. 2009;28(3):165-71.