

Photodynamic therapy with methyl aminolevulinate hydrochloride for actinic keratosis and non-melanocytic cutaneous neoplasia

Experiência na terapia fotodinâmica com cloridrato de aminolevulinato de metila para queratose actínica e neoplasia cutânea não melanocítica

ABSTRACT

Introduction: Photodynamic therapy uses photochemical substances that selectively impregnate abnormal tissue and act as a sensitizing agent for the light.

Objective: To evaluate the clinical response, aesthetic results and side effects of applying photodynamic therapy using the photosensitizer methyl-aminolevulinate hydrochloride in actinic keratosis lesions, basal cell carcinomas, and Bowen's disease.

Methods: After removing scales or crusts and impregnating the lesion with methyl-aminolevulinate hydrochloride, 632 nm (37 j/cm²) red light radiation was applied, at a distance of 5 to 8 cm from the skin, for 8 minutes.

Results: 102 patients (59 with actinic keratosis, 32 with basal cell carcinoma, and 11 with Bowen's disease) were studied. After 12 weeks, only 14 patients (6 actinic keratosis, 6 basal cell carcinoma, and 2 Bowen's disease) had incomplete results. The treatment yielded excellent aesthetic results. The main complications were 1 case of severe erythema and 1 case of important pustules and edema.

Conclusions: Consistent with the literature, this study confirms the efficacy of photodynamic therapy with methyl-aminolevulinate hydrochloride in the treatment of actinic keratosis lesions and non-melanocytic cutaneous neoplasias, with similar recurrence rates and better aesthetic results than conventional therapies.

Keywords: photochemotherapy; keratosis, actinic; carcinoma, basal cell.

RESUMO

Introdução: A terapia fotodinâmica (TFD) é uma opção de tratamento baseada na utilização de substâncias fotoquímicas que, ao impregnarem seletivamente o tecido anormal, agem como sensibilizadores para a atuação de radiação luminosa.

Objetivos: Avaliar a resposta clínica, o resultado estético e efeitos colaterais da aplicação de TFD utilizando o fotosensibilizante cloridrato de aminolevulinato de metila (MAL) em lesões de queratose actínica (QA), carcinoma basocelular (CBC) e doença de Bowen (DB).

Métodos: Após remoção de escamas ou crostas e impregnação da lesão com MAL, foi realizada a exposição à radiação de luz vermelha de 632nm (37 j/cm²), por 8 minutos, entre 5 e 8 cm de distância da pele.

Resultados: Foram analisados 102 pacientes, sendo que 59 eram portadores de QAs, 32 de CBC e 11 de DB. Houve resposta completa na maioria dos pacientes após 12 semanas, excetuando-se 14 pacientes: 6 com QA, 2 com DB, 6 com CBC. O tratamento demonstrou excelente resultado estético. As principais complicações foram 1 caso de eritema severo e 1 de pústulas e edema importantes.

Conclusões: O presente trabalho, em consonância com a literatura, confirma a eficácia da TFD-MAL no tratamento de lesões de QA e neoplasias cutâneas não melanocíticas (NcNM), com semelhantes taxas de recidiva e melhores resultados estéticos em comparação com as terapias convencionais.

Palavras-chave: Terapia Fotodinâmica; Cloridrato de Aminolevulinato de Metila; Queratose Actínica; Carcinoma Basocelular

Palavras-chave: terapia fotodinâmica; queratose actínica; carcinoma basocelular

Original Article

Autores:

Luiz Eduardo Garcia Galvão¹
Heitor de Sá Gonçalves²
Antônio Renê Diógenes de Sousa³
Leonardo Augusto Coelho Torres da Silva⁴
Iana Siqueira de Almeida⁵

¹ Dermatologist Physician and Head, Photodynamic Therapy Outpatient Clinic, Centro de Dermatologia Dona Libânia – Fortaleza (CE), Brazil

² Dermatologist Physician, Coordinator and Instructor of Dermatology, Universidade Estadual do Ceará (UFC) – Fortaleza (CE) and General Director, Centro de Dermatologia Dona Libânia

³ Dermatologist Physician, Coordinator and Instructor of Dermatology, Universidade Estadual do Ceará (UFC) and Dermatology Medical Residency Coordinator, Centro de Dermatologia Dona Libânia

⁴ Dermatology Resident Physician, Centro de Dermatologia Dona Libânia

⁵ Medicine academician, Universidade Estadual do Ceará (UEC)

Correspondence:

Dr Leonardo Augusto Coelho Torres da Silva
Rua Nunes Valente, 981/602 – Aldeota
60125-070 – Fortaleza - CE, Brasil
e-mail: sadamits@terra.com.br

Received on: 15/08/2010

Approved on: 15/11/2010

This study was carried out at the Centro de Dermatologia Dona Libânia – Fortaleza (CE), Brazil.

Financial support: none
Conflicts of interest: none

INTRODUCTION

Actinic keratosis (AK) and non-melanoma skin cancer lesions, such as Bowen's disease (BD) and superficial and nodular basal cellular carcinomas (BCC), are the most common malignant neoplasias in the world, particularly in the Caucasian population. These types of lesions account for more than 1/3 of all cancers in the United States, with approximately 900,000 to 1.2 million new cases per year.¹ Such lesions present a good prognosis when treated early, since BCC – the most common non-melanocytic cutaneous neoplasia (NMCN) – rarely metastasizes, although it can be locally invasive if it is not treated. On the other hand, since squamous cell carcinoma (SCC) – which can develop from AK or BD lesions (in situ SCC) – can metastasize, all cases of AK and BD must be treated.²

Photodynamic therapy (PDT) uses a light source to activate a topical photosensitizer that has a high selectivity for the affected tissue (NCNM in this case). A 20% 5-aminolevulinic acid solution (5-ALA) was the first broadly used product to treat AK (initially in the United States) from the 1990s. It was used on the skin, with 14-hour incubation periods (later reduced to 1 hour) with sources of blue light (415 nm).³ European research also focused on the treatment of BCCs, with the development of methyl aminolevulinate hydrochloride (MAL) in cream, to be exposed to the skin for 3 hours, using a 632 nm red light.⁴ Both 5-ALA and MAL produce photoactive porphyrins with selectivity to the neoplastic tissue, causing necrosis and apoptosis following illumination.⁵⁻⁸

There are few studies in the literature comparing 5-ALA and MAL. MAL, however, is more lipophilic, and thus has greater penetration and could also be used in NCNM. Additionally, the treatment protocol for MAL is more standardized than that of 5-ALA, which uses several sources of light or adjuvant treatments (5-fluorouracil and dermabrasion before the sessions, for instance). Moreover, MAL uses red light with longer wavelengths, allowing a more effective penetration of the photosensitizer.

This study's objective was to evaluate clinical and aesthetic responses and the more common side effects in patients who were treated with PDT-MAL sessions for facial AKs, superficial and nodular BCCs (less than 2 mm deep in the histological analysis and BD).

MATERIALS AND METHODS

A prospective observational study was developed, following the ethical recommendations of the Declaration of Helsinki (2000), to include consecutive patients who sought care spontaneously at the Centro de Referência em Dermatologia Sanitária Dona Libânia in Fortaleza, Brazil. Patients had AK facial lesions, superficial or nodular BCCs less than 2mm deep, and BD (Graph 1). The selection criteria included the regular use of wide spectrum anti-UVA/UVB sunscreen and unsuccessful previous cryotherapy or 5-fluorouracil treatments for AK patients.

Skin scales were removed prior to the treatment by curettage or gauze soaked in 0.9% saline solution, without anesthe-

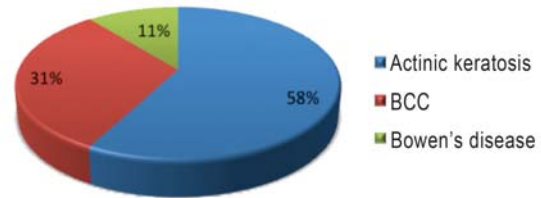


Gráfico 1: Porcentagens das lesões

sia. Hemostasis was carried out using compression only; the use of aluminium chloride solution or electrocoagulation was avoided, in order to prevent interference in the penetration of the MAL. A thick layer of MAL (Metvix®Galderma, Br) was then applied on the lesion or area to be treated, and was covered by transparent PVC plastic film (Figure 1); aluminium foils resembling curative masks were affixed with adhesive micropored plaster (Figure 2).

After 2.5 to 3 hours, the curative mask was taken off and the MAL was removed with 0.9% saline solution. The treated area was immediately subjected to illumination with a 632 nm and 37 j/cm² source of red light (Aktilite® CL128 Galderma, Br), positioned 5 to 8 cm from the treated area, for 8 minutes.

RESULTS

Patients (n = 102) included 59 with AK (58%), 32 with BCC (31%), and 11 with BD (11%). The 59 patients with facial AKs had one PDT-MAL session and were evaluated for clinical and aesthetic results after 12 weeks. The aesthetic result was considered satisfactory when the patient presented photorejuvenation with improvement of solar melanosomes, telangiectasias and thin wrinkles. All patients presented satisfactory aesthetic results and a decrease in the number of AKs. Six patients needed one additional session after 12 weeks, due to an incomplete result (Graph 2 / Figures 3 and 4).

Of the 32 BCC patients who were treated with PDT-MAL, all except 6 presented a histological cure and excellent aesthetic results after the treatment (Graph 3 / Figures 5 and 6). Of the remaining,⁶ 1 had superficial extensive facial BCC, ² had Gorlin syndrome, and 3 had BCC lesions in the "H" area of the face (perioral, perinasal and periorbital areas). The 11 BD

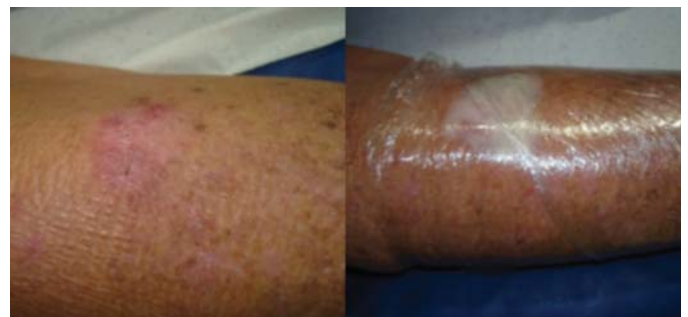

Figure 1: Bowen's disease before and after the application of a thick layer on the lesion.

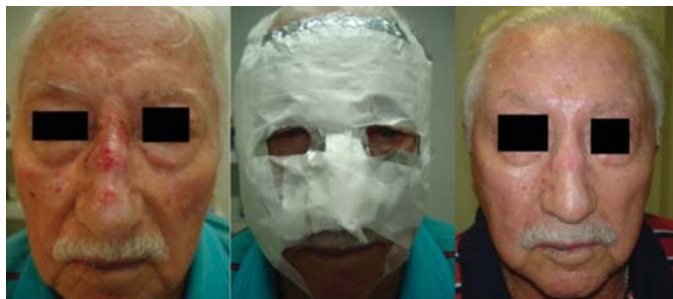

Figure 2: Occlusive curative in 90-year-old AK patient who underwent PDT-MAL in the whole face (before and 12 weeks after the procedure).

patients had 13 lesions treated with 2 PDT-MAL sessions with a 7-day interval. The lesions persisted in two patients after 12 weeks. The remaining patients presented a clinical and histological cure with excellent aesthetic results (Graph 4 / Figure 7).

All patients reported sensibility to pain during the procedure; the interruption of the illumination was necessary in only 2 cases. Several strategies were employed to minimize pain during the sessions: oral analgesic 1 hour before the use of the red light, cooling spray, thermal water, cooled saline solution compresses applied directly on the treated area during the entire period of illumination, and increasing the distance from the light bulb to the skin to 8 cm.⁹ A higher correlation of pain sensibility – which was directly proportional to the extent of the treated area (and, in the case of AKs, to the number of lesions) – was observed in male patients. The area most sensitive to the treatment was the scalp in bald men, followed by the frontal region in both genders.

An additional side effect observed was erythema, light or moderate in most cases, which was treated with emollients. It was severe in only one case, and required the use of a topical corticosteroid. Crusts and desquamation were commonly observed, while pustules and significant edema were observed in one female patient (Figure 8).

DISCUSSION

AKs are the most common premalignant cutaneous lesions; they are frequently multiple and occur in exposed areas such as the face, scalp and upper limbs. Since 5–20% of these lesions will become SCCs in 10 to 25 years, and there is no way to tell which lesions will become malignant, it is necessary to treat all AKs.^{10,11}

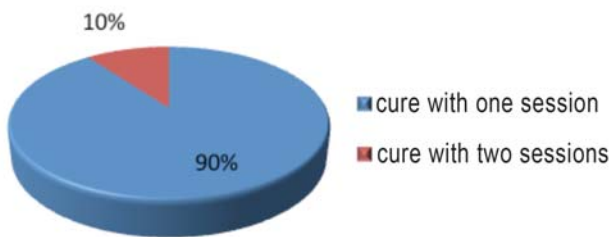


Gráfico 2: Cura x Número de sessões de pacientes com QA

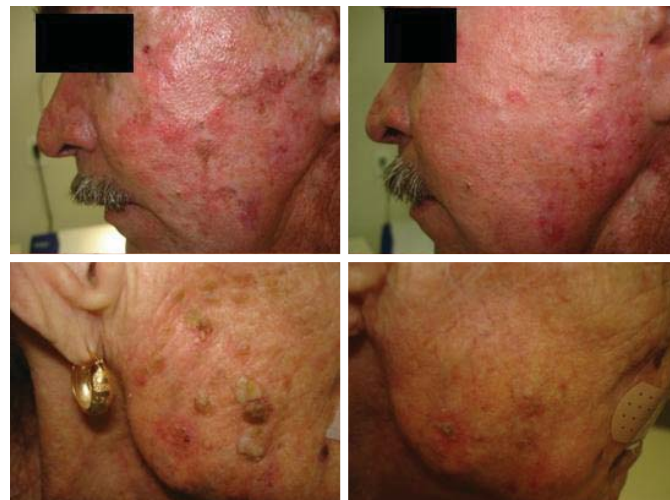

Figure 3: Patients with multiple facial AKs who underwent 1 PDT-MAL session and saw a decrease in the AK, but had to repeat the procedure after 12 weeks in spite of the clinical improvement and excellent aesthetic results.

Tarstedt and colleagues demonstrated that one PDT-MAL session (repeated after 3 months if the lesions persisted), was as effective as the initial treatment plan of two sessions with a one-week interval.¹² Facial AKs respond better to PDT-MAL due to the lower hyperkeratosis that they present compared to similar lesions when located in the acral segments. The use of PDT-MAL is limited by the sensitivity to pain, which is directly proportional to the following patient characteristics: male gender, location on bald men's scalps, frontal region in both genders and multiple and extensive lesions on the face.⁹ Due to such factors, we chose to carry out one session on each side of the face, with a one-week interval, in addition to taking several measures (discussed above) to minimize pain.⁹

Other many times minimized however fundamental aspects in the PDT-MAL for facial AKs, would be: the curettage

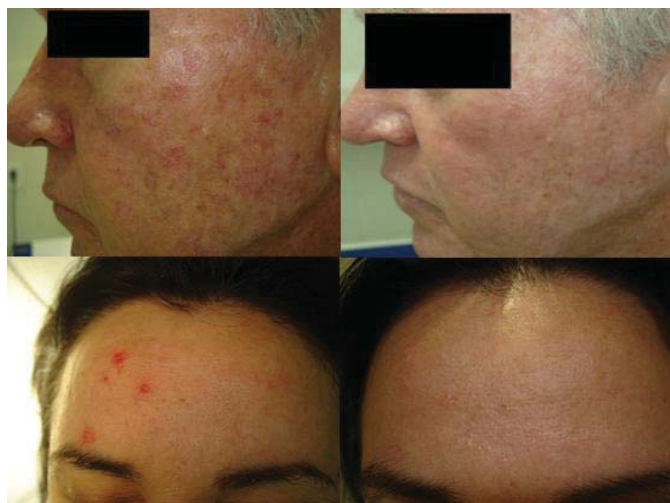

Figure 4: Patients with multiple facial AKs who underwent 1 PDT-MAL session with excellent aesthetic results.

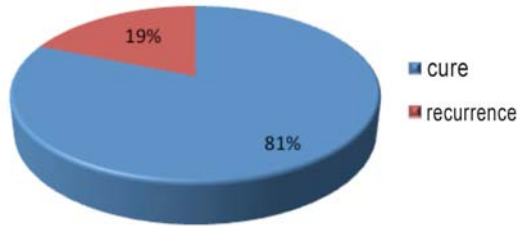


Gráfico 3: Cura x Recidiva de pacientes com CBC

of the larger and more hyperkeratotic lesions with the application of a thick layer of medication after compression with gauze, with the subsequent preparation of the occlusive curative with transparent PVC plastic film, carefully applied on the area to be treated in order to avoid removing the MAL applied to the lesions.

We verified a complete response to PDT-MAL from practically all patients with facial AK, with only six cases undergoing a new session after 12 weeks. One of the patients who presented only a partial resolution of AKs after the initial treatment had many lesions disseminated throughout the face; the others presented extensive lesions. Nevertheless, all presented great improvement and tolerance to the treatment, and were satisfied with a partial response.

Even though we obtained a good response to the treatment of AKs located in the dorsum, cervical region, and upper and lower limbs, this procedure's high cost does not seem justified for treating those locations compared to the results obtained with conventional treatments. Therefore, PDT-MAL seems to be a more appropriate method for facial AKs in patients who have already had other treatments such as 5-fluorouracil and cryotherapy, as much for the high clinical response (around 90% in the literature^{12,13,14}) as for the photorejuvenation provided.

The pain during the 8 minutes of the session can be a limiting factor. We believe that performing the treatment in two stages (right and left sides of the face, with a one-week interval), in addition to taking measures to relieve the pain and having a good physician-patient relationship, can alleviate this side effect.⁹ In our study sample, erythema and edema did not cause significant discomfort, except in two patients (one of them developed pustules). In these cases, the problem was solved with the use of emollients and corticosteroid creams.

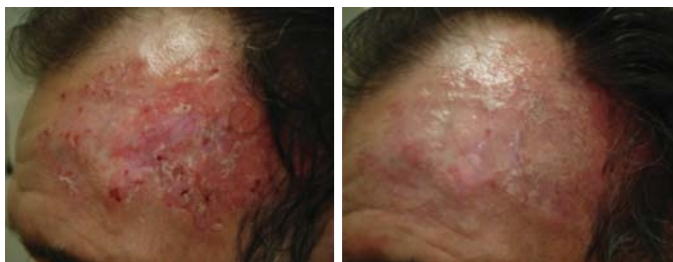

Figure 5: Superficial BCC in the frontal region, with partial response after 2 PDT-MAL sessions; despite the clinical improvement, there was no histological cure, having undergone a third session after 12 weeks.

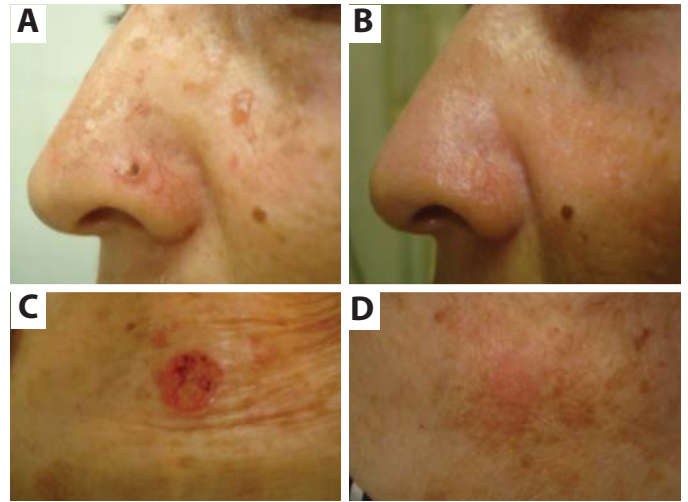


Figure 6: A/B: 37-year-old patient with 2 superficial BCC lesions in the left nasal wing and keratoses and solar melanoses in the malar region, before and after 2 PDT-MAL sessions. Complete resolution of lesions with excellent aesthetic results. C /D: 90-year-old patient with BCC. Complete resolution of lesions with excellent aesthetic results.

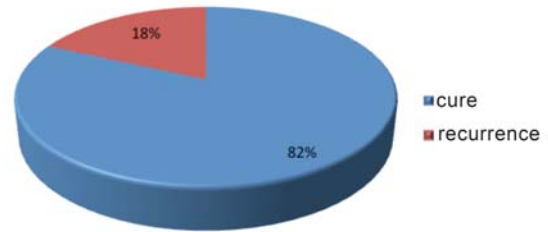


Gráfico 4: Cura x Recidiva de pacientes com DB

BD lesions constitute in situ SCC and typically occur in senior patients' lower limbs (though they can occur in any cutaneous region), with around 3% of such lesions evolving into SCCs 15, of which 1/3 metastasize.¹⁶ Despite the fact that PDT-MAL for BD is still used "off-label" in Brazil, it has been approved in 22 European Union countries. In a multicentric study with 2 PDT-MAL sessions administered in 7 days in cases of BD, the initial cure rate was 93%¹⁷. In a 12-month follow-up, the recurrence rate under PDT-MAL was 15%, compared to 21% for cryotherapy and 17% for 5-Fluouracil.¹⁷

In the present study, 2 sessions of PDT-MAL were carried out to treat 11 lesions in patients aged 51-96 – most of them elderly and with co-morbidities. All lesions were located in the upper and lower limbs and dorsum, areas that are difficult to heal. After the end of treatment, in a follow-up that varied from six to twelve months, only two patients with lesions located in the dorsum did not present a histological cure after 12 weeks. One possible explanation is that the second session was carried out only 14 days after the initial session, since the patients were absent on the day scheduled for the treatment.

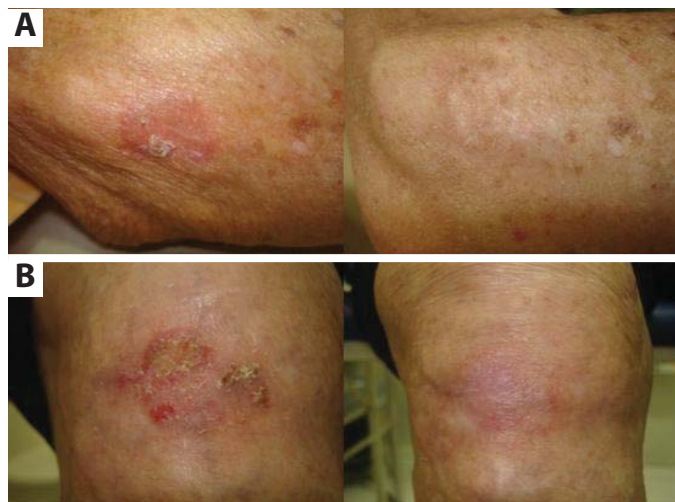


Figure 7: Results after 2 PDT-MAL sessions. A: Lesion on right forearm of 72-year-old patient with non-Hodgkin Lymphoma. B: Bowen's disease on knee of 90-year-old woman with Alzheimer's disease.

BCC lesions are the most common cutaneous neoplasias. They can be superficial (sBCC) or nodular (nBCC), pigmented or sclerodermiform. Primary BCCs located outside the "H" zone of the face can be classified as low risk, a circumstance in which both the aesthetic result and the antitumoral efficacy are important. In general, BCCs also affect a younger age group or occur as multiple lesions in tegument areas subjecting to dystrophic scars.

There is considerable evidence to support the use of PDT-MAL in BCCs, including several phase III studies that demonstrate high histologically confirmed efficacy (80%) in 3 months for large or recurrent lesions, or those located in the H zone of the face.^{18,19} In a four-year follow-up, the same studies verified a recurrence rate similar to that of cryotherapy (19%, versus 22% for PDT-MAL),^{20,21} with lower three-year recurrence rates (6%) for lesions with diameters equal to or smaller than 1 cm.²⁰ Vinciullo and others²² and Horn and colleagues²³ showed 36-month recurrence rates of 15% and 31%, respectively, in lesions that were difficult to treat. In spite of the higher recurrence rate of lesions in the H zone of the face, PDT-MAL is effective in the treatment of BCCs, and is a viable alternative when surgery is contraindicated.

We used PDT-MAL in 13 BCC lesions, including a 37-year-old female patient with 2 lesions in the H zone of the face, who demonstrated a complete response with excellent aesthetic results (Figure 7). In that case, the choice of treatment was made after the explanation of the surgical option, which leads to a lower probability of recurrence. Nevertheless, as the patient presented 2 lesions, and multiple keratoses and solar melanoses, there was consensus on the choice for PDT-MAL. The patient was at the 12-month follow-up stage at the time this article was written.

The strongest evidence for the use of PDT-MAL in nBCC is based on 5 phase II studies; a total of 220 lesions were treated, with 73-94% efficacy.²²⁻²⁶ Horn and others²³ and Vinciullo and colleagues²² showed a response rate between 94% and 87%, respectively. Lower rates can occur due to differences in the preparation of the lesion, as explained in the beginning of this article. A recurrence rate of 14% in 3 or 5 years after treatment was verified in a phase III study for nBCC,²⁶ while for difficult lesions, the rate varied between 18 and 30% in 48-60 months.^{22,23} In a retrospective study, the recurrence rate varied between 7% and 14% for thin and thick lesions, respectively,²⁷ also demonstrating the importance of the preparation of the lesion.

Twelve nBCC lesions underwent PDT-MAL, with the clinical response confirmed by histological cure in all cases, at the Centro de Dermatologia Dona Libânia. In our casuistry, we also carried out 2 PDT-MAL sessions in two patients with Gorlin syndrome who presented pigmented nBCC in the retroauricular areas, however the lesions still persisted after 12 weeks, illustrating the difficulty in treating lesions with pigment.

CONCLUSION

PDT-MAL is an effective treatment for AK and NCNM, presenting efficacy and recurrence rates similar to those of conventional therapies, however with higher recurrence than that of surgery in nBCC and sBCC cases. Nevertheless, this method presents the best aesthetic result, and becomes an attractive option for sBCC and nBCC that occur outside of the H zone of the face and in areas of poor healing and lower probability of recurrence, such as the trunk and limbs. Likewise, because of the photorejuvenation entailed by the treatment, it becomes a first line method for facial AKs – especially multiple AKs – in patients with low phototypes or who have already tried lower-

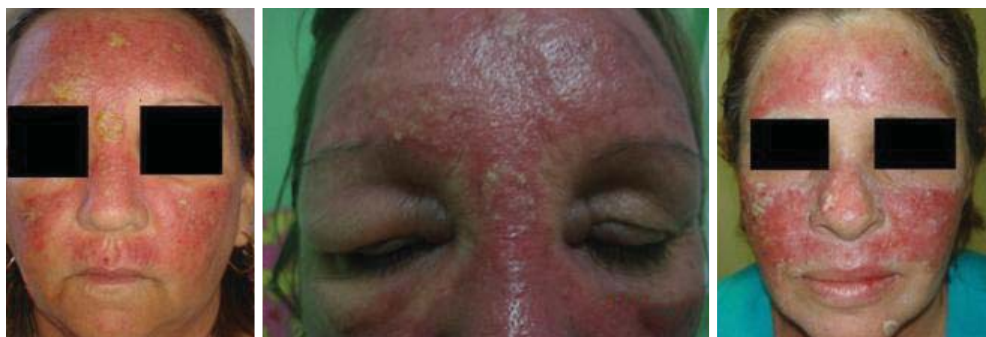

Figure 8: Intense phototoxicity, pustules and edema formation observed 1 week after PDT-MAL session.

cost treatments such as 5-fluorouracil and cryotherapy and have experienced a recurrence of the lesions.

An important limiting factor in the patients' choice for PDT-MAL is the cost of the procedure. In this manner, it is the dermatologist's duty to adequately position the method in terms

of efficacy and recurrence, as compared to other options. It is important to emphasize the lower probability of recurrence with surgical treatment in sBCC and nBCC cases, especially in the H zone of the face, in infiltrated or hyperkeratotic lesions. ●

REFERÊNCIAS

1. Miller DL, Weinstock MA. Nonmelanoma skin cancer in the United States: incidence. *J Am Acad Dermatol*. 1994;30(5 pt 1):774-8.
2. Szeimies RM. Epidemiology of actinic keratosis, squamous cell carcinoma and basal cell carcinoma. Presented at the International Skin Cancer Conference, Zurich, July 22-24, 2004.
3. Alexiades-Armenakas M, Geronemus R. Laser mediated photodynamic therapy of actinic keratoses. *Arch Dermatol*. 2003; 139(10): 1313-20.
4. Angell-Petersen E, Sørensen R, Warloe T, Soler AM, Moan J, Peng Q, et al. Porphyrin formation in actinic keratosis and basal cell carcinoma after topical application of methyl 5-aminolevulinate. *J Invest Dermatol*. 2006;126(2):265-71.
5. Gad F, Viau G, Boushira M, Bertrand R, Bissonnette R. Photodynamic therapy with 5-aminolevulinic acid induces apoptosis and caspase activation in malignant T cells. *J Cutan Med Surg*. 2001;5(1):8-13.
6. Noodt BB, Berg K, Stokke T, Peng Q, Nesland JM. Apoptosis and necrosis induced with light and 5-aminolevulinic acid-derived protoporphyrin IX. *Br J Cancer*. 1996;74(1):22-9.
7. Kuzelova K, Grebenova D, Pluskalova M, Marinov I, Hrkal Z. Early apoptotic features of K562 cell death induced by 5-aminolevulinic acid-based photodynamic therapy. *J Photochem Photobiol B*. 2004;73(1-2):67-78.
8. Webber J, Luo Y, Crilly R, Fromm D, Kessel D. An apoptotic response to photodynamic therapy with endogenous protoporphyrin in vivo. *J Photochem Photobiol B*. 1996;35(3):209-11.
9. Wennberg A-M. Pain relief and other practical issues in photodynamic therapy. *Australas J Dermatol*. 2005;46(Suppl) :S3-4.
10. Marks R, Rennie G, Selwood TS. Malignant transformation of solar keratoses to squamous cell carcinoma. *Lancet*. 1988;1(8589):795-7.
11. Glogau RG. The risk of progression to invasive disease. *J Am Acad Dermatol*. 2000;42(Suppl):S23-4.
12. Tarstedt M, Rosdahl I, Berne B, Svanberg K, Wennberg AM. A randomized multicenter study to compare two treatment regimens of topical methyl aminolevulinate (Metvix)-PDT in actinic keratosis of the face and scalp. *Acta Derm Venereol*. 2005;85(5):424-8.
13. Pariser DM, Lowe NJ, Stewart DM, Jarratt MT, Lucky AW, Pariser RJ, et al. Photodynamic therapy with topical methyl aminolevulinate for actinic keratosis: results of a prospective randomized multicenter trial. *J Am Acad Dermatol*. 2003;48(2):227-32.
14. Freeman M, Vinciullo C, Francis D, Spelman L, Nguyen R, Fergin P, et al. A comparison of photodynamic therapy using topical methyl aminolevulinate (Metvix®) with single cycle cryotherapy in patients with actinic keratosis: a prospective, randomized study. *J Dermatolog Treat*. 2003;14(2):99-106.
15. Cox NH, Eedy DJ, Morton CA. Guidelines for management of Bowen's disease. *British Association of Dermatologists. Br J Dermatol*. 1999;141(4):633-41.
16. Kao GF. Carcinoma arising in Bowen's disease. *Arch Dermatol*. 1986;122(10):1124-6.
17. Morton CA, Horn M, Leman J, Tack B, Bedane C, Tjioe M, et al. A randomized, placebo-controlled, European study comparing MAL-PDT with cryotherapy and 5-fluorouracil in subjects with Bowen's disease. *J Eur Acad Dermatol Venereol*. 2004;18(Suppl 2):415.
18. Horn M, Wolf P, Wulf HC, Warloe T, Fritsch C, Rhodes LE, et al. Topical methyl aminolevulinate photodynamic therapy in patients with basal cell carcinoma prone to complications and poor cosmetic outcome with conventional therapy. *Br J Dermatol*. 2003;149(6):1242-9.
19. Vinciullo C, Elliott T, Gebauer K, Spelman L, Nguyen R. MAL-PDT in patients with basal cell carcinoma: results of an Australian multicenter study. Poster presented to the International Skin Cancer Conference 2004, Zurich, Switzerland, July 22-24, 2004.
20. Basset-Seguín N, Ibbotson S, Emtestam L, Tarstedt M, Morton C, Maroti M, et al. MAL-PDT versus cryotherapy in primary sBCC: results of 36 months follow-up. *J Eur Acad Dermatol Venereol*. 2004;18 (suppl 2):412.
21. Basset-Seguín N, Ibbotson S, Emtestam L, Tarstedt M, Morton C, Maroti M, et al. MAL-PDT vs. cryotherapy in primary sBCC: results of 48-month follow up. *J Eur Acad Dermatol Venereol*. 2005;19 (Suppl 2):237.
22. Vinciullo C, Elliott T, Gebauer K, Spelman L, Nguyen R. MAL-PDT in patients with basal cell carcinoma: results of an Australian multicenter study. Poster presented to the International Skin Cancer Conference 2004, Zurich, Switzerland, July 22-24, 2004.
23. Horn M, Wolf P, Wulf HC, Warloe T, Fritsch C, Rhodes LE, et al. Topical methyl aminolevulinate photodynamic therapy in patients with basal cell carcinoma prone to complications and poor cosmetic outcome with conventional therapy. *Br J Dermatol*. 2003;149(6):1242-9.
24. Tope WD, Menter A, El-Azhary RA, Lowe NJ, Jarratt M, Pariser DM, et al. Comparison of topical methyl aminolevulinate photodynamic therapy versus placebo photodynamic therapy in nodular BCC. *J Eur Acad Dermatol Venereol*. 2004;18(Suppl 2):413-4.
25. Foley P, Freeman M, Siller G, Gebauer K, Murrell D, Barnetson R, et al. MAL-PDT or placebo cream in nodular basal cell carcinoma: results of an Australian double-blind randomized multicenter study. Poster presented at the International Skin Cancer Conference 2004, Zurich July 22-24, 2004.
26. Rhodes LE, de Rie M, Enstrom Y, Groves R, Morken T, Goulden V, et al. Photodynamic therapy using topical methyl aminolevulinate vs surgery for nodular basal cell carcinoma: results of a multicenter randomized prospective trial. *Arch Dermatol*. 2004;140(1):17-23.
27. Soler AM, Warloe T, Berner A, Giercksky KE. A follow-up study of recurrence and cosmesis in completely responding superficial and nodular basal cell carcinomas treated with methyl 5 aminolevulinate-based photodynamic therapy alone and with prior curettage. *Br J Dermatol* 2001;145(3):467-71.