

Difficulty in the diagnosis and bad prognosis associated with the regression of primary cutaneous melanoma

Dificuldade diagnóstica e mau prognóstico associados à regressão de melanoma cutâneo primário

ABSTRACT

The partial regression of cutaneous melanoma is a frequent event. Nevertheless, complete regression is a rare and difficult to diagnose condition. We report three cases of regressed cutaneous melanoma (RCM) whose initial biopsies did not reveal melanoma and in which the diagnosis was based on the presence of metastasis.

There is no consensus about the prognosis of RCMs. Some authors relate a higher prevalence of metastasis, coinciding with our cases' outcomes, where the RCM had the worst prognosis due to the tumors' aggressiveness or to the difficulty in establishing an early diagnosis and staging.

We have concluded that the regression of melanoma complicates the diagnosis, staging and formulation of a worst-case scenario prognosis. Excisional biopsy should always be the first choice.

Keywords: melanoma; neoplasm regression, spontaneous; neoplasm metastasis; prognosis.

RESUMO

O melanoma cutâneo primário em regressão (melanoma em regressão) espontânea parcial é frequente, porém a regressão completa é rara. O diagnóstico é difícil, principalmente na regressão completa. Relatam-se três casos de melanoma em regressão nos quais a biópsia inicial não revelou melanoma, e o diagnóstico foi obtido pelas metástases.

Não há consenso sobre o significado prognóstico da regressão. Nos casos descritos, o melanoma em regressão associou-se a pior prognóstico, pela própria característica do tumor ou dificuldade no diagnóstico precoce e estadiamento.

Conclui-se que a regressão no melanoma primário pode conferir maior dificuldade ao diagnóstico e estadiamento, com conseqüente pior prognóstico. Deve-se indicar biópsia excisional de lesão suspeita sempre que possível.

Palavras-chave: melanoma; regressão neoplásica espontânea; metástase neoplásica; prognóstico.

INTRODUCTION

Malignant melanoma represents 1.8% of all of malignant neoplasias; nevertheless, it accounts for 11% of spontaneous tumorous regression cases, a frequency five to six times higher than those of other neoplasias. Spontaneous regression is characterized by the partial or total fading of the tumor in the absence of any therapy capable of influencing its natural development¹. The partial regression of primary cutaneous melanoma (PCM) is frequent, taking place in 10% to 35% of cases. However, complete regression is rare. The estimated incidence ranges from 0.22% to 0.27%, with 40 cases described in the literature².

Case report

Authors:

Camila Ari Seque¹
 Mayra Ianhez²
 Laura de Sena Nogueira Maehara³
 Viviane Shinsato Higashi⁴
 Ivan Dunshee de A. de Oliveira Santos⁵
 Sergio Yamada⁶
 Fernando Augusto Almeida⁷
 Mílvia Maria Simões e Silva Enokihara⁸
 Nilceo Schwery Michalany⁹
 Sergio Henrique Hirata¹⁰
 Mauro Yoshiaki Enokihara¹¹

¹ 2nd year Resident at the Department of Dermatology of the Federal University of São Paulo (Unifesp) - São Paulo (SP), Brazil.

² Master in Dermatology from the Federal University of São Paulo (Unifesp) - São Paulo (SP), Brazil.

³ 3rd year Resident at the Department of Dermatology of the Federal University of São Paulo (Unifesp) - São Paulo (SP), Brazil.

⁴ 3rd year Resident at the Department of Dermatology of the Federal University of São Paulo (Unifesp) - São Paulo (SP), Brazil.

⁵ PhD in Plastic Surgery from the Federal University of São Paulo (Unifesp); Plastic Surgeon; Head and Neck Surgeon; Co-professor of the Plastic Surgery discipline at the Federal University of São Paulo (Unifesp) - São Paulo (SP), Brazil.

⁶ Master in Dermatology from the Federal University of São Paulo (Unifesp); Lecturer at the Department of Dermatology of the Federal University of São Paulo (Unifesp) - São Paulo (SP), Brazil.

⁷ PhD in Dermatology from the Federal University of São Paulo (Unifesp); Professor at the Department of Dermatology of the Federal University of São Paulo (Unifesp) - São Paulo (SP), Brazil.

⁸ PhD in Pathology from the Federal University of São Paulo (Unifesp); MD at the Department of Pathology of the Federal University of São Paulo (Unifesp) - São Paulo (SP), Brazil.

⁹ Master in Pathology from the Federal University of São Paulo (Unifesp); MD at the Department of Pathology of the Federal University of São Paulo (Unifesp) - São Paulo (SP), Brazil.

¹⁰ PhD in Dermatology from the Federal University of São Paulo (Unifesp); Professor at the Department of Dermatology of the Federal University of São Paulo (Unifesp) - São Paulo (SP), Brazil.

¹¹ PhD in Dermatology from the Federal University of São Paulo (Unifesp); Professor at the Department of Dermatology of the Federal University of São Paulo (Unifesp) - São Paulo (SP), Brazil.

Correspondence:

Dra. Camila Ari Seque
 Universidade Federal de São Paulo - (Unifesp)
 Departamento de Dermatologia
 Rua Borges Lagoa, 508 - Vila Clementino
 04038-001 - São Paulo - SP

Received on: 01/12/2009

Accepted for publication on: 10/01/2010

This study was conducted at the Federal University of São Paulo (Unifesp) - Medical School of the State of São Paulo.

Conflicts of interest: None
 Financial support: None

over time, studies about the nature and the prognostic meaning of regression in PCM suggested the association with distant metastases and the reduction of survival (3). This paper reports three cases of melanoma with regression (MR) associated with poor prognosis.

CASE 1

A female patient, white, 68 years old, presented with a history of treated ovarian neoplasia, with no recurrence. Three years ago the patient noticed a brownish stain of 1 x 0.5 cm in the right infraclavicular region, with progressive growth, without alteration of the color. The growth was

excised in another medical service, which concluded that the lesion was actinic keratosis. Six months ago the patient presented right side fast development axillary lymph node megalia (Figure 1). An excisional biopsy was carried out, whose histopathologic result revealed undifferentiated neoplasm with immunoeexpression of markers S100, Melan A and HMB45, compatible with metastatic melanoma. In the staging, tomographic images suggesting lymph node metastases in the right armpit, in the adrenal glands and lungs were identified (Figure 2). The histopathologic examination of the cutaneous lesion

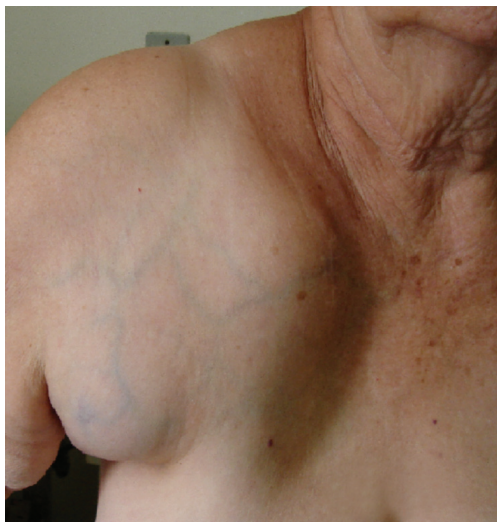

Figure 1: Right side axillary lymph node megalia

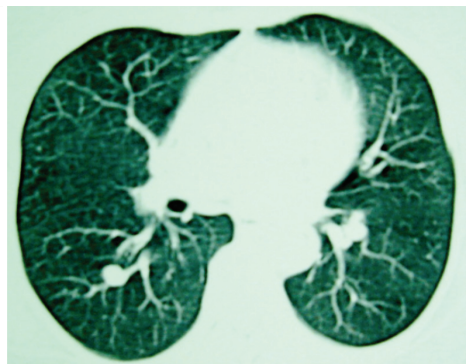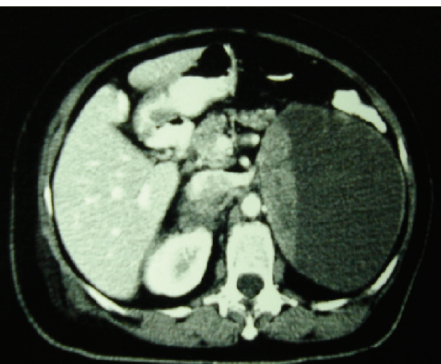
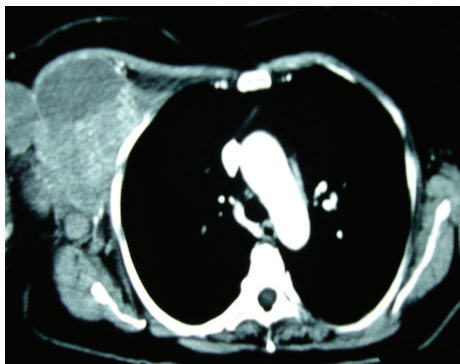


Figure 2: Suggestive tomographic images of right side axillary lymph node metastases, left adrenal gland and right pulmonary

revealed an area of melanocytic lesion regression (Figure 3, suggesting the presence of a primary tumor. The patient was referred to the Oncology Clinic for chemotherapy and radiation treatment, and died two months after the diagnosis of the metastatic melanoma.

CASE 2

Female patient, white, 62 years old. Two years ago the patient noticed a darkened stain in the dorsum (Figure 4), having been subjected to an incisional biopsy with to detect the presence of melanoma. The histopathologic study showed dermal melanocytosis with fibrosis and intense melanodermia (Figure 5). Less than one month later, the patient returned to the care service presenting hemiparesis on the right side, with two tomographic images having been identified as suggestive of brain metastases. A diagnostic approach for a brain lesion was then carried out, whose histopathologic and immunohistochemistry examinations (Figure 6) were compatible with metastatic melanoma, with the reversion of the neurological picture after treatment with phenytoin.

Exeresis of the cutaneous lesion on the dorsum was conducted, with histopathologic and immunohistochemistry diagnoses consistent with melanoma in regression (Figure 7). The

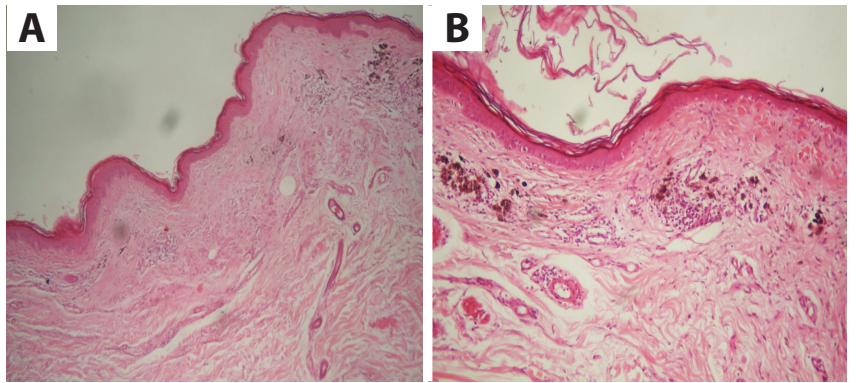
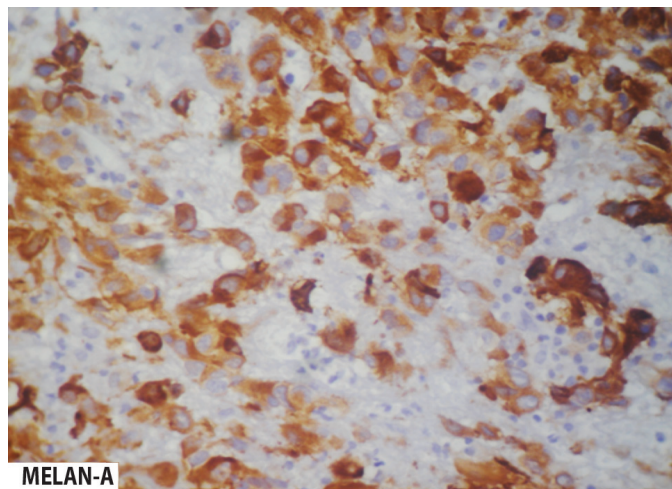


Figure 3: A and B - Histopathology of excisional biopsy of right infraclavicular cutaneous lesion
A - Area containing fibrosis, vascular capillary proliferation and infiltrated lymphocitary with permeating melanophages. It is suggested to be a melanocytic lesion regression (HE 40x)
B - Papillary dermis with perivascular infiltrated lymphocitary, various melanophages and eosinophilic bodies that may suggest cells in regression. The epidermis has become thinner and has flattened interpapillary crests (HE 100x)

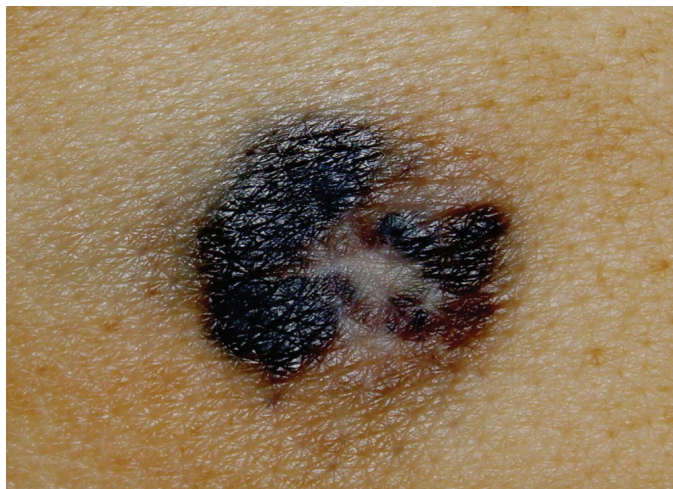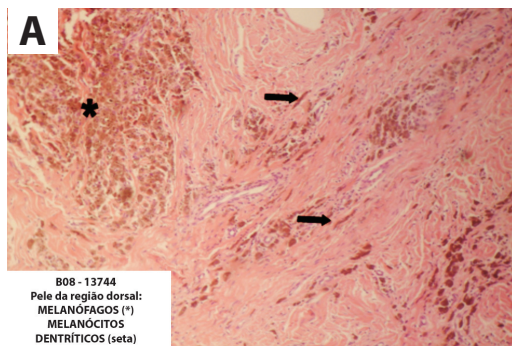


Figure 4: Hyperchromic, asymmetric stain on the dorsum, intermixed by depressed and whitish areas



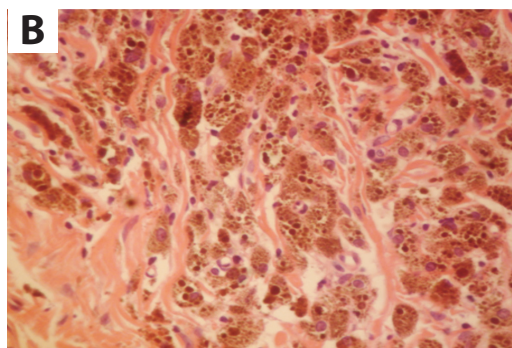
MELAN-A

Figure 6: Immunohistochemistry of brain metastases lesion: immunoe-expression of Melan A marker in the neoplasia cells (400x)



Figuras 5: A and B
Histopathology of Incisional biopsy of cutaneous lesion

A) Presence of melanophages (*) and dendritic melanocytes (arrows) (HE 100x)



B) Great quantity of melanophages (HE 400x)

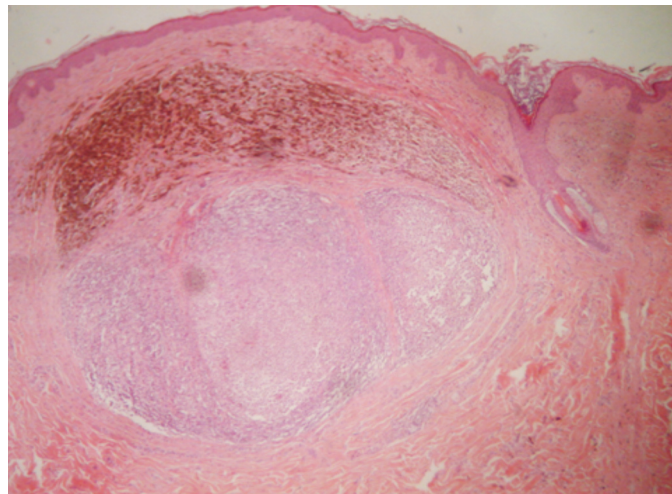


Figure 7: Histopathology of excised cutaneous lesion on the dorsum: nodule of residual melanoma with malignant melanocytic cells and several melanophages above. The epidermis does not present neoplasia (HE 40x)

patient was subjected to 10 radiation sessions, with recurrence of the cerebral metastases. The patient died 10 months after diagnosis.

CASE 3

A male patient, white, 57 years old, presented with itching and progressive growth of pigmented lesion in the left temporal region, for seven months. Four months prior the diagnosis, the patient noticed a painful nodule with progressive growth in the pre-auricular homolateral region. An intensely pigmented 1.5 x 1cm plaque in the left temporal region was characterized by dermatologic examination (Figure 8). To the dermatoscopy, the lesion presented an irregular and eccentric blotch, an area of

pigmentary pseudo reticulate, with gray-bluish points (melanophages in the dermis), and a whitish structure on the lesion (Figure 9). The histopathologic study of the temporal lesion was compatible with a melanocytic lesion in regression (Figure 10) and that of the pre-auricular lymph node indicated a metastatic melanoma. During the staging, ultrasonographic images suggestive of hepatic metastases were identified. The tomography of the skull and the x-ray of the thorax were normal. The patient died five months after diagnosis.

DISCUSSION

In 1963, Das Gupta, Bowden and Berg described the first cases of MR, on two patients apparently without primary lesions who presented with lymph nodes with metastatic melanoma. The biopsy of the suspicious cutaneous lesions revealed dermal fibrosis and pigmentary incontinence. There

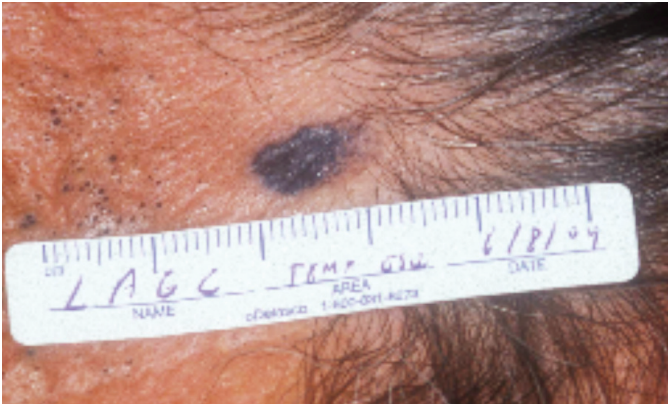

Figure 8: Intensely pigmented 1.5 x 1cm plaque in the left temporal region

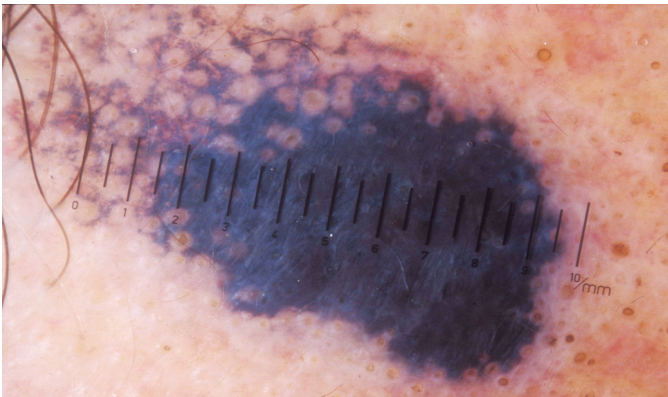


Figure 9: Dermatoscopy: irregular and eccentric blotch, pigmented pseudo reticulate area with gray-bluish points, and whitish structure on the lesion

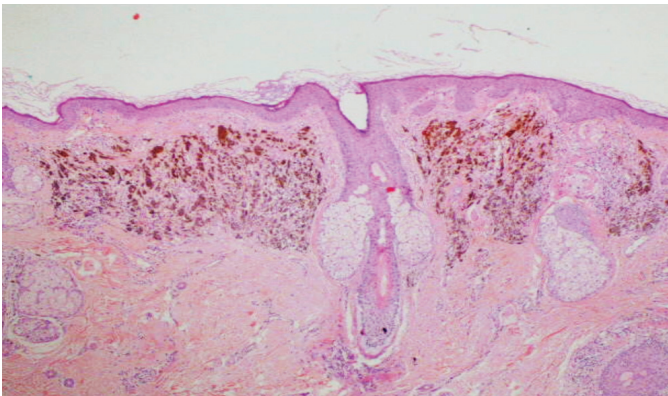


Figure 10: Histopathology of left temporal lesion: epidermal atrophy with sclerosis of the papillary dermis and intense underlying melanoderma, in addition to great quantity of melanophages (HE 40x)

were two possible explanations: malignant transformation of the node cells or complete regression of the primary lesion. In 1965, Smith and Stehlin published an extensive study and elaborated diagnostic criteria for the complete regression of primary cutaneous melanoma.

Regarding other neoplasias, PCM presents high rates of spontaneous regression. It was suggested that the lower suscep-

tibility to rarer tumors, such as melanoma, reflects a higher immunological resistance of the host, leading to a greater number of regressions¹.

Although the partial regression of PCM is frequent (10 to 35%), there are only 40 well documented cases of complete regression, with an estimated incidence of between 0.22% and 0.7%^{2,3}. On the other hand, the incidence of metastatic melanoma of indefinite primary site varies from 2% to 15%. Considering that some of the melanomas with complete regression (RCM) are not diagnosed and can evolve into metastases, it is believed that the real incidence of RCM is expressive¹⁴. There is a higher prevalence in males compared to females (2.7:1), and the average age at the time of diagnosis is 46. Once the diagnosis is made, the survival period varies between six weeks and 11 years^{1,3}.

Most patients with complete regression of the lesion report the transformation of a previous nevus, with an increase, darkening, bleeding or reduction of the relief, depigmentation and atrophy, in periods of two months to 14 years before the metastases diagnosis³. Bories and others have

accomplished a dermatoscopic study of lesions with complete regression histologically confirmed, describing the following parameters: scar-like depigmentation, rose background, irregular vessels and pigmentary remains. These parameters can be used in the search for a primary lesion in metastatic melanoma of indefinite site⁵.

The spontaneous regression of melanoma metastases may also occur, with 76 described cases from 1866. The main regression sites are skin/subcutaneous metastases and lymph nodes. There is association with a better prognosis¹.

Although circumstantial clinical evidence may suggest regression, the diagnosis is histopathologic. The regression is the histological consequence of the interaction between the neoplasia cells and the immune system of the host, resulting in the replacement of the tumor for fibrosis, degenerate neoplasia cells, melanophages, lymphocytic proliferation, and telangiectasia. In the areas with complete regression, there is a total absence of malignant melanoma cells in the dermis and epidermis⁶. Dunn and others reported the association between the complete histological regression and histiocytic intense infiltration. It is believed that the isolated presence of melanophages is sufficient to allow the interference of a previous melanocytic lesion³. However, there is no consensus about the exact definition and size of the regression. Depending on the criteria used, for instance, the estimated number of thin melanomas (< 1mm) that present regression varies between 7% and 61%, while that of thin metastatic melanomas varies between 40% and 100%⁶.

While the exact mechanism of the melanoma regression is not known, there is important circumstantial evidence of the involvement of the immune system. The presence of inflammatory cells, mainly lymphocytes – and also histiocytes (macrophages), yield a better prognosis; the high incidence of PCM, from two to four times among immunosuppressed patients, is indirect evidence. It was demonstrated that lymphocytes T CD4+ and CD8+ recognize the antigens of the

melanoma cells, using them as targets for cellular destruction. Bodurtha and others have verified that the lymphocitary cytotoxicity against two allogeneic lineage of tumorous cells was substantially high in a patient with melanoma in regression^{1,2}.

The prognostic meaning of the regression in PCM is controversial. Several studies report that regression is usually present in cases of metastatic melanoma, as described in this paper. In the analysis of 9,500 cases of melanoma registered in the Sidney Melanoma Unit database system, extensive regression comprising more than 75% of the tumorous area) has been detected in all cases of thin melanoma (< 0.8mm) with metastases in regional lymph nodes; McCarthy and others have found histological evidence of regression in cases of thin metastatic melanoma (< 0.5mm). In

contrast, in the research of micrometastases of the sentinel lymph node of PCM in regression, a low incidence of positive cases (from 2.2 to 5.7%) were observed in comparison to PCM without regression (17%), which would not justify the systematic biopsy of the sentinel lymph node in cases of regression^{1,7,8}.

In addition, it is impossible to determine the percentage of primary melanomas that have regressed completely without causing metastatic illness, impairing the interpretation of the prognostic meaning of regression in PCM². Nevertheless, the regression diagnosis in PCM is important, through the detailed clinical examination of the skin and mucous membranes in addition to histopathologic and immunohistochemistry studies, given that early detection allows the appropriate treatment and better evaluation of melanomas of indefinite primary site. The identification of spontaneous regression illustrates the necessity of regular monitoring in order to detect the possible development of metastases^{2,4}.

CONCLUSION

The diagnosis of PCM in regression is difficult and many times subsequent to the metastatic picture, associated with a poor prognosis. Hence, it is recommended that excisional biopsies of suspect lesions are conducted whenever possible. ●

REFERENCES

1. Kallialis LV, Drzewiecki KT, Klyver H. Spontaneous regression of metastases from melanoma: review of the literature. *Melanoma Res.* 2009;19(5):275-82.
2. Emanuel OP, Mannion M, Phelps RG. Complete Regression of Primary Malignant Melanoma. *Am J Dermatopathol.* 2008;30(2):178-81.
3. High WA, Stewart D, Wilbers CR, Cockerell CJ, Hoang MP, Fitzpatrick JE. Completely regressed primary cutaneous malignant melanoma with nodal and/or visceral metastases: a report of 5 cases and assessment of the literature and diagnostic criteria. *J Am Acad Dermatol.* 2005;53(1):89-100.
4. Schlagenhauff B, Stroebel W, Ellwanger U, Meier F, Zimmermann C, Breuninger H, et al. Metastatic melanoma of unknown primary origin shows prognostic similarities to regional metastatic melanoma: recommendations for initial staging examinations. *Cancer.* 1997;80(1):60.
5. Bories N, Dalle S, Debarbieux S, Balme B, Ronger-Savlé S, Thomas L. Dermoscopy of fully regressive cutaneous melanoma. *Br J Dermatol.* 2008; 158(6):1224-9.
6. Payette MJ, Katz M 3rd, Grant-Kels JM. Melanoma prognostic factors found in the dermatopathology report. *Clin Dermatol.* 2009;27(1):53-74.
7. Shaw HM, Rivers JK, McCarthy SW, McCarthy WH. Cutaneous melanomas exhibiting unusual biologic behavior. *World J Surg.* 1992;16(2):196-202.
8. McCarthy WH, Shaw HM, McCarthy SW, Rivers JK, Thompson JF. Cutaneous melanomas that defy conventional prognostic indicators. *Semin Oncol.* 1996;23(6):709-13.