

Glabellar wrinkles: a pilot study of contraction patterns

Rugas glabellares: estudo piloto dos padrões de contração

ABSTRACT

Introduction: Muscle activity at the glabella causes wrinkles that are perpendicular to muscle contraction. Such wrinkles are currently treated with botulinum toxin. However, interpersonal local contraction variations are revealed during facial animation. Although a great number of articles on this topic have been published, the patterns of glabellar contraction have not yet been adequately studied and classified.

Objective: To identify and classify the glabellar contraction patterns found in the population undergoing cosmetic treatment with botulinum toxin.

Methods: Retrospective photographic analysis of 30 patients receiving botulinum toxin for the treatment of glabellar wrinkles. The contraction patterns were identified and classified based on the prevalence of lowering, approximation, or lifting movements at the glabella.

Results: Five patterns were identified: 1) "U," 2) "V," 3) "Omega," 4) "Converging Arrows," and 5) "Inverted Omega." The classification method allowed indentifying the most important muscles in each contraction pattern.

Conclusion: There are interpersonal variations in facial animation. The classification of glabellar wrinkles enables a more accurate, individualized treatment with botulinum toxin. The most heavily used muscles receive higher doses or are injected into a larger number of sites. Those less solicited muscles are left untreated or receive lower doses, allowing for more effective and natural results.

Keywords: classification; botulinum toxins; rejuvenation.

RESUMO

Introdução: A atividade muscular na glabella provoca rugas perpendiculares à direção de contração dos músculos, hoje tratadas pela toxina botulínica. Variações interpessoais na forma de contração local, são exibidas durante a animação facial. Apesar dos inúmeros artigos publicados sobre o tema, os padrões de contração glabellar ainda não foram adequadamente estudados e classificados.

Objetivo: Identificar e classificar os padrões de contração glabellar encontrados na população que recebe tratamento cosmético com toxina botulínica.

Métodos: Análise retrospectiva de fotografias de 30 pacientes que receberam toxina botulínica para tratamento de rugas glabellares. De acordo com a predominância de movimentos de depressão, aproximação ou elevação da glabella, os padrões de contração foram identificados e classificados.

Resultados: Cinco padrões foram identificados: 1) "U", 2) "V", 3) "Ômega", 4) "Setas convergentes" e 5) "Ômega invertido". A classificação permitiu identificar os músculos mais importantes em cada padrão de contração.

Discussão/conclusão: Existem diferenças interpessoais na animação facial. A classificação das rugas glabellares permite tratamento mais acurado e individualizado com a toxina botulínica. Músculos mais recrutados recebem doses maiores ou maior número de pontos de aplicação. Os menos requisitados são poupados ou recebem doses menores, permitindo resultados mais eficazes e naturais.

Palavras-chave: classificação; toxinas botulínicas; rejuvenescimento.

Authors:

Ada Regina Trindade de Almeida¹
Elisa Raquel Martins da Costa Marques²
Bogdana Victoria Kadunc³

- ¹ Assistant Physician at the Dermatologic Clinic, Hospital of the Public Servants of São Paulo – São Paulo (SP), Brazil.
² Master in Dermatology from the University of São Paulo Medical School (FMUSP), Assistant Physician at the Dermatologic Clinic, Hospital of the Public Servants of São Paulo – São Paulo (SP), Brazil.
³ PhD in Dermatology from the University of São Paulo Medical School (FMUSP), Assistant Physician at the Dermatologic Clinic, Hospital of the Public Servants of São Paulo – São Paulo (SP), Brazil.

Correspondence:

Ada Regina Trindade de Almeida
Rua Fabia, 94 - apt. 111-A Vila Romma
05051 030 São Paulo SP, Brazil
Email: artrindal@uol.com.br

Received on: 25/01/2010

Accepted for publication on: 26/02/2010

This study was developed at dermatologic private practices

Conflicts of interest: None
Financial support: None

INTRODUCTION

The glabella, located between the two eyebrows, is the first area that is noticed in the facial mimic, and its contraction is usually associated with negative feelings such as worry, irritation, anger, frustration, or tiredness.¹

The main muscles in this area make up the glabellar complex and include the corrugators and orbicularis oculi (which approximate and lower the eyebrows), procerus and depressor supercillii (which lower the eyebrows) muscles, and the lower fibers of the frontalis (which lift the eyebrows).^{2,3} The muscle activity causes perpendicular hyperkinetic lines to muscle contraction, forming unaesthetic horizontal, vertical and oblique wrinkles.³

A number of methods have been described for rejuvenation of the glabella, such as the use of fillers, ablative techniques such as peeling and laser treatments, surgical procedures, and chemodenervation with botulinum toxin.⁴ The latter was described in 1990 by Jean and Alastair Carruthers⁵ and is now the treatment of choice for this area and one of the most commonly studied in related scientific publications.^{6,7}

Most of the articles assume that glabellar wrinkles are identical in the majority of patients, only with differences related to gender (larger muscle mass and thicker skin in men),^{6,8} age, ethnicity,^{9,10} solar exposure, or physical activity.¹¹

The literature on the cosmetic use of botulinum toxin describes traditional models of injection into the glabella, with three,¹² five,¹²⁻¹⁶ and seven^{14,17} sites distributed to the corrugator, procerus and/or orbicularis oculi muscles. Reports are made as if the suggested injection models would fit every single case, with no publications being found that would identify different glabellar contraction patterns.

Although most individuals have similar anatomy, there are interpersonal differences in facial animation and expressions that are typical of each person. Therefore, variations can be identified in the contraction patterns for the same area during facial animation in different patients. In a postmortem anatomical study, Benedetto and Lahti¹⁸ found individual variations in the corrugator location and insertion, regardless of the gender.

In 1974, Rubin¹⁹ described different types of smile, each of them having a distinct muscle group that prevails. In 2003, Kane²⁰ classified periorbital wrinkles into four groups, and reported his differentiation as a "key" for treatment individualization.

Similarly, some types of contractions are also repetitive in the glabella, showing individual differences in how muscles are recruited and resulting in the prevalence of eyebrow lowering, approximation, or lifting movements.

OBJECTIVE

The objective of this retrospective case analysis study was to identify and classify the glabellar contraction patterns found in the population undergoing cosmetic treatment with botulinum toxin. This study complied with the ethical rules recommended by the 2000 Declaration of Helsinki.

METHODS

A retrospective evaluation of photos of 30 randomly selected patients who had received botulinum toxin for the first time to treat glabellar wrinkles was conducted. The cases were selected in the authors' private practices. Sixty sets of photos of 4 men and 26 women were included. The patients' ages ranged from 29 to 62 years old (mean, 43 years). Patients with a previous history of ablative (dermabrasion, peeling, or laser), surgical or filling treatments on the region were excluded from the analysis. There was no restriction of gender or phototype. The photos were taken at rest and during contraction (upon request) of the glabella. Between the first and the last photo of each case, the camera, lighting, and distance parameters were maintained.

RESULTS

Through the analysis of the prevailing movement observed in the 30 evaluated cases, five different glabellar contraction patterns were identified and classified: 2 showing simultaneous lowering and approximation of the glabella, each with different intensity levels; 1 showing approximation only; 1 showing simultaneous approximation and lifting; and 1 showing prevalence of lowering.

CLASSIFICATION OF GLABELLAR CONTRACTION PATTERNS

In a didactic manner, in order to facilitate identification, a symbol was assigned to each contraction pattern, as described below:

1) "U" pattern – This is the second most common type, found in 27% of the study cases. The individuals classified in this pattern show, during stimulated contraction, prevalence of mild approximation and lowering of the glabella, with the resulting movement resembling the shape of the letter "U." Elevation of the tail of the eyebrows occurs simultaneously. At rest, the brows remain arched. The most heavily involved muscles are the corrugators and procerus, which are not very strong muscles. This would be treated by using the traditional five-site model, at the standard doses (Figure 1).

2) "V" pattern – This is the most frequent type, seen in 37% of cases. The approximation and lowering of the eyebrow medial portion, which vary from moderate to severe, are observed at a much higher intensity than in the previous group. In some cases, the lowering of the eyebrow is so strong that it can extend up to its lateral portion. At rest, patients' eyebrows are more horizontal or rectified and on a lower location. In addition to the greater strength of the corrugators and procerus, there is also an important participation of the medial portion of the orbicularis. These patients require higher doses of toxin and more injection sites, with the best approach being the seven-point model. The higher doses are concentrated in the procerus and corrugators (Figure 2).

3) "Omega" pattern – This pattern accounted for 10% of patients in our study. For this group, the prevailing movements are of medial approximation and lifting of the glabella, forming the Greek letter "Omega." Simultaneously, lateral lowering of the eyebrows occurs. The prevailing muscles are the

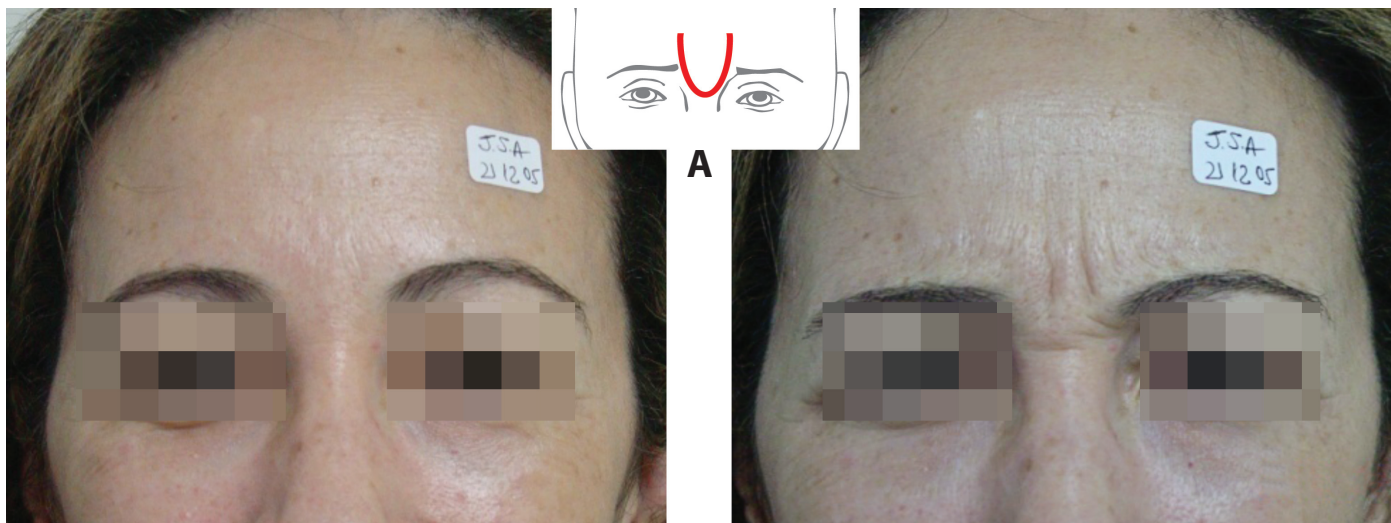


Figure 1: Example of a patient with a "U" contraction pattern, at rest and during contraction.

A) Illustrates the final glabellar approximation and lowering movement .

B) Suggests how the toxin doses should be distributed.



corrugators, medial portion of the orbicularis, and frontalis , with little or no contraction of the procerus. The best approach for these cases would be to inject the corrugators and orbicularis oculi as well as the medial portion of the frontalis, with higher toxin doses into the corrugators and smaller doses into the frontalis and orbicularis sites. The procerus muscle does not need to be treated, or it may be injected with a minimal dose (Figure 3).

4) "Converging Arrows" pattern – This pattern mainly shows approximation of the eyebrows, with little or no lowering or lifting of the medial or lateral portion..The resulting final movement is of horizontal approximation. There seems to be a balance of forces between the procerus and frontalis in this group. This pattern was found in 20% of the cases. The involved muscles are the corrugators and the medial portion of the orbicularis oculi, and the injection scheme should be more horizon-

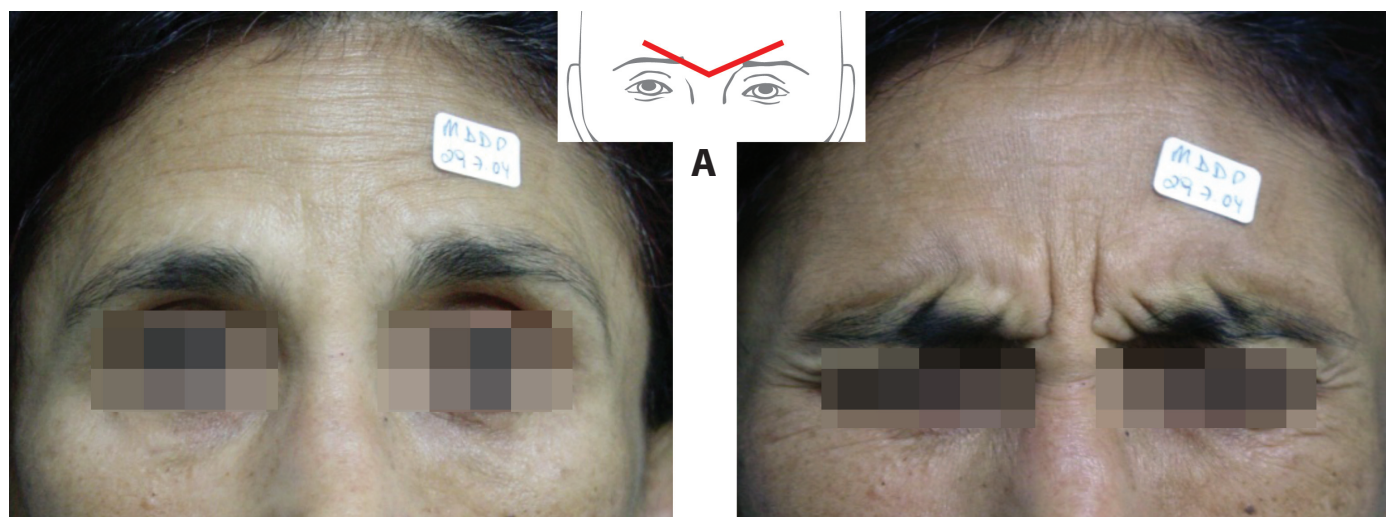


Figure 2: Example of a patient with a "V" contraction pattern, at rest and during contraction.

A) illustrates the strong final glabellar approximation and lowering movement.

B) Suggests how the toxin doses should be distributed



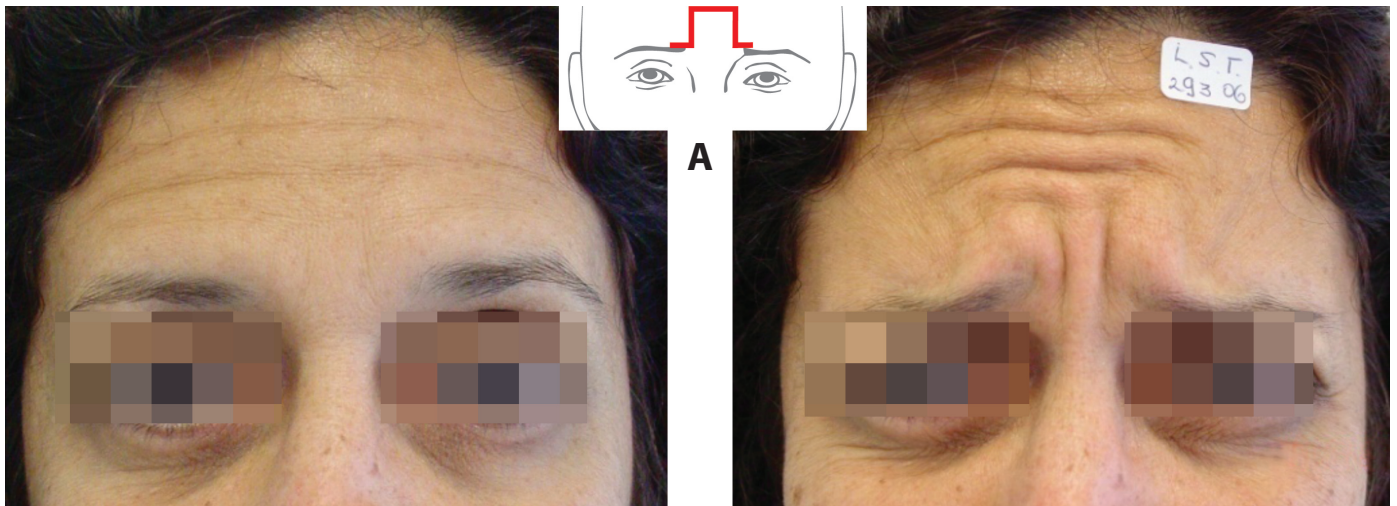


Figure 3: Example of a patient with "Omega" contraction pattern, at rest and during contraction. **A)** illustrates the final glabellar of approximation and medial lifting movement. **B)** Suggests how the toxin doses should be distributed

tal, focusing on them. There is no need to inject the procerus or the frontalis. (Figure 4)

5) "Inverted Omega" pattern – This is the least frequent pattern, observed in only 6% of patients. The prevailing movement is of lowering, more than approximation, resembling an inverted Greek letter "Omega." The involved muscles are mainly the procerus, depressor supercili, the internal portion of the orbicularis oculi, and possibly the nasalis as well, although it is not classified as a glabellar muscle. In this group, the corruga-

tors have more limited participation. It seems to be more common in patients having a flattened nasal apex, as is the case of Asians. The most adequate treatment is the use of higher doses into the procerus and depressor supercili muscles, and lower doses into the internal portion of the orbicularis oculi and the nasalis muscle. A minimal dose may or may not be injected into the corrugators. (Figure 5)

Individuals with asymmetric eyebrows show different patterns on each side; therefore, they are doubly classified and treated.

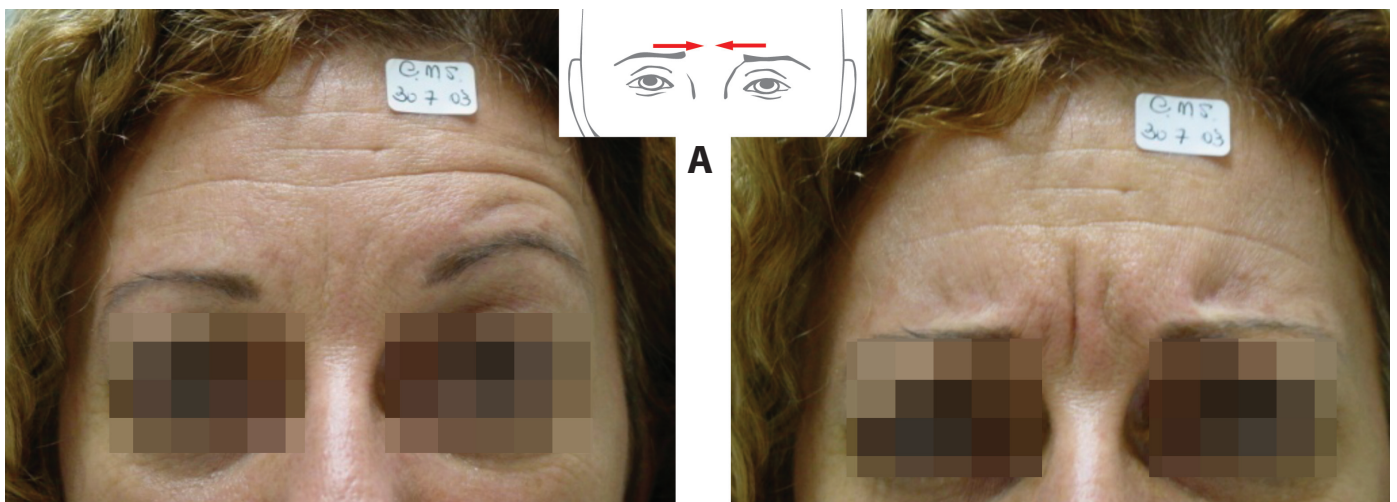


Figure 4: Example of a patient with "Converging Arrows" contraction pattern, at rest and during contraction. **A)** Illustrates the final glabellar horizontal approximation movement. **B)** Suggests how the toxin doses should be distributed

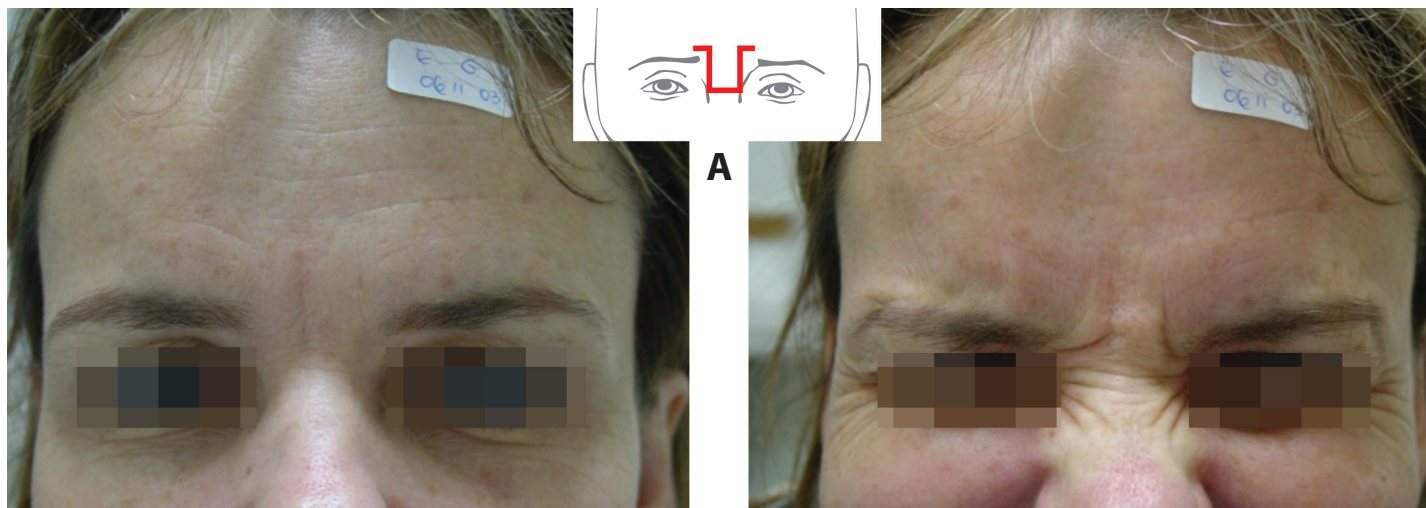


Figure 5: Example of a patient with "Inverted Omega" contraction pattern, at rest and during contraction, including the action of the nasalis muscle.
A) Illustrates the glabellar lowering movement.
B) Suggests how the toxin doses should be distributed

DISCUSSION

In daily practice, the glabella is the most frequently treated region with botulinum toxin and numerous are the related scientific publications. However, the suggested approaches are always repeated, as if they could be replicated for every single case. Such a standardized approach is necessary for comparative and multicenter study purposes, in which cases individualization is not desirable.

Nevertheless, in the daily routine of dermatological practices, standardized treatments are only effective for some cases, whereas for others they cause irregular results, with some of them being "heavy," "artificial," or "plasticized" and some having persistence of contraction – which is intended to avoid. Currently, a natural expression is the goal of cosmetic treatments. For that reason, the more specific, individualized the approach is, the better the final results are.

Rubin¹⁹ demonstrated that there are variations in smiles, depending on the prevalence of the different muscle groups. Accordingly, he classified smiles into three types: a) "Mona Lisa," with prevalence of action of the zygomaticus major muscle and characterized by very elevated mouth corners; b) "Canine," with higher participation of the levator labii superioris muscle, in which case a smile with strong lifting of the upper lip's medial portion is manifested; and c) "full denture," in which the simultaneous contraction of the levator labii superioris and depressor muscles occurs.

The use of Rubin's classification allowed Kane to subsequently select more appropriate cases for the correction of deep nasogenial crease with botulinum toxin, thereby preventing unsatisfactory results in other patients.²¹

In another article, Kane set a classification system for peri-orbital wrinkles, which were divided into: a) superior, b) inferior, c) central, and d) complete.²⁰ Because only one muscle group is involved – the orbicularis oculi, the classification was based on the hyperkinetic segment.²⁰ The aim of this categorization was also to enable a more individualized treatment, with more effective and natural results.

Likewise, for the glabellar region, a need of organizing and labeling the contraction patterns observed in daily practice is noted. As with Kane's experience,²⁰ these patterns were not created, but rather they were simply noticed over the years, confirmed by peers in personal communications, and supported by the findings of this pilot study.

This classification system enables a more accurate, individualized treatment with botulinum toxin. Muscles that are more recruited, hyperkinetic, and/or hypertonic receive higher doses or more injection sites. Other less solicited muscles are injected with lower doses or not treated at all.

CONCLUSION

To achieve satisfactory, natural individualized results in the treatment of the glabella with botulinum toxin, it is necessary to understand that, although the anatomy is similar among individuals, the way people use their musculature varies. The classification of glabellar wrinkles makes the identification of the prevalent contraction pattern easier, allowing concentrating the dose in the involved muscles and leaving those less used untreated or avoiding them. ●

REFERENCES

1. Finn JC, Cox SE, Earl ML. Social implications of hyperfunctional facial lines. *Dermatol Surg.* 2003;29(5):450-5.
2. Sommer B, Sattler G, editors *Botulinum toxin in Aesthetic Medicine.* Viena: Blackwell Science;2001. p.31.
3. Madeira CL, Marques ERM C. *Noções de Anatomia da Face In: Gadelha AR, Costa IMC. Cirurgia Dermatológica em consultório.* Rio de Janeiro: Atheneu; 2003. p.77-94.
4. Hankis CL, Strimling R, Rogers GS. Botulinum A Toxin for Glabellar Wrinkles. Dose and response. *Dermatol Surg.* 1998;24(11):1181-3.
5. Carruthers A, Carruthers J. The treatment of glabellar furrows with Botulinum A exotoxin. *J Dermatol Surg Oncol.* 1990;16:83-4.
6. Carruthers J, Fagien S, Matarasso SL, Botox Consensus Group. Consensus recommendations on the use of botulinum toxin type A in facial aesthetics. *Plast Reconstr Surg.* 2004;114(Suppl 6):1S-22S.
7. Carruthers JD, Glogau RG, Blitzler A, Facial Aesthetics Consensus Group Faculty. Advances in facial rejuvenation: botulinum toxin type a, hyaluronic acid dermal fillers, and combination therapies--consensus recommendations. *Plast Reconstr Surg.* 2008;121(5):5S-30S.
8. Draelos ZD. The shrinking word: Skin considerations in a global community. *J Cosmet Dermatol.* 2006;5(1):1-2.
9. Porter JP, Lee JI. Facial analysis: Maintaining ethnic balance. *Facial Plast Surg Clin North Am.* 2002;10(4):343-9.
10. Ahn KY, Park MY, Park DH, Han DG. Botulinum toxin A for the treatment of facial hyperkinetic wrinkle lines in Koreans. *Plast Reconstr Surg.* 2000;105(2):778-84.
11. Rexbye H, Petersen I, Johansens M, Klitkou L, Jeune B, Christensen K. Influence of environmental factors on facial aging. *Age Ageing.* 2006;35(2):110-5.
12. Rzany B, Ascher B, Fratila A, Monheit GD, Talarico S, Sterry W. Efficacy and safety of 3- and 5-injection patterns (30 and 50 U of botulinum toxin A (Dysport) for the treatment of wrinkles in the glabella and the central forehead region. *Arch Dermatol.* 2006;142(3):320-6.
13. Monheit G, Carruthers A, Brandt F, Rand R. A randomized, doubleblinded, placebo-controlled study of Botulinum toxin type A for the treatment of glabellar lines: determination off the optimal dose. *Dermatol Surg.* 2007;33(suppl 1):S51-S59.
14. Carruthers A, Carruthers J. Clinical indications and injection technique for the cosmetic use of botulinum A exotoxin. *Dermatol Surg.* 1998; 24(11):1189-94.
15. Carruthers J, Carruthers A. Botulinum toxin type A treatment of multiple upper facial sites: patient-reported outcomes. *Dermatol Surg.* 2007;33 (1 Spec No): S10-S17.
16. Fagien S, Cox SE, Finn JC, Werschler WP, Kowalski JW. Patient-reported outcomes with botulinum toxin type A treatment of glabellar rhytides: A double-blind, randomized, placebo-controlled study. *Dermatol Surg.* 2007;33(1 Spec No):S2-S9.
17. Carruthers A, Carruthers J. Eyebrow hight after Botulinum toxin type A to the glabella. *Dermatol Surg.* 2007;33(1):S26-S31.
18. Benedetto AV, Lahti JG. Measurement of the anatomic position of the corrugator supercilli. *Dermatol Surg.* 2005;31:923.
19. Rubin LR. The anatomy of a smile: Its importance in treatment of facial paralysis. *Plast Reconstr Surg.* 1974;53(4): 384-7.
20. Kane MAC. Classification of Crow's Feet Patterns among Caucasian women: the Key to individualizing treatment. *Plast reconstr Surg.* 2003;112(5 suppl):33S-39S.
21. Kane MAC. The effect of Botulinum toxin injections on the Nasolabial fold. *Plast reconstr Surg.* 2003;112(5 suppl):66S-72S.