

## Case Reports

### Authors:

Rogério Nabor Kondo<sup>1</sup>  
 Fabiana de Mari Scalone<sup>1</sup>  
 Luciana Rigolin Mazoni Alves<sup>1</sup>  
 Ricardo Hirayama Montero<sup>1</sup>

<sup>1</sup> Department of Internal Medicine, Dermatology Service, do Hospital Universitário Regional do Norte do Paraná da Universidade Estadual de Londrina, Londrina, Paraná (PR), Brazil.

### Correspondence:

Av. Ayrton Senna da Silva, 1055 - sala 1205- Gleba Fazenda Palhano 86050-460 Londrina (PR)  
 E-mail: kondo.dermato@gmail.com

Received on: 26/01/2020

Approved on: 03/11/2020

Study conducted at the Dermatology Service of the Hospital Universitário do Norte do Paraná - Universidade Estadual de Londrina, Brazil.

Financial support: None.

Conflict of interest: None.



# Autologous fat transplantation: a good option for treatment to facial deformity after head trauma

*Lipoenxertia autóloga: uma boa opção para tratamento de deformidade facial após traumatismo craniano*

DOI: <http://www.dx.doi.org/10.5935/scd1984-8773.20201242518>

## ABSTRACT

Correcting facial deformities is still a significant challenge for the dermatological surgeon. The therapeutic options may vary depending on the etiology, location, costs, and attending physician's experiences of the. Although some studies have shown controversies regarding the results of using autologous fat transplantation (AFT) to treat facial depression, we report a case with good aesthetic results after two sessions of AFT in a male patient with a depressed facial fracture after head trauma.

**Keywords:** Transplantation; Transplantation, Autologous; Subcutaneous fat; Skull fracture, depressed

## RESUMO

*Corrigir deformidades na face ainda é um grande desafio para o cirurgião dermatológico. As opções terapêuticas podem variar conforme a etiologia, a localização, os custos e a experiência do médico-assistente. Apesar de alguns trabalhos demonstrarem controvérsias quanto aos resultados do uso de lipoenxertia autóloga (LA) para tratamento de depressões na face, relatamos um caso com bom resultado estético, após duas sessões de LA, em paciente masculino com afundamento facial após traumatismo craniano.*

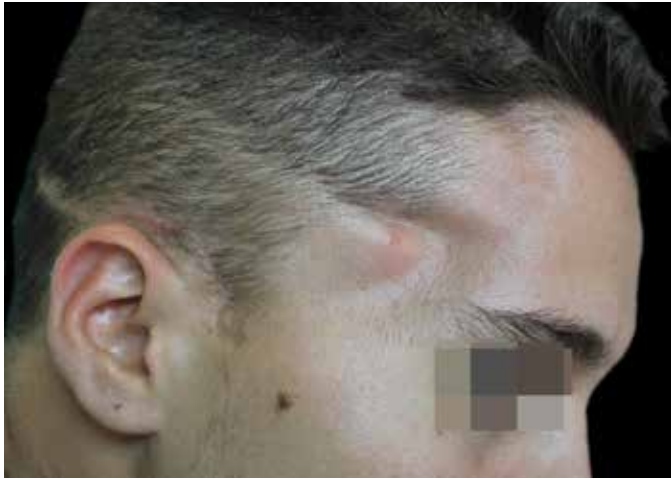**Palavras-chave:** Fratura do crânio com afundamento; Transplante; Transplante autólogo; Gordura subcutânea

## INTRODUCTION

Depending on the facial deformity and its etiology, it is possible to use several methods, from less invasive ones (such as botulinum toxin<sup>1</sup> and filling with hyaluronic acid<sup>2</sup>) to more complex surgeries (such as silicone implants or acrylic resin prostheses<sup>3</sup>). Autologous fat transplantation (AFT) is a surgical alternative, especially in cases of lipodystrophy.<sup>4-10</sup>

We report a case of a patient with complaints of depressed facial scars (Figure 1) after a head injury, which is considered ideal for AFT for treatment, with satisfactory aesthetic results. Although this technique has cost-benefit advantages, the literature describes the unpredictability of the results due to the possibility of absorption with consequent loss of volume and the need for new uses.<sup>5,6,7</sup>

This case report aims to demonstrate this technique's effectiveness, low cost, easy performance, and patient and surgical team's good satisfaction level.



**FIGURE 1:** Right frontal deformity

## METHODS

A 15-year-old man, student, had a motorcycle crash, with a consequent head injury and frontal, parietal, and temporal bone fractures on the right side. He underwent neurosurgical interventions, such as bone graft and insertion of a platinum plate, to correct depressed scars and fractures. After days of induced coma and intensive care, the patient evolved without motor sequelae at hospital discharge (only local paraesthesia) but with aesthetic deformity (he referred to a local depressed scar) that bothered him. He was 16 years old when he underwent neurosurgery for dermatological assessment.

As it was only an aesthetic correction, the mother and the patient were informed about the procedure. They signed the Patient Photo Release and Informed Consent forms.

The patient remained with the bandages for 24 hours. We prescribed sulfamethoxazole and trimethoprim tablets 400/80 mg<sup>2</sup> every 12 hours for ten days.

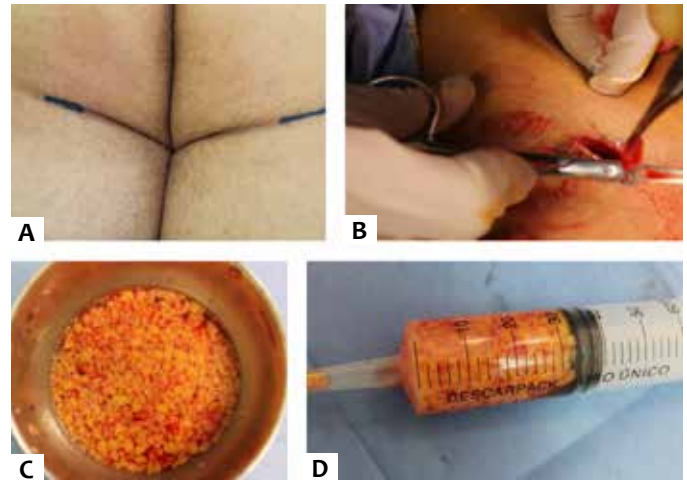
### Technique Description:

#### I - Removal of fat tissue (Figure 2)

- a) Patient in a horizontal position;
- b) Marking of the bilateral infra-gluteal fold (donor site);
- c) Asepsis with 10% topical polyvinyl iodine from the donor site;
- d) Placing of surgical drapes;
- e) Infiltration of the donor site using 2% lidocaine with vasoconstrictor;
- f) Linear incision with blade size 15;
- g) Removal of fat tissue with Adson forceps and iris scissors and insertion of the material in a vat with saline;
- h) Fractionation of fat tissue with iris scissors into smaller fragments for better aspiration of the contents in the urological syringe;
- i) Primary wound closure using 4.0 mononylon, single stitches, from the donor site;

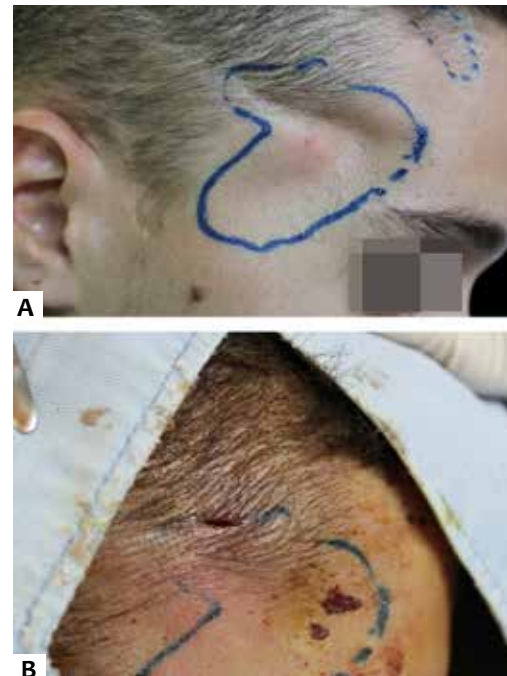#### II - Fat grafting (Figure 3)

- a) Marking the area to be filled;

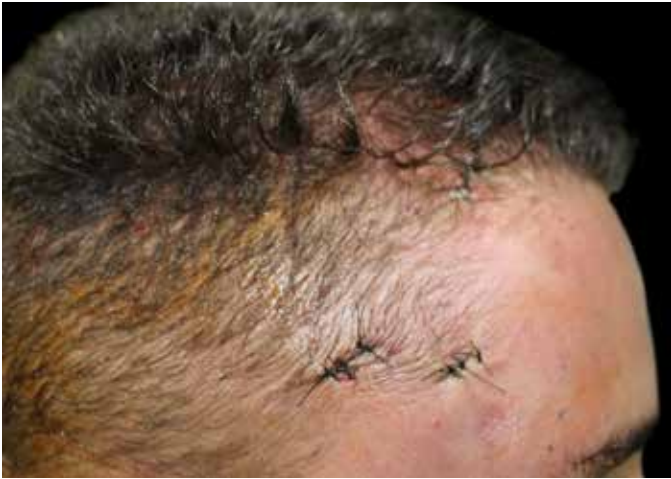

**FIGURE 2:** A - Marking on the infra-gluteal fold. B. Removal of adipose tissue. C. Fragmented adipose tissue. D. Urological syringe filled with fat

- b) Anesthetic infiltration using 2% lidocaine with a vasoconstrictor surrounding the marked area;
- c) 6 mm incision, using blade size 15 on the upper parts of the demarcated areas (at 12 hours);
- d) Local skin detachment using a tentacle, through the incisions, in the plane above the skull (in this case), up to the previously delimited area;
- e) Using a urological syringe (60 ml), fat is injected through the incision until it fills the detached cavity;
- f) Incision suture with 5.0 mononylon, single stitches;
- g) Local cleaning with saline;
- h) Occlusive dressing with gauze.



**FIGURE 3:** A - Marking the area to be filled. B. Incision with blade size 15 and local detachment using tentacle



**FIGURE 4:** Immediate postoperative

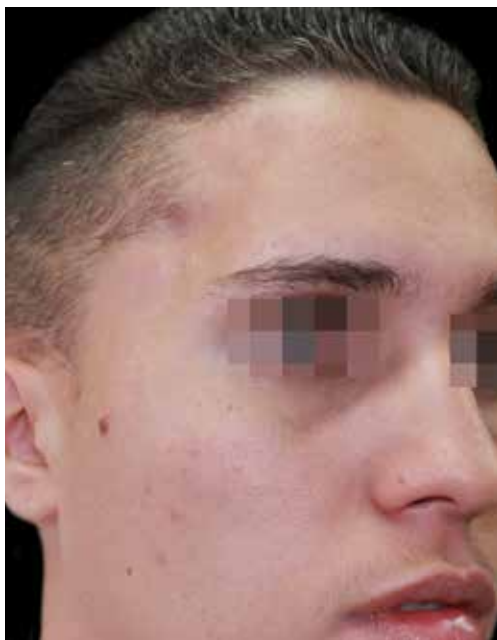### RESULTS

The patient responded well in the immediate postoperative period, without infection of the surgical sites or hemorrhages. Six months after the intervention, he presented good aesthetics and no functional impairment of the face, although partial resorption of local fat occurred (Figure 5). We recommended a second AFT with the consent of the patient and his mother.

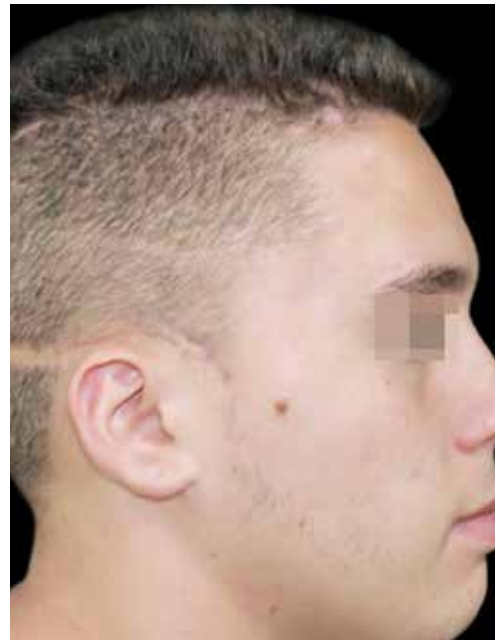The second intervention was conducted without complications. After nine months, the patient presented a very good aesthetic result (Figure 6).

### DISCUSSION

The correction of facial deformities, whatever their etiology, is still a significant challenge for the dermatological surgeon. In more straightforward cases, such as post-traumatic



**FIGURE 5:** Six months after the first intervention



**FIGURE 6:** Nine months after the second intervention

chin deformities, botulinum toxin can be used.<sup>1</sup> However, for lipodystrophy or depressed facial scars, autologous fat grafting (AFT), hyaluronic acid, or poly-L-lactic acid are recommended.<sup>2</sup> For cases of cartilage and bone loss, acrylic resin prostheses can be used.<sup>3</sup>

AFT is very interesting in correcting facial deformities, considering that the adipose tissue is relatively abundant on the skin surface, has an ideal texture and modeling, in addition to an almost zero tissue rejection index.<sup>6,8,10</sup> Although it has been proposed since the end of the 19th century, some studies present controversies regarding the procedure given the effectiveness of the results.<sup>6,8</sup> The hypothesis for no improvement would be fat absorption or low tissue viability transferred.<sup>6</sup>

With the neurosurgery team's permission, in the case of an aesthetic procedure, we opted to perform the AFT in the present case, considering the low cost, tissue rejection rate, and risk of complications.

The patient evolved with good aesthetic results, and after six months of the first surgery (Figure 5), there was a significant improvement in the local depressed scar. Even so, we conducted a second intervention to correct the possible absorption of some areas. Nine months later, the patient achieved an excellent result (Figure 6). Some studies have also noticed a significant improvement with AFT, especially after the second intervention.<sup>5,6</sup>

This study hypothesizes that the procedure's effectiveness is higher on the second session due to the remaining adipocytes' presence from the first intervention. It hinders the absorption of this new injected fat tissue and, somehow, also stimulates fibroblasts.

Another therapy option is poly-L-lactic acid (PPLA). PPLA is a biocompatible, resorbable, and immunologically inert polymer. Its mechanism of action consists of the stimula-

tion of fibroblasts in their subclinical inflammatory response. It can be used in cases of facial deformities, including plates and screws.<sup>2,6</sup> We opt for not using it due to the extent of the depressed scar, costs, and risk of papules, nodules, and granulomas formation.

Although some studies have shown controversial results, the AFT technique used in the case has proved to be entirely satisfactory. The deformity that the patient called “sinking” was solved and provided an improvement in his self-esteem.

## CONCLUSION

AFT is a technique that is easy to perform, well-tolerated, has low cost, and presents good cosmetic results (Figures 5 and 6).

## ACKNOWLEDGMENTS

The authors thank the patient who collaborated in the study and trusted the medical team in his treatment. ●

## REFERENCES

1. Park EJ, In SK, Yi HS, Kim HI, Kim HS, Kim HY. Treatment of post-traumatic chin deformities using bilateral botulinum toxin injections. *Arch Craniofac Surg.* 2019;20(5):310-3.
2. Zhang AJ, Moraites E, Goldfarb N, Liszewski W, Farah RS. Acquired partial lipodystrophy treated with poly-L-lactic acid and hyaluronic acid fillers: a case report. *J Cosmet Laser Ther.* 2019;21(4):201-2.
3. Aggarwal V, Datta K, Kaur S. Rehabilitation of post-traumatic total nasal defect using silicone and acrylic resin. *J Indian Prosthodont Soc.* 2016;16(1):87-90.
4. Wang KY, Yang Z, Wang WL, Xu H, Liu FY. Autologous free fat graft for repair of concave deformity after total parotidectomy. *J Craniofac Surg.* 2019;30(3):834-7.
5. Xie Y, Li Q, Zheng D, Lei H, Pu LLQ. Correction of hemifacial atrophy with autologous fat transplantation. *Ann Plast Surg* 2007;59(6):645- 653.
6. Alencar JCG, Andrade SHC, Pessoa SGP, Dias IS. Lipoenxertia autóloga no tratamento da atrofia hemifacial progressiva (síndrome de Parry-Romberg): relato de caso e revisão da literatura. *An Bras Dermatol.* 2011;86(4 Supl 1):S85-8.
7. Volker LW, Warnke PH, Douglas T, Wiltfang J. Unilateral atrophy of the cheek: autologous fat injection as treatment of choice. *J Craniofac Surg.* 2009;20(2):423-5.
8. Wetterau M, Szpalski C, Hazen A, Warren SM. Autologous fat grafting and facial reconstruction. *J Craniofac Surg.* 2012;23(1):315-8.
9. Koonce SL, Grant DG, Cook J, Stelnicki EJ. Autologous fat grafting in the treatment of cleft lip volume asymmetry. *Ann Plast Surg.* 2018;80(6S Suppl 6):S352-5.
10. Egro FM, Coleman SR, Rubin JP. Fat grafting for treatment of secondary facial deformity. *Clin Plast Surg.* 2020;47(1):147-54

## AUTHORS ' CONTRIBUTION:

**Rogério Nabor Kondo** |  ORCID 0000-0003-1848-3314

Approval of the final version of the manuscript; study design and planning; preparation and writing of the manuscript; active participation in research orientation; intellectual participation in propaedeutic and/or therapeutic conduct of studied cases; critical literature review; critical revision of the manuscript.

**Fabiana de Mari Scalone** |  ORCID 0000-0002-5050-8246

Approval of the final version of the manuscript; study design and planning; preparation and writing of the manuscript; critical literature review; critical revision of the manuscript.

**Luciana Rigolin Mazoni Alves** |  ORCID 0000-0003-4865-4110

Approval of the final version of the manuscript; preparation and writing of the manuscript; critical literature review; critical revision of the manuscript.

**Ricardo Hirayama Montero** |  ORCID 0000-0001-8148-1026

Approval of the final version of the manuscript; preparation and writing of the manuscript; critical literature review; critical revision of the manuscript.