

How I do

Authors:

Carlos Gustavo Wambier¹
 Brittany G. Craiglow^{2,3}
 Brett A. King²

¹ Department of Dermatology, Warren Alpert Medical School, Brown University, Providence, Rhode Island, USA.

² Department of Dermatology, Yale School of Medicine, Yale University, New Haven, CT, USA.

³ Dermatology Physicians of Connecticut, Fairfield, CT, USA.

Correspondence:

Brett A. King
 PO Box 208059, New Haven, CT 06520.
 E-mail address: brett.king@yale.edu

Received on: 11/01/2020

Approved on: 10/03/2020

Research conducted at the Department of Dermatology, Yale School of Medicine, Yale University, New Haven, CT, USA.

Financial Support: BAK received funding support from The Ranjini and Ajay Poddar Resource Fund for Dermatologic Diseases Research

Conflict of interest: BAK and CGW are investigators for Concert Pharmaceuticals Inc., Eli Lilly and Company and Pfizer Inc. BAK is a consultant to and/or has served on advisory boards for Aclaris Therapeutics, Concert Pharmaceuticals Inc., Dermavant Sciences, Aclaris, Eli Lilly and Company, Pfizer Inc.; BAK and BGC are on speaker bureau for Pfizer Inc., Regeneron, Sanofi Genzyme. BGC is a consultant and has served on advisory boards for Pfizer Inc.



Adjuvant oral minoxidil for the treatment of alopecia areata refractory to Janus kinase inhibitors

Tratamento adjuvante com minoxidil oral para tratamento de alopecia areata refratária a inibidores de JAK

DOI: <http://www.dx.doi.org/10.5935/scd1984-8773.20201211512>

ABSTRACT

Janus kinase inhibitors have changed the therapeutic paradigm of severe alopecia areata therapy. Some patients are refractory to dosage escalating. In this article, we describe the applicability of adjuvant oral minoxidil therapy.

Keywords: Alopecia; Alopecia Areata; Hair Janus Kinases; Minoxidil

RESUMO

Inibidores de Janus quinase mudaram o paradigma terapêutico de alopecia areata grave. Alguns pacientes são refratários ao aumento da dosagem. Neste artigo, descrevemos a aplicabilidade da terapia adjuvante com minoxidil oral.

Palavras-chave: Alopecia; Alopecia areata; Cabelo; Janus Quinases; Minoxidil

While Janus kinase (JAK) inhibitors have changed the therapeutic landscape of severe alopecia areata (AA), not every patient with AA responds to JAKi, and other treatment challenges remain: (1) Some patients require increased doses of JAK inhibitor to achieve hair regrowth; (2) Disease relapse can occur despite ongoing treatment; (3) If disease relapse occurs after treatment discontinuation, the same hair regrowth as occurred with initial treatment may not occur with retreatment.

In 1987, a study of oral minoxidil, 5mg twice daily, for the treatment of AA showed that 20% of patients achieve cosmetically acceptable hair growth.¹ Recently, we observed that tofacitinib used in combination with oral minoxidil may be more efficacious than tofacitinib monotherapy in patients with severe AA.² Here we present 3 patients with AA undergoing monotherapy with tofacitinib or ruxolitinib in which there was no efficacy or waning efficacy; in each case, adding (adjuvant) oral minoxidil (AOM) produced an excellent response (Figures 1 and 2).

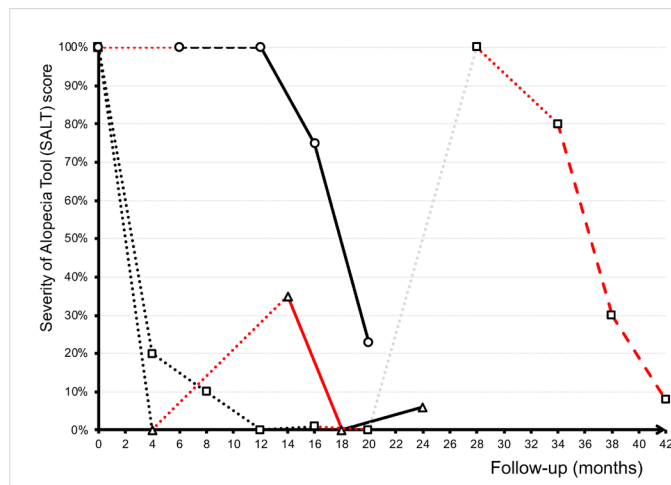


FIGURE 1: Longitudinal Severity of Alopecia Tool (SALT) scores of patients undergoing Janus kinase (JAK) inhibitor treatment.

Dotted lines: prior to and after starting adjuvant oral minoxidil (AOM). **Continuous lines:** minoxidil 2.5mg twice daily. Dashed line: minoxidil 2.5mg daily. Red lines: higher dose (tofacitinib 15-20mg per day in divided doses). Black lines: standard dose (tofacitinib 5mg twice daily or ruxolitinib 25mg twice daily [short dashes]). Light gray line: discontinuation of prescription. The indication for AOM was: Disease relapse during treatment with JAK inhibitor (Δ), decreased retreatment efficacy (\square), and poor response to JAK inhibitor monotherapy (O). After starting AOM, hair regrowth is apparent (illustrated by decreasing SALT scores).

In some patients who are refractory to JAKi monotherapy, AOM may offer a solution. In our experience, the response to adjuvant treatment is typically seen 3–6 months after initiation of

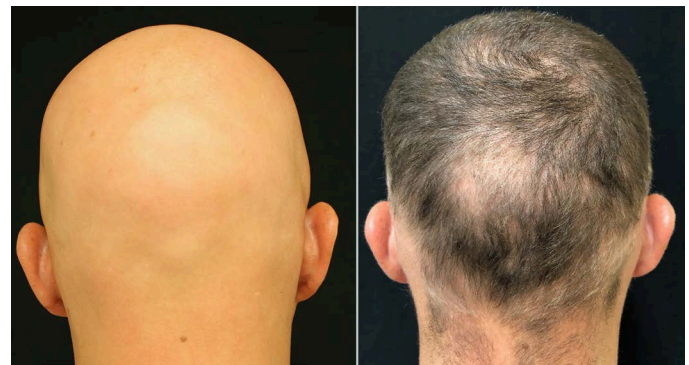

FIGURE 2: Alopecia areata unresponsive to JAK inhibitor monotherapy. Left: After 6 months of ruxolitinib 25 mg twice daily, Severity of Alopecia Tool (SALT) score was 100% (same as prior to starting ruxolitinib). Right: Nine months after starting adjuvant oral minoxidil (AOM), SALT score was 23%.

AOM (2,5mg, once or twice daily). Combination therapy may improve efficacy of JAKi, thereby limiting the need to escalate dosage, which is costly and potentially increases the risks for adverse effects. Additional studies will be important to better understand the optimal use of oral minoxidil in combination with JAKi. ●

REFERENCES

1. Fiedler-Weiss VC, Rumsfeld J, Buys CM, West DP, Wendrow A. Evaluation of Oral Minoxidil in the Treatment of Alopecia Areata. *Arch Dermatol.* 1987;123(11):1488-90.
2. Wambier CG, Craiglow BG, King BA. Combination tofacitinib and oral minoxidil treatment for severe alopecia areata. *J Am Acad Dermatol.* 2019;pii:S0190-9622(19)32688-X. Epub 2019 Sep 6.

AUTHORS' CONTRIBUTIONS:

Carlos Gustavo Wambier | ORCID 0000-0002-4636-4489

Statistical analysis; approval of the final version of the manuscript; study conception and planning; elaboration and writing of the manuscript; data collection, analysis, and interpretation; effective participation in orientation of the research; critical review of the literature; critical revision of the manuscript.

Brittany G. Craiglow | ORCID 0000-0001-8970-7691

Statistical analysis; approval of the final version of the manuscript; study conception and planning; elaboration and writing of the manuscript; data collection, analysis, and interpretation; effective participation in orientation of the research; critical review of the literature; critical revision of the manuscript.

Brett A. King | ORCID 0000-0002-4576-4616

Statistical analysis; approval of the final version of the manuscript; study conception and planning; elaboration and writing of the manuscript; data collection, analysis, and interpretation; effective participation in orientation of the research; intellectual participation in the propaedeutic and/or therapeutic conduct of the cases; critical review of the literature; critical revision of the manuscript.