

# Treatment of actinic cheilitis with daylight photodynamic therapy - clinical and histopathological evaluation

Tratamento da queilite actínica com terapia fotodinâmica com a luz do dia - avaliação clínica e histopatológica

DOI: <http://dx.doi.org/10.5935/scd1984-8773.20191141462>

## ABSTRACT

**Introduction:** Actinic cheilitis (AC) is a premalignant condition resulting from chronic sun exposure that affects the lower lip vermilion. Daylight Photodynamic Therapy (DL-PDT) is a new alternative to conventional therapy, being more straightforward, more accessible, and with better tolerability.

**Objective:** To evaluate the efficacy and applicability of DL-PDT in the treatment of AC and to determine the most prevalent adverse events.

**Material and Methods:** Experimental study, uncontrolled clinical trial type. The included patients were selected based on clinical and histopathological diagnosis of AC. Aminolevulinic acid was applied to the lower lip, and the sun exposure was conducted (3 sessions/ 2-week interval). We performed pre and post-treatment biopsies, took photographs for documentation, and filled out a default form.

**Results:** The study included 11 patients (63.6% men); mean age 59 years, and predominance of Fitzpatrick skin phototype II (45.4%). We observed a statistically significant clinical improvement ( $p = 0.026$ ), but not histologically confirmed. The adverse events were minimal (46% asymptomatic).

**Conclusions:** The study evaluated the efficacy and applicability of DL-PDT in the treatment of AC and determined the prevalent adverse events, motivating, and supporting future studies.

**Keywords:** Hyaluronic acid; Skin aging; Skin care

## RESUMO

**Introdução:** A queilite actínica (QA) é uma condição pré-maligna resultante da exposição crônica ao sol que afeta o vermhão do lábio inferior. A terapia fotodinâmica com luz do dia (TFD-LD) consiste em recente alternativa à forma convencional, sendo mais simples, acessível e com melhor tolerabilidade.

**Objetivo:** avaliar a eficácia e aplicabilidade da TFD-LD no tratamento da QA e determinar efeitos adversos prevalentes.

**Material e Métodos:** Estudo experimental, tipo ensaio clínico não controlado. Os pacientes incluídos foram selecionados com base no diagnóstico clínico e histopatológico de QA. Foi aplicado ácido aminolevulinico no lábio inferior e realizada fotoexposição (três sessões/ intervalo de duas semanas). Foram realizadas biópsias pré e pós-tratamento, fotografias para documentação e preenchimento de formulário padrão.

**Resultados:** Incluídos 11 indivíduos (63,6% homens), com idade média de 59 anos e predomínio do fototipo II (45,4%). Houve melhora clínica estatisticamente significativa ( $p=0,026$ ), não confirmada histologicamente. Efeitos adversos foram mínimos (46% assintomáticos).

**Conclusões:** O estudo avaliou a eficácia e aplicabilidade da TFD-LD no tratamento da QA e determinou os efeitos adversos prevalentes, motivando e embasando estudos futuros.

**Palavras-chave:** Ácido hialurônico; Envelhecimento da pele; Higiene da pele

## Original Article

### Authors:

Isabella Lemos Baltazar<sup>1</sup>

Flávia Regina Ferreira<sup>1</sup>

Luiz Fernando Costa Nascimento<sup>2</sup>

Samuel Henrique Mandelbaum<sup>1</sup>

<sup>1</sup> Dermatology Service of the Hospital Municipal Universitário de Taubaté, Universidade de Taubaté, Taubaté (SP), Brazil.

<sup>2</sup> Department of Energy, Universidade Estadual Paulista "Júlio de Mesquita Filho", Guaratinguetá (SP), Brazil.

### Correspondence:

Isabella Lemos Baltazar

Av. Granadeiro Guimarães, 270 Centro

12020-130 Taubaté (SP), Brazil

E-mail: [isabellalb@gmail.com](mailto:isabellalb@gmail.com)

Received on: 07/10/2019

Approved on: 29/11/2019

Study conducted at the Hospital Municipal Universitário de Taubaté, Universidade de Taubaté (SP), Brazil.

**Financial support:** Supply of aminolevulinic acid (Metvix®) by Galderma company.

**Conflict of interest:** Study sponsored by Galderma with supply of aminolevulinic acid (Metvix®); however, all methodology, execution and analysis of the results obtained were conducted by the researchers from the institutions involved, with no interference from the pharmaceutical industry.



## INTRODUCTION

Actinic cheilitis (AC) is a pre-malignant condition resulting from chronic exposure to the sun that affects the vermilion of the lower lip.<sup>1,2</sup> Clinically, erythema, edema, atrophy, hyperkeratosis, and erosions /ulcerations characterized this condition. Histologically, the main diagnostic criteria include atypia and loss of keratinocyte polarity associated with elastosis and inflammatory infiltrate.<sup>3</sup>

Daylight photodynamic therapy (DL-PDT) is a new therapeutic alternative to conventional photodynamic therapy (C-PDT), with similar efficacy in the treatment of actinic keratoses (grades I and II) of the face and scalp, and it also has reports of its use in AC.<sup>1,4</sup> It is a simplified method, more accessible and with better tolerability due to the absence of occlusion and the use of daylight instead of an artificial light source.<sup>4,5</sup>

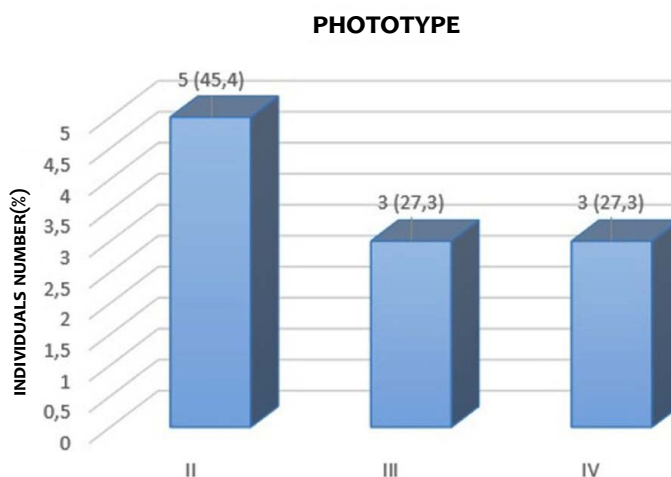
Based on the above, this study aimed to assess the effectiveness and applicability of DL-PDT in the treatment of AC and determine its prevalent adverse events.

## MATERIALS AND METHODS

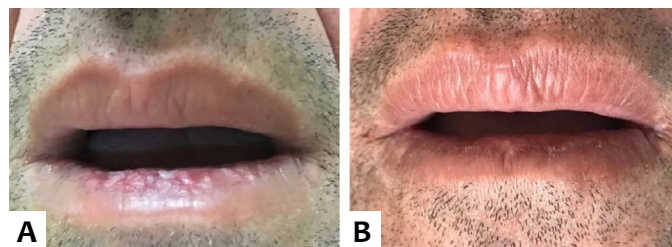Experimental study, uncontrolled clinical trial type, conducted at the Dermatology Service of Hospital Municipal Universitário de Taubaté (SP), Brazil, between March and December 2018. The patients included came from spontaneous demand and were selected based on the clinical and histopathological diagnosis of AC. Before the treatment, the clinically most affected area was biopsied for diagnostic confirmation and subsequent comparison. Aminolevulinic acid – MAL 160mg/g (Metvix® cream, Galderma, São Paulo, Brazil) was applied: on the lower lip and on a strip of approximately 5mm of adjacent skin. Scabs and scales were carefully removed before application. Three sessions were held with an interval of two weeks. The rest of the face was protected with a physical filter. After 30 minutes of the application, the patients remained outdoors for two hours (between 8 am and 10 am), with a minimum of 10 minutes of direct sun exposure to the area to be treated. Then, the product was removed, and the researcher observed the local reaction, asking the patient about symptoms during the procedure. After the procedure, the patients were instructed to remain indoors for the remainder of the day and to keep strict photoprotection throughout the treatment period. The patients were photographed before and after each session and also before the treatment start, as well as two weeks and three months after the last DL-PDT session. Two weeks after the last session, a new biopsy was performed. An experienced dermatopathologist assessed pre- and post-treatment biopsies. The histopathological criterion considered was the degree of epidermal dysplasia (atypia), classified as mild, moderate, and severe. The researcher assessed the clinical improvement of the lesion, considering erythema, edema, atrophy, hyperkeratosis, and erosions/ ulcerations and graded it in percentages: 0% (no improvement), 50% (partial improvement), and 100% (complete improvement). The statistical analysis used the Wilcoxon nonparametric test for dependent samples. Adopted  $\leq 10\%$ . The research was approved by the Institution's Research Ethics Committee under number 2.600.287.

## RESULTS

The study included 11 patients: 7 (63.6%) men and 4 (36.4%) women. The age of the sample ranged from 39 to 79 years, with an average of 59.3 years (SD = 14.4), among men, and 59.2 years (SD = 16.8) among women. There was no variation in the mean age between genders ( $p = 0.99$ ). The sample skin phototype varied from II to IV according to the Fitzpatrick classification, with the skin phototype II (45.4%) predominating (Graph 1). The comparison between the parameters of the initial and final clinical evaluation showed a statistically significant improvement ( $p = 0.026$ ). Also, the improvement in the clinical aspect was quite significant (Figures 1a and 1b). Regarding the adverse events after the procedure, in decreasing order of frequency, the following were observed: asymptomatic (46%), pruritus (27%), discomfort (18%), and mild pain (9%). In the week after the procedure, peeling and dry lips predominated (42%). Only one patient presented a first-degree burn on the lip after the first session, an effect that was not repeated.



**GRAPH 1:** Distribution of sample individuals according to skin phototype



**FIGURE 1:** Actinic cheilitis on the lower lip. **A.** Before (left) and after, **B.** (right) 3 months from the last DL-PDT session

TABLE 1: HISTOPATHOLOGICAL EVALUATION - PRE- AND POST-DL-PDT -, DIAGNOSIS AND DYSPLASIA DEGREE

Patient	Age	Sex (in years)	Phototype	BIOPSY PRE-DL-PDT-LD		BIOPSY POST-DL-PDT	
				Diagnosis	ATYPIA	Diagnosis	ATYPIA
1	75	M	II	Actinic cheilitis	1	Keratosis And Solar Elastosis	0
2	47	M	IV	Actinic cheilitis	1	Actinic cheilitis	1
3	62	M	III	Actinic cheilitis	1	Actinic cheilitis	1
4	60	M	II	Actinic cheilitis	2	Actinic cheilitis	2
5	53	M	II	Actinic cheilitis	1	Actinic cheilitis	2
6	39	M	III	Actinic cheilitis	1	Actinic cheilitis	1
7	79	F	IV	Actinic cheilitis	2	Elastose Solar	0
8	67	F	III	Actinic cheilitis	3	Queilite Crônica	0
9	49	F	II	Actinic cheilitis	1	Actinic cheilitis	3
10	42	F	II	Actinic cheilitis	2	Queilite Crônica	0
11	79	M	IV	Actinic cheilitis	2	Actinic cheilitis	1

Atypia - 1= Mild; 2= Moderate; 3= Severe

ted in the following sessions. Regarding histopathological evaluation, the 11 initial biopsies confirmed actinic cheilitis, and the degree of dysplasia (atypia) found was: mild in 6 lesions (54.5%), moderate in 4 lesions (36.4%), and severe in 1 lesion (9, 1%). There was no significant reduction in the degree of dysplasia when comparing these with post-treatment biopsies ( $p = 0.23$ ) (Table 1).

## DISCUSSION

This is a pioneering study in Brazil using DL-PDT in the AC treatment. It corroborates the scarce literature on the topic, which made it difficult to discuss the findings. Mean age, sex, and skin phototype were in agreement with the researched literature.<sup>2,3,6</sup> The improvement in clinical parameters proved to be

statistically significant and in agreement with the findings by Berking *et al.* and Ribeiro *et al.*, who used C-PDT, and Levi *et al.*, who used DL-PDT.<sup>1,3,7</sup> As for the histological parameter, the absence of statistically significant improvement was controversial and agreed with the findings of Berking *et al.*, in which 43% of patients with complete clinical cure still had residual disease.<sup>1,7</sup> The adverse events observed (pruritus, discomfort, and mild pain) agreed with those described for this modality and confirmed its better tolerability.<sup>1,4</sup>

## CONCLUSIONS

This study allowed to assess the effectiveness and applicability of DL-PDT in the treatment of AC and to determine its prevalent adverse events, serving as a basis and motivating future studies. ●

## REFERENCES

1. Levi A, Wulf HC, Enk CD. Two cases of actinic cheilitis responsive to daylight-activated photodynamic therapy (DA-PDT). *Photodermatol Photoimmunol Photomed*. 2013;29(5):268-71.
2. Araújo CP, Vidal MTA, Gurgel CAS, Ramos EAG, Barbosa Junior AA, Ramalho LMP, et al. Queilite actínica: um estudo de 35 casos com destaque para os aspectos morfológicos. *RPG Rev Pós Grad*. 2012;19(1):21-7.
3. Ribeiro CF, Souza FHM, Jordão JM, Haendchen LC, Mesquita L, Schmitt JV, et al. Photodynamic therapy in actinic cheilitis: clinical and anatomicopathological evaluation of 19 patients. *An Bras Dermatol*. 2012;87(3):420-5.
4. Galvão LEG. Daylight photodynamic therapy: clinical and aesthetic benefit with repeated sessions for facial actinic keratoses. *Surg Cosmet Dermatol*. 2016;8(4 Supl. 1):S40-2.
5. Wiegell SR, Haedersdal M, Philipsen PA, Eriksen P, Enk CD, Wulf HC. Continuous activation of PpIX by daylight is as effective as and less painful than conventional photodynamic therapy for actinic keratoses - a randomized, controlled, single-blinded study. *Br J Dermatol*. 2008;158(4):740-6.
6. Markopoulos A, Albanidou-Farmaki E, Kayavis I. Actinic cheilitis: clinical and pathologic characteristics in 65 cases. *Oral Dis*. 2004;10(4):212-6.
7. Berking C, Herzinger T, Flaig MJ, Brenner M, Borelli C, Degitz K. The efficacy of photodynamic therapy in actinic cheilitis of the lower lip: a prospective study of 15 patients. *Dermatol Surg*. 2007;33(7):825-30.

## AUTHORS' CONTRIBUTIONS:

**Isabella Lemos Baltazar** |  ORCID 0000-0002 9731 4414

Statistical analysis; approval of the final version of the manuscript; study design and planning; preparation and writing of the manuscript; data collection, analysis, and interpretation; intellectual participation in propaedeutic and/or therapeutic conduct of studied cases; critical literature review.

**Flávia Regina Ferreira** |  ORCID 0000-0001 5679 4282

Approval of the final version of the manuscript; study design and planning; preparation and writing of the manuscript; data collection, analysis, and interpretation; active participation in research orientation; intellectual participation in propaedeutic and/or therapeutic conduct of studied cases; critical literature review; critical revision of the manuscript.

**Luiz Fernando Costa Nascimento** |  ORCID 0000-0001 9793 750X

Statistical analysis.

**Samuel Henrique Mandelbaum** |  ORCID 0000-0002 4631 4828

Study design and planning.