

Diagnostic imaging

Authors:

Francisco Macedo Paschoal^{1,2}
 Andressa Sobral Soares de Deus¹
 Anelise Damiani da Silva Citrin¹
 Gisele Gargantini Rezze²

¹ Department of Dermatology, Centro Universitário Saúde ABC – Santo André (SP), Brazil.

² Dermaimage Medical Associates – São Paulo (SP), Brazil.

Correspondence:

Francisco Macedo Paschoal
 Av. General Furtado do Nascimento, 740
 cj.24
 05465-070 – São Paulo, SP, Brasil
 Email: frpasch@uol.com.br

Received on: 10/04/2019

Approved on: 01/06/2019

This study was carried out at Department of Dermatology of Centro Universitário Saúde ABC, Santo André (SP), Brazil.

Financial support: None

Conflict of interests: None



Reflectance confocal microscopy as a tool for assessing the injury caused by microneedling: a serie of five cases

Microscopia confocal de reflectância como ferramenta para avaliar os efeitos causados pelo microagulhamento: uma série de cinco casos

DOI: <http://www.dx.doi.org/10.5935/scd1984-8773.201911202>

ABSTRACT

Microneedling is an ambulatory surgical procedure that can be used for different indications with the objective of stimulating the production of collagen. Five cases were evaluated in the first 72 hours after the procedure by reflectance confocal microscopy in order to evaluate the pores lifetime.

Keywords: Collagen; Wound healing; Ambulatory surgical procedures

RESUMO

O microagulhamento é um procedimento cirúrgico ambulatorial que pode ser utilizado para diferentes indicações com o objetivo de estimular a produção de colágeno. Foram avaliados 5 casos no transcorrer das 72 horas após o procedimento, por meio da Microscopia Confocal de Reflectância, com o objetivo de avaliar a vida útil dos orifícios.

Palavras-chave: Colágeno; Cicatrização; Procedimentos cirúrgicos ambulatoriais

INTRODUCTION

Microneedling has been used as minimally invasive technology for the treatment of various dermatological conditions such as acne scars, stretch marks and skin rejuvenation.^{1, 2} It has also been applied aimed at increasing the absorption of drugs via transdermal route, creating pores in the epidermis and papillary dermis.^{3, 4} Nevertheless, few studies have evaluated its initial effects within the epidermis and dermis. Therefore, the authors of the present paper have studied a series of cases through confocal reflectance microscopy (CRM), which is an *in vivo* auxiliary examination that allows the visualization of different levels of the skin with histological resolution.⁵

FIVE CASE REPORTS

A total of five patients with acne scars and skin photoaging who have signed a Free and Informed Form of Consent were included in the present study. Confocal reflectance microscopy images were acquired through a laser scanning confocal microscope with reflection close to that of the infrared (Vivascope 3000®, Caliber I. D, Rochester, NY, US), from the *stratum corneum* to the papillary dermis (horizontal cuts), at the right temple. One hour after of topical anesthesia had been applied (Pliaglis®, Galderma, São Paulo, SP, Brazil), microneedling was performed with the assistance of the Derma Roller device (Fabinject Technology, Taubaté, São Paulo, Brazil). The device had 540 microneedles with 1.5mm in length and was applied in the whole face aimed at causing punc-

tate bleeding on the total facial area. The application region was evaluated by CRM immediately after (T0), 24 hours after (T1), 48 hours after (T2) and 72 hours after (T3) the procedure. All patients were advised not to apply any topical cream to the facial skin between CRM assessments. The CRM evaluation conducted at T0 evidenced a black linear cleft extending from the top of the epidermis to the papillary dermis – being more triangular in the dermis (Figure 1) – in all cases. At T1 and T2, the cleft has become a black circular structure in the upper epidermis (*stratum corneum*), in the epidermis and in the dermo-epidermal junction. Some of them contained a mild and bright substance. In the dermis, these black areas presented bright particles at T1 (Figure 1).

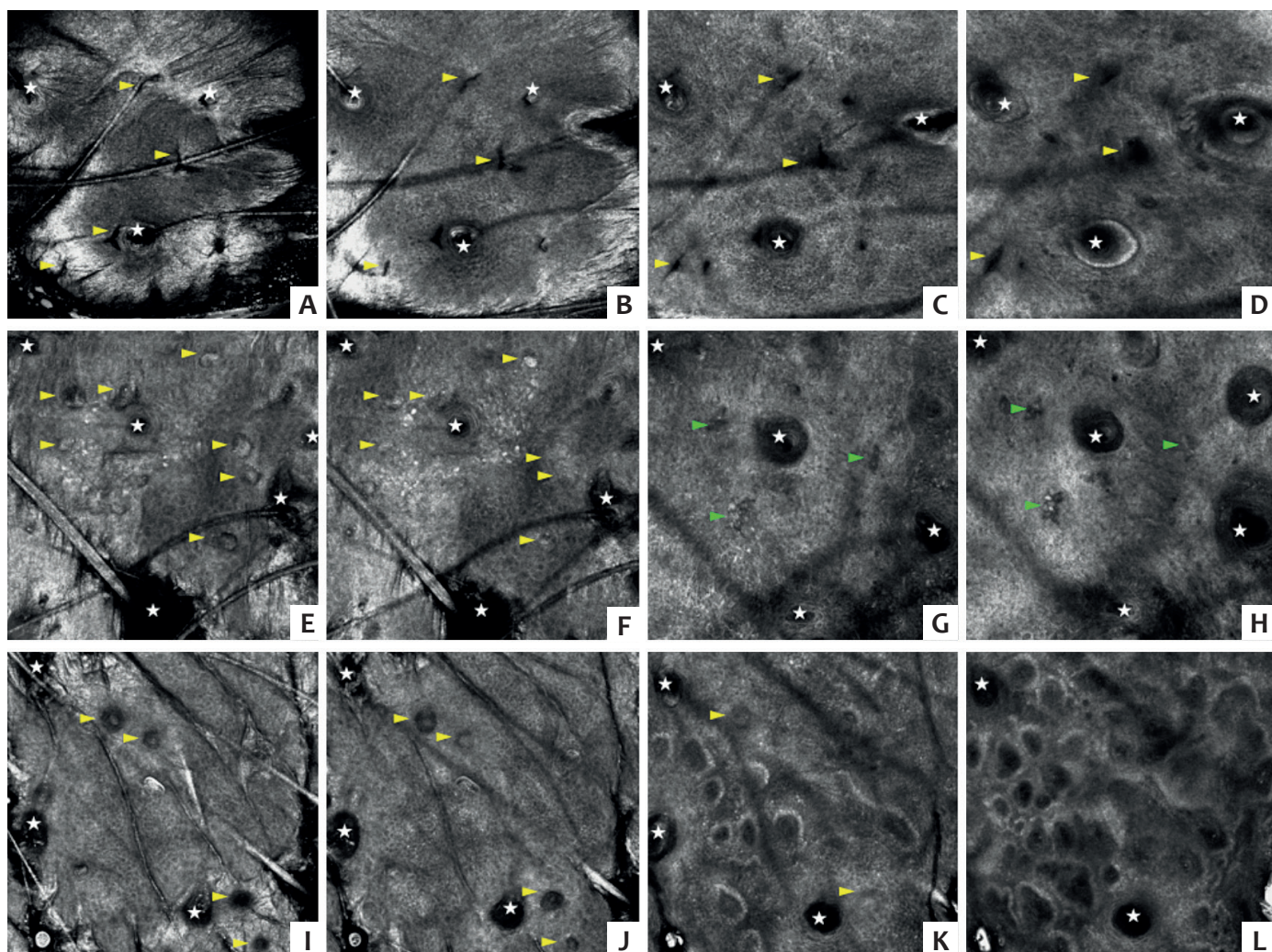


FIGURE 1: CRM images (500x500µm).

A, B, C and D. T0: Stratum corneum, supra-basal layer, dermoepidermal junction and papillary dermis, respectively, showing black fissures (yellow arrowheads) and follicular openings (white stars).

E and F. T1: Supra-basal and suprabasal/dermoepidermal junction layers, respectively showing circular black structures containing a light and substance (yellow arrowheads) and follicular openings (white stars).

G and H. T1: Dermoepidermal/papillary dermis layers and papillary dermis showing black areas with bright particles (green arrowheads) and follicular openings (white stars).

I, J and K. T2: Stratum granulosum, suprabasal layer and dermoepidermal junction, respectively, showing circular black structures containing a bright substance (yellow arrowheads) and follicular openings (white stars).

L. T2: Papillary dermis with absence of orifices, showing follicular openings (white stars).

DISCUSSION

Microneedling has been increasingly used in dermatology for cosmetic reasons due to its easy application technique and rare complications. It also appears promising for drug delivery since the stratum corneum is the major barrier for transdermal drug delivery and can be punctured by microneedles that mechanically pierce the skin layers leading to the transdermal absorption of the drug.^{3,4}

Using a new technology (CRM), the present study allowed the observation of perforations in the skin resulting from microneedling. The presence of the orifices in the epidermis and dermis, possibly increasing the skin's permeability – which is essential for the concept of transdermal drug release – is noticed immediately after microneedling (T0). The presence of a mild and bright substance in the epidermis' pores at T1, T2 and T3 may correspond to local subclinical inflammation responsible

for micropore occlusion. This physiological process is not yet known, however it is believed that the micropore may close in a matter of hours.^{3,4} The finding of black areas with bright particles inside the papillary dermis allows the authors of the present paper to hypothesize whether it could correspond to inflammation caused by the micro injuries, leading to neovascularization and neocollagenesis, involved in skin rejuvenation.⁴

CONCLUSION

Finally, little is known about the useful life of the orifices and the injury caused by the treatment with microneedles. Therefore, the authors of the present article believe that CRM may be useful for unprecedented visualization of microneedling's mechanical and inflammatory events. ●

REFERENCES

1. Andrade LE. Microneedling in facial recalcitrant melasma: report of a series of 22 cases. *An Bras Dermatol*. 2015;90(6):919-21.
2. Singh A, Yadav S. Microneedling: Advances and widening horizons. *Indian Dermatol Online J*. 2016;7(4):244-54.
3. Badran MM, Kuntsche J, Fahr A. Skin penetration enhancement by a microneedle device (Dermaroller) in vitro: dependency on needle size and applied formulation. *Eur J Pharm Sci*. 2009;36(4-5):511-23.
4. Vandervoort J, Ludwig A. Microneedles for transdermal drug delivery: a minireview. *Front Biosci*. 2008;13:1711-5.
5. Langley RG, Rajadhyaksha M, Dwyer PJ, Sober AJ, Flotte TJ, Anderson RR. Confocal scanning laser microscopy of benign and malignant melanocytic skin lesions in vivo. *J Am Acad Dermatol*. 2001;45(3):365-76.

DECLARATION OF PARTICIPATION:

Francisco Macedo Paschoal |  ORCID 0000-0002-6264-1538

Approval of the final version of the manuscript; study design and planning; preparation and Drafting of the manuscript; data collection, analysis and interpretation; research guidance; intellectual participation in propaedeutic and / or therapeutic approach of the cases studied; critical review of the literature; critical review of the manuscript.

Andressa Sobral Soares de Deus |  ORCID 0000-0002-8569-4229

Study design and planning; preparation and Drafting of the manuscript; data collection, analysis and interpretation; intellectual participation in the propaedeutic and / or therapeutic approach of the cases studied; critical review of the literature.

Anelise Damiani da Silva Citrin |  ORCID 0000-0002-2986-6188

Preparation and Drafting of the manuscript.

Gisele Gargantini Rezze |  ORCID 0000-0001-9084-4634

Approval of the final version of the manuscript, preparation and drafting of the manuscript; data collection, analysis and interpretation; research guidance; critical review of the literature; critical review of the manuscript.