

Cryobiopsy in dermatological practice

Criobiópsia na prática dermatológica

DOI: <http://www.dx.doi.org/10.5935/scd1984-8773.20191111217>

ABSTRACT

Skin biopsy is an important introductory tool and also essential for the dermatologist. The conventional biopsy method, with the use of local anesthetics, sterile fields, surgical instruments (*punch*, scalpel, forceps, scissors) and suture material demand staff, time and considerable financial investment. Cryobiopsy is a simple method, where by using the cryocautery an extraction of good quality skin fragments is made for histopathologic analysis, making it an excellent alternative to the conventional biopsies.

Keywords: Ambulatory Surgical Procedures; Biopsy; Cryosurgery; Dermatology; Histology

RESUMO

A biópsia de pele é ferramenta propedêutica importante e indispensável para o médico dermatologista. O método convencional de biópsia, com a utilização de anestésicos locais, campos estéreis, instrumental cirúrgico (*punch*, bisturi, pinças, tesoura) e fios de sutura, exige equipe, tempo e considerável investimento financeiro. A criobiópsia é método simples, que, por meio do criocautério, faz a extração de fragmentos de pele de boa qualidade para análise histopatológica, o que a torna excelente alternativa às biópsias convencionais.

Palavras-chave: Biópsia; Criocirurgia; Dermatologia; Histologia; Procedimentos Cirúrgicos Ambulatoriais

INTRODUCTION

The histological study of skin fragments is an indispensable propaedeutic method in the daily routine of dermatologists. Conventional skin biopsies require sterilized surgical instruments, operating room, nursing team and longer surgical time, as well as local anesthesia, which can cause pain and distress in patients who have phobia to needles.¹ In Brazil, there is a complicating factor since the issuance of Resolution CFM (Brazilian Federal Council of Medicine) N°. 2,056/2013, requiring that premises where procedures using local anesthesia are carried out be furnished with minimal equipment and medication to deal with intercurrents, such as cardiorespiratory arrest and anaphylaxis – which makes mandatory that items such as emergency oxygen kits and aspirators, defibrillators, and vasoactive drugs be made available in the dermatological practice, a space in which small surgeries are performed. This requirement discourages the performance of conventional biopsies in dermatological practices. As a result, cryobiopsy becomes a good alternative to harvest cutaneous specimens to be studied.

How I do?

Authors:

Rachel de Avila Coelho¹

Luiz Fernando de Oliveira Santana²

Juliana Cristina Silva Fraga³

¹ Department of Dermatology, Military Police Hospital - Belo Horizonte (MG), Brazil

Correspondence:

Dr. Rachel de Avila Coelho

Rua Pacífico Mascarenhas, s/n

Santa Efigênia

30110-013, Belo Horizonte, MG

Brazil

E-mail: rachelavilacoelho@yahoo.com.br

Received on: 07/07/2018

Approved on: 11/04/2019

This study was performed at the Minas Gerais Military Police Hospital - Belo Horizonte (MG), Brazil.

Financial support: None

Conflict of interests: None



Technique description

The technique consists of:

1) Topical antisepsis of the site where the cryobiopsy will be performed.²

2) Spraying of liquid nitrogen over the lesion from a distance of 2.5 to 3.8cm, for 4 to 5 seconds, up until the complete freezing of the lesion, visually verified based on the whitening of the region (Figure 1).²

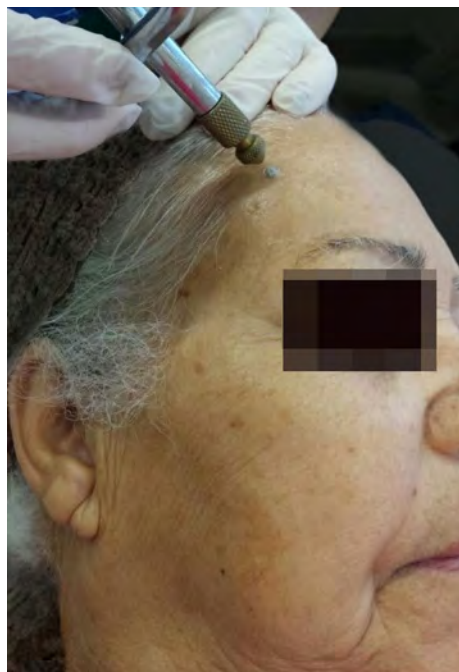

FIGURE 1: Spraying of liquid nitrogen on the lesion

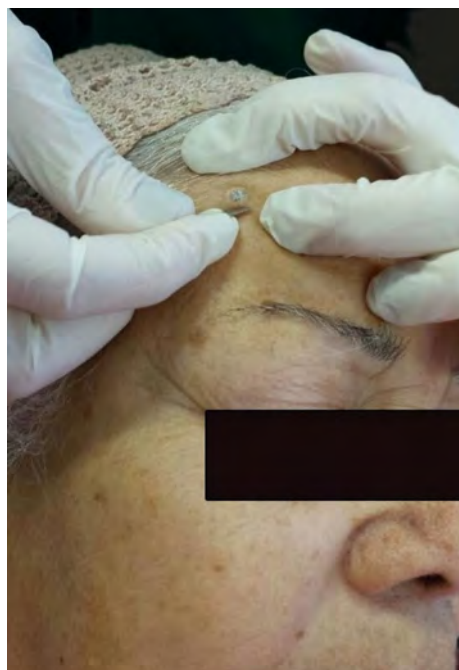

FIGURE 2: Shaving at the base of the lesion

3) Shaving at the base of the lesion, using a scalpel with n.15 blade, as soon as the thawing of the skin begins, while the tissue still offers some resistance (Figures 2 and 3).²

4) Once removed, the specimen is immediately transferred to a flask containing formaldehyde solution.²

5) Prior to the complete thawing of the skin, a swab soaked in 20% aluminum chloride is gently pressed onto the site for hemostasis (Figure 4).²

DISCUSSION

Cryobiopsy is a method used to obtain cutaneous specimens for histological analysis that uses equipment that is usually employed in dermatological practices and dismisses the use of local anesthetics and complex infrastructure to be performed.

The procedure is indicated for benign, pre-malignant lesions and non-melanoma skin cancers. Thus, the technique can

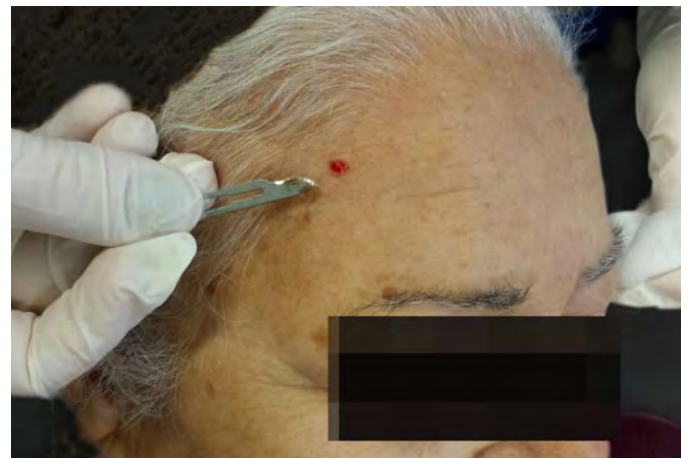

FIGURE 3: Complete excision of the lesion

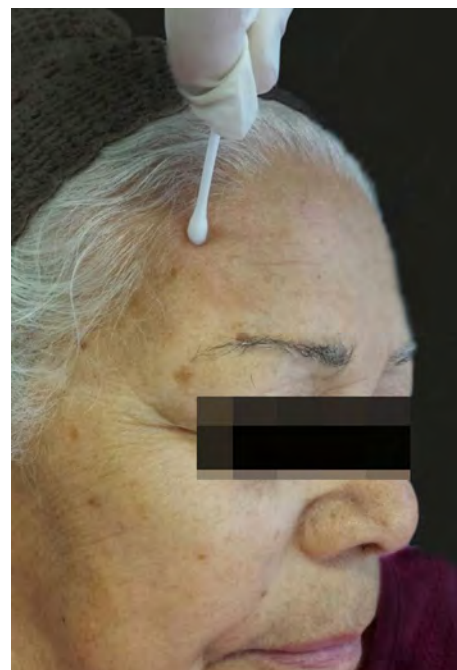

FIGURE 4: Local application of swab soaked in 20% aluminum chloride for hemostasis

be performed in most cases where routine biopsy is indicated (e.g. basal and squamous cell carcinomas, actinic keratoses, nevi and inflammatory or infectious lesions with dubious diagnosis – such as facial granuloma, annular granuloma, molluscum contagiosum, angiomas, soft fibromas, seborrheic keratoses, viral warts etc).^{2,3}

Few conditions limit the use of cryobiopsy, which should, nevertheless, not be performed in patients with pathologies that can be induced or exacerbated by exposure to cold – such as cryoglobulinemia, Raynaud's disease, cold-induced urticaria, and previous history of cold-induced injury – or in sites with poor blood circulation.⁴

Complications arising from the procedure are usually mild and dependent on the physician's familiarity with the technique. The most common is dyschromia, in special hypopigmentation, which is the most common type due to the destruction of melanocytes caused by the low temperature.⁴ In individuals with high skin phototypes, postinflammatory hyperpigmentation may also occur. The onset of depressed scars is a result of deep cryobiopsy, however it usually resolves spontaneously.⁴ In hairy areas, permanent cicatricial alopecia may occur, resulting from the destruction of the hair follicle by freezing. Finally, if cryobiopsy is performed on the nail matrix or cartilage (nasal or auricular), tissue distortion may occur secondarily to the formation of indentations or retractions.⁴

Regarding the quality of the obtained skin specimen via cryobiopsy, the histological analysis of the fragments does not show any tissue damage formation or artifacts in the evaluated pieces after they have been subjected to low temperatures (Figure 5). To avoid cell autolysis, the histological specimen is placed in formalin aiming at preserving the morphology and chemical composition of the tissue's components, which contributes to a reliable histological examination.⁵⁻⁷

CONCLUSION

The authors of the present study describe a new technique with a view to raising the awareness regarding a safe, almost painless, cost effective and efficacious procedure that can be of great value in the daily dermatological practice.

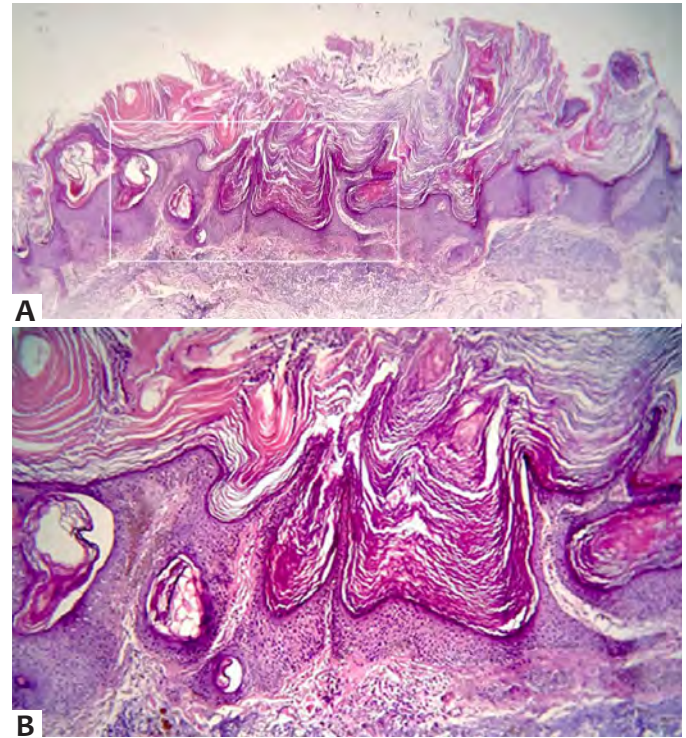


FIGURE 5: **A** - Hematoxylin & eosin cryobiopsy specimen slice under small magnification showing skin tumor characterized by hyperkeratosis, acanthosis, papillomatosis and corneal pseudocysts. **B** - Hematoxylin & eosin cryobiopsy specimen slice under greater magnification showing hyperkeratosis, acanthosis, papillomatosis, and corneal pseudocysts

In face of the new enforced legislation, the described technique is a viable alternative to most dermatologists and provides more agility in performing skin biopsies.

The promising experience of cryobiopsies in diverse fields of medicine, such as pneumology, which has been conducting tracheobronchial biopsies since the 1980s, demonstrates how dermatological surgery can still develop and benefit from the more frequent use of this technique.^{5,6,8-10} ●

REFERENCES

1. Pasquali P, Freitas-Martinez A, Fortuño-Mar A. Cryobiopsy: An alternative technique to conventional shavebiopsy. *J Am Acad Dermatol*. 2015;73(5):867-8.
2. Pasquali P, Freitas-Martinez A, Fortuño-Mar A. Use of cryobiopsy in dermatological practice. *J Am Acad Dermatol*. 2015;72(2):e63-4.
3. Pasquali P. The cryosurgery alternative. *Int J Dermatol*. 2007;46(5):511-3.
4. Prohaska J, Badri T. Cryotherapy. [Updated 2019 Apr 4]. In: StatPearls [Internet]. Treasure Island (FL): StatPearls Publishing; 2019 Jan-. Available from: <https://www.ncbi.nlm.nih.gov/books/NBK482319/>.
5. Casoni GL, Tomassetti S, Cavazza A, Colby TV, Dubini A, Ryu JH, et al. Transbronchial lung cryobiopsy in the diagnosis of fibrotic interstitial lung diseases. *PLOS ONE*. 2014;9(2):e86716.
6. Ohno N, Terada N, Saitoh S, Zhou H, Fujii Y, Ohno S. Recent development of in vivo cryotechnique to cryobiopsy for living animals. *Histol Histo-pathol*. 2007;22(11):1281-90.
7. Junqueira LCU, Carneiro J. *Histologia Básica: texto e atlas*. 4 ed. Rio de Janeiro: Editora Guanabara Koogan; 1979. p. 1.
8. Ohno N, Terada N, Bai Y, Saitoh S, Nakazawa T, Nakamura N, et al. Application of cryobiopsy to morphological and immune histochemical analyses of xenografted human lung cancer tissues and functional blood vessels. *Cancer*. 2008;113(5):1068-79.
9. Olariu B. Endoscopic cryobiopsy in tracheobronchial pathology. *Rev Chir Oncol Radiol O R L Oftalmol Stomatol Otorinolaringol*. 1983;28(3):225-7.
10. Hetzel J, Hetzel M, Hasel C, Moeller P, Babiak A. Old meets modern: the use of traditional cryoprobes in the age of molecular biology. *Respiration*. 2008;76(2):193-7.

DECLARATION OF PARTICIPATION:

Rachel de Avila Coelho |  ORCID 0000-0002-7947-7754

Approval of the final version of the manuscript, study design and planning, preparation and drafting of the manuscript, critical review.

Luiz Fernando de Oliveira Santana |  ORCID 0000-0002-7793-5360

Approval of the final version of the manuscript, study design and planning, preparation and drafting of the manuscript, critical review.

Juliana Cristina Silva Fraga |  ORCID 0000-0002-1593-8742

Approval of the final version of the manuscript, study design and planning, effective participation in the research guidance, intellectual participation in the propaedeutic and / or therapeutic approach of the cases studied, critical review of the literature, review of the manuscript.