

Suture with absorbable cones for facial rejuvenation: technique description and analysis of 21 patients

Sutura com cones absorvíveis para rejuvenescimento facial: descrição da técnica e análise de 21 pacientes

DOI: <http://www.dx.doi.org/10.5935/scd1984-8773.201810402>

ABSTRACT

Introduction: Injectable use of poly-L-lactic acid (PLLA), biocompatible absorbable polymer with a high capacity to stimulate collagen, is already well-established in Cosmetic Dermatology. PLLA lifting threads, studded with poly-L-lactic-co-glycolic (PLGA) cones, besides triggering neocollagenesis through subclinical inflammatory response, provide a *lifting* effect due to the traction caused by these cones. The interest in thread *lifting* is in evidence and needs detailed studies for the evaluation of treatment indications, complications, and efficacy.

Objectives: This study aimed at evaluating safety, efficacy and patient satisfaction in regards to rejuvenation after facial lifting using the absorbable suture.

Methods: Twenty-one patients with laxity of the middle and lower third of the face were selected and submitted to the treatment with lifting threads. A satisfaction questionnaire was applied.

Results: In this study, 71.4% of the patients reported great aesthetic result three months after the procedure. Side effects such as bruising, pain and uneven facial skin surface were described mainly on the first week after the procedure.

Conclusions: PLLA sutures with PLGA cones was effective for the treatment of mild to moderate facial laxity in well-indicated patients, and the side effects were minimal when compared to invasive techniques. These results should be confirmed by studies with a larger number of individuals.

Keywords: Ambulatory surgical procedures; Sutures; Rejuvenation

RESUMO

Introdução: O uso injetável do ácido poli-L-lático (PLLA), polímero biocompatível reabsorvível com alto poder de estímulo ao colágeno, já é consagrado na Dermatologia Cosmiátrica. Os fios de sustentação do PLLA, cravejados por cones de poli-L-lactídeo-co-glicolídeo (PLGA), além de desencadearem a neocolagênese por meio da resposta inflamatória subclínica, proporcionam um efeito *lifting* devido à tração proporcionada por estes cones. O interesse pelo *lifting* com fios está em evidência e necessita de estudos detalhados para avaliação de indicações, complicações e eficácia do tratamento.

Objetivos: Este estudo buscou avaliar a segurança, eficácia e satisfação do paciente em relação ao rejuvenescimento após *lifting* facial por meio da sutura absorvível.

Métodos: Foram selecionados e submetidos ao tratamento com fios de sustentação 21 pacientes que apresentavam flacidez no terço médio e inferior da face. Questionário de satisfação foi aplicado.

Resultados: No presente estudo, 71,4% dos pacientes relataram ótimo resultado estético após três meses da realização do procedimento. Efeitos colaterais, como equimose, dor e irregularidade da superfície facial, foram descritos principalmente na primeira semana após o procedimento.

Conclusões: A sutura de PLLA com cones de PLGA foi eficaz no tratamento da flacidez facial leve a moderada de pacientes bem indicados, e seus efeitos colaterais foram mínimos quando comparados aos de técnicas invasivas. Estes resultados devem ser confirmados por estudos com casuística maior.

Palavras-Chave: Procedimentos cirúrgicos ambulatoriais; Rejuvenescimento; Sutures

Original Articles

Authors:

Marina Macellaro¹

Maria Gabriela Ortiz Noronha¹

Nathalia Hatsue Oushiro¹

Renan Lage¹

¹ Dermatology Department, Pontifícia Universidade Católica de Campinas (PUC-Campinas), Campinas (SP), Brazil.

Correspondence:

Nathalia Hatsue Oushiro

Ambulatório de Dermatologia da PUC Campinas. Avenida John Boyd Dunlop s/n. Jardim Ipaussurama. Cep: 13060-904. Campinas-SP.

E-mail: nathalia.oushiro@gmail.com

Received on: 08/11/2018

Approved on: 05/12/2018

This study was performed in the Dermatology Department, PUC-Campinas, Hospital PUC-Campinas, Campinas (SP), Brazil.

Financial support: None.

Conflict of interests: None.



INTRODUCTION

The process of cutaneous aging is a result of both intrinsic and extrinsic factors. Age advancement leads to loss of skin quality, with fatty tissue atrophy, loss of bone mass, decreased fibroblast production of collagen¹, and reduction of mucopolysaccharides, such as proteoglycans and hyaluronic acid², leading to loss of facial volume and elasticity, resulting in deflation of the face.^{3,4,5}

The gold standard technique for moderate to severe intensity facial rejuvenation is rhytidectomy (face lift). However, there is a growing search for less invasive procedures, with a shorter recovery period and satisfactory results. According to the American Association of Aesthetic Plastic Surgery (ASAPS) from 1997 to 2016, rejuvenating cosmetic surgeries increased 19.5% while non-surgical procedures by increased 6,956.6%.³

Suspension threads were developed aimed at preventing and treating facial flaccidity in a minimally invasive way. They were initially made of non-resorbable material, such as gold⁶ and polypropylene⁶⁻⁹, which led to a series of complications and pain related complaints. With the advent of absorbable material threads, such as PLLA (poly-L-lactic acid), polydioxanone¹⁰, polytetrafluoroethylene^{11,12} and polyglactin⁷, better outcomes, fewer complications and higher tolerability were obtained. In 2004, the PLLA thread was patented and, in 2007, it was approved by the US Food and Drug Administration (FDA).¹³

Poly-L-lactic acid is a synthetic molecule that was discovered in France in 1954, and is derived from lactic acid, which is naturally produced by muscle contraction. It has a long history of use, particularly in orthopedic fixation devices such as pins, rods and screws. In Aesthetic Medicine, its injectable application, as a biostimulator of collagen, is widely use.¹⁴

The suture used in the present study has PLGA (Poly L-lactic-co-Glycolic Acid) cones that provide traction by means of two mechanisms: anchorage and minimal acute inflammatory reaction of the tissue, which is followed by a progressive encapsulation, thus avoiding the migration and extrusion of the thread.

Indications for suture suspension threads are: sagging, the middle third of the face's skin, the mandibular line, eyebrow ptosis, and loss of malar volume – especially in its mild and moderate forms and in patients with subcutaneous tissue that is not very well-marked.¹⁵ Other indications would be asymmetry due to facial paralysis with no possibility of functional restoration of the nerve, and for patients with contraindications to surgical procedures.¹³

The contraindications are: sensitivity to foreign bodies, known or suspected allergies to implant or instrumentation materials, active infection, autoimmune disease, pregnancy, lactancy or patients with limited ability to follow post-treatment recommendations.¹⁶

The aforementioned technique is minimally invasive and can be performed under local anesthesia and in an outpatient setting. It is applicable to various age groups for facial rejuvenation and remodeling. Outcomes are relatively long-lasting and satisfactory.¹³

The objective of this study was to evaluate the safety, efficacy and patient's satisfaction regarding rejuvenation effects after undergoing absorbable suture face-lift.

METHODS

Patient selection: PLLA absorbable suspension threads were used in 21 patients to treat facial aging during a 1-year period (from February 2017 to February 2018). The procedures were performed in the medical practice of one of the authors of the present article, in the city of Jundiaí (SP), Brazil. All patients with indication of treatment with suspension threads who answered a satisfaction questionnaire through the telephone during the aforementioned period were included. Patients with very thin skin, very advanced signs of aging and loss of follow-up were excluded. Consent for photographs and publication was duly obtained. The study followed the Declaration of Helsinki's guidelines.

The absorbable thread: The suspension thread chosen for the study was the Silhouette® suture (Silhouette InstaLift, Sinclair Pharma, Irvine, CA, USA). This absorbable suture is composed of poly-L-lactic acid (PLLA), a biodegradable and biocompatible polymer. It presents lengths of 26.8cm, 27.5cm and 30.0cm, with 8, 12 or 16 cones, respectively, arranged bidirectionally, which allows equal distribution of weight and tension in the face. The cones and nodes system provides a 360-degree surface for effective stitch anchoring by attaching the suture to the subcutaneous tissue.^{3,17}

Poly-L-lactic acid is absorbed over a period of 12 to 18 months. Ten percent of the cone-shaped anchors will be absorbed in the period of two to three months; 30% of them will be absorbed in three to six months; and all will be fully absorbed between six and 12 months.¹

The suspension thread is applied in the subcutaneous and, through the process of resorption, its components act by stimulating the fibroblasts and the production of collagen. This action, which continues over time, helps to increase the volume and restores the smoothness of the facial contour gradually and naturally.^{10,16}

The procedure:

Two to three PLLA threads were used with eight PLGA cones in each hemiface. The marking of the insertion points was performed with the patient in sitting position, with the spine erect, after a thorough analysis of the points of greatest flaccidity of the middle and lower thirds of the face as well as the respective traction vectors (as shown in Figure 1), aiming at a best lifting effect. The marking of the lower third has as its point of entry the angle of the mandible's region, with the marking of the threads' path being carried out inferiorly, in the direction of the mandible's angle and in the upper portion, towards the scalp and parallel to the ear, forming an approximate angle of 110°. The distance between the two exit points was of at least 12cm, reaching up to 18cm. It is recommended, as performed in the present cases, to go beyond the jawline, in order to better define

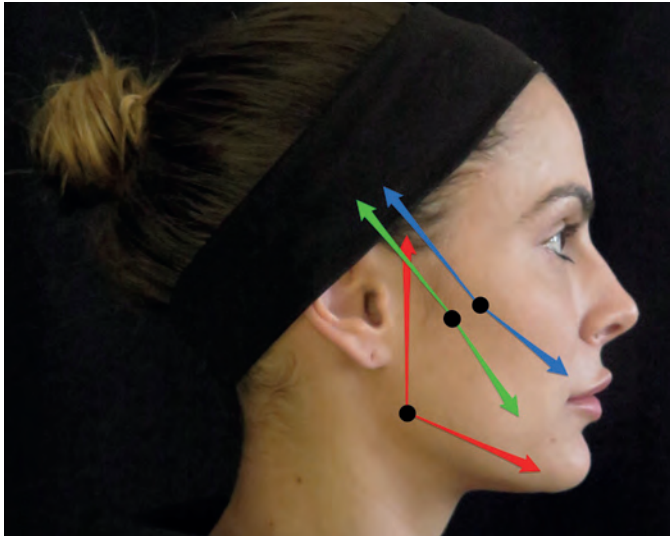


FIGURE 1: Insertion points and traction vectors

the contour of the mandible.

The marking of the middle third had as its point of entry a point in the lateral malar region for which greater volumization was desired. From this point of entry, a vector was defined which should be marked towards the nasogenian and/or labiomental groove, without transposition of these grooves, so that there is no anatomical distortion of the perioral region. A second vector is directed towards the scalp, and the marking is carried out with the exit of the thread, after implantation in the temporal region. As in the lower third of the face, the distance between the two exit points must be of at least 12cm. When a decision is made for using two or more threads, the entry points should be positioned up to 1cm apart, while the exit points near the nasolabial folds should be between 1cm and 4cm apart. The exit points in the temporal region may be close to each other.

With the patient in dorsal decubitus at 45°, skin antiseptis is performed with aqueous chlorhexidine and local anesthesia is applied using 2% Lidocaine with 1:100,000 Adrenaline at the points of entry and exit of the threads. After anesthesia, the suture is inserted perpendicularly to a depth of 0.6mm below the skin, in the subcutaneous, through an entrance orifice made with an 18G needle. The needle is then inserted horizontally towards the first exit point, always in the same subcutaneous plane, up until the total length of the thread goes through, with all the cones staying beneath the skin. The remainder of the thread is introduced in the same entry orifice, in the predetermined opposite direction. All threads are passed by following this same sequence, with all needles being kept up until the end of the procedure. The patient should then return to the 90° position so that the traction of the threads be performed. This traction is initially performed in the half closest to the medial region of the face, with one hand holding the thread close to its insertion in the needle and the other hand feeling the thread path with the aid of the surgeon's fingers, in order to facilitate the anchoring of

the cones, resulting in a slightly exaggerated traction of the treated region. This is repeated in all halves of the threads near the centofacial region and then in the more peripheral halves. The free ends of the sutures are trimmed at the exit points, after a slight pressure on this point, with the aid of the scissors, in order to properly bury the end of the thread. The application of the technique described in this article can be visualized in Video 1.

<https://vimeo.com/309535885>

Post-procedure: All patients were instructed to perform cold compresses, sleep in dorsal decubitus, avoid massaging the face, not floss and avoid intense opening of the mouth for seven days. They were allowed to use makeup after 72 hours; to perform physical activities after 15 days; and to undergo dental procedures 30 days after the surgery. Furthermore, patients were advised against performing excessive facial movements, chewing hard foods, contracting the perioral region (smoking or using straws) for two weeks after surgery to avoid rupture of the suture in the tissue, inflammation, pain, and tenderness. Instructions were offered regarding facial hygiene care and the use of topical substances.

Satisfaction questionnaire: All patients included in this study answered the satisfaction questionnaire regarding the presence of ecchymosis, facial surface irregularity and pain (on a mild, moderate or intense scale) weekly in the first three weeks after the procedure. Questions on the aesthetic outcome observed by the patient after 15 days were answered (on a poor, regular, good or excellent scale), one month and three months after the procedure. The questionnaire was administered via telephone calls.

RESULTS

This study included 21 patients with an average age of 50.8 years (ranging from 39 to 62 years), 19 women and 2 men. The authors used four to six PLLA threads per patient (average of 4.6 threads per face).

All patients reported ecchymosis and facial surface irregularity in the first week after the procedure, and 90.5% reported mild or moderate pain. After three weeks of the procedure, only one patient reported a local resolving ecchymosis with no patient reporting allergic complaints or cutaneous irregularity. Long-term complications and postoperative infections were not found (Tables 1, 2 and 3).

After 15 days, 38% of the patients reported excellent results; 47.6% reported good results; and 14.2%, regular results. After one month, 57.1% reported excellent results and 42.8% good results. After three months, 71.4% reported excellent results and 28.5% good results (Table 4). Figures 2 to 6 show the development of a patient who underwent the procedure described in this article and experienced moderate facial flaccidity, with indication for a face lift, however did not wish to undergo an invasive procedure.

TABLE 1: Evaluation of pain

Pain	Absent	Mild	Moderate	Strong
1 st Week	2 (9.5%)	16 (76.1%)	3 (14.2%)	0
2 st Week	16 (76.1%)	3 (14.2%)	0	0
3 st Week	21 (100%)	0	0	0

TABLE 2: Evaluation of ecchymosis

Ecchymosis	Present (%)	Absent (%)
1 st Week	21 (100)	0
2 st Week	9 (42.8)	12 (57.1)
3 st Week	1 (4.7)	20 (95.2)

TABLE 3: Evaluation of the cutaneous irregularities

Cutaneous irregularities	Present (%)	Absent (%)
1 st Week	21 (100)	0
2 st Week	5 (23.8)	16 (76.1)
3 st Week	0	21 (100)

DISCUSSION

The suspension technique using absorbable sutures is part of the wide range of non-invasive procedures available for rejuvenation.¹⁸ When indicated, it presents high rates of patient satisfaction, effectiveness and safety.³

The present study demonstrated an increasing development of patient satisfaction levels throughout the evaluated period, the procedure was considered excellent by 38% of the patients after 15 days, and by 71.4% of them after 3 months. These data are in line with previous statistics, such as those verified by Khiabanloo *et al.*¹⁹, who evaluated 193 patients after the use of absorbable threads, with a 75% satisfaction rate in the first week after the procedure and 96% after 6 months. Ogilvie *et al.*³ evaluated 100 patients who underwent Silhouette® thread suture, of which only 28 answered to the evaluation questionnaire. After one week, 79% were satisfied.

Regarding side effects, the questionnaire applied in the present study was restricted to pain, alteration of the cutaneous surface and ecchymosis. The reported levels of pain were mild to moderate, restricted to some cases, and had complete resolution by the third week (Table 1). Ecchymosis and facial surface alterations were predominant, however ephemeral, with satisfactory resolution by up to the third week (Tables 2 and 3). No serious side effects were reported.

Benito *et al.*¹³ performed 316 procedures, resulting in 42 complications (13.3%), all of which were simple and transient. There were no postoperative infections, which is in line to the findings of the present study. Other adverse reactions related to absorbable threads – in varying percentages – were hemorrhage, edema, papules, facial asymmetry and skin depression. It is im-

TABLE 4: Evaluation of the overall outcome

Results	Regular	Good	Excellent
15 days	3 (14.2%)	10 (47.6%)	8 (38.0%)
30 days	0	9 (42.8%)	12 (57.1%)
90 days	0	6 (28.5%)	15 (71.4%)

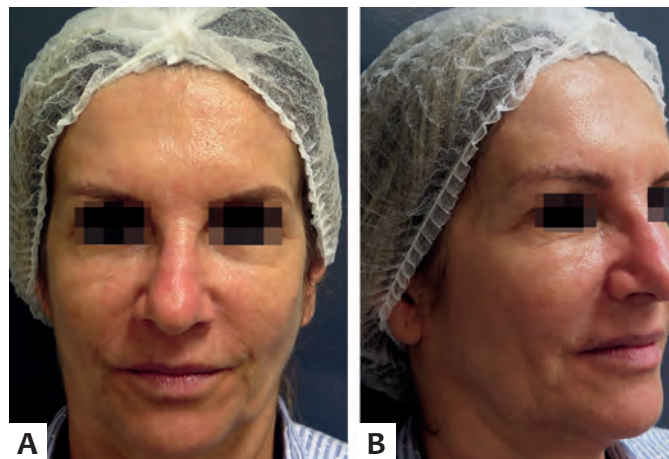


FIGURE 2: Do

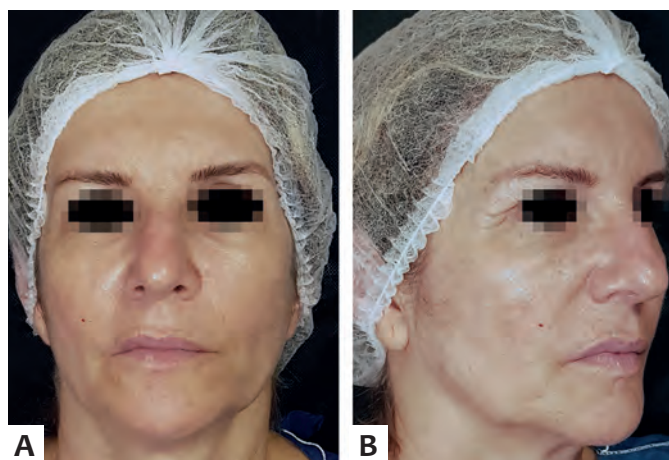


FIGURE 3: D3

portant to note that immunological or chemical reactions to an inert implant, though unlikely, might occur.¹³

Lycka *et al.*²⁰ evaluated 350 patients who underwent polypropylene anchored threads during a period of 36 months. Of these, 152 (43%) reported good outcomes, however, 52 (15%) required revisions – 10 for correcting asymmetries, 12 for correcting visible threads, and 2 who requested full removal of the thread due to dissatisfaction.

Similar results were reported by Rachel *et al.*²¹, who evaluated 29 patients who underwent unidirectional polypropylene anchored threads for approximately 12 months. Additional procedures were requested by 17 patients, with 5 removals and 9

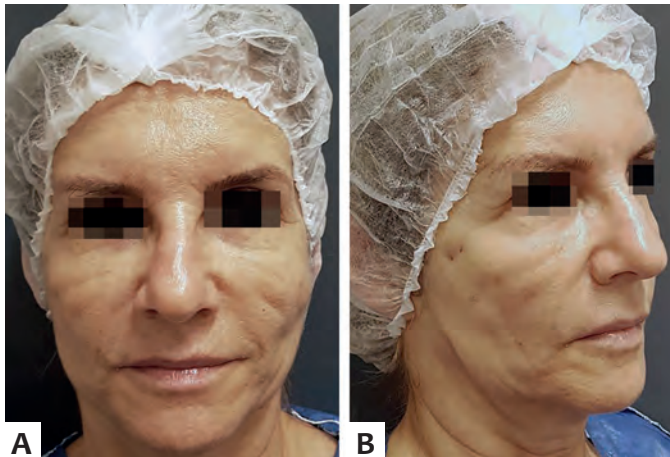

FIGURE 4: D7

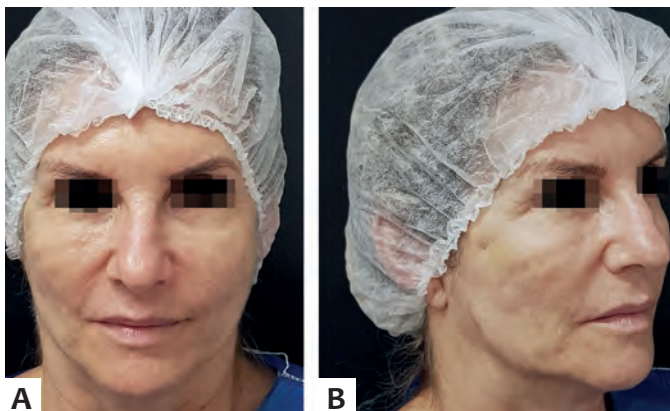

FIGURE 5: D30

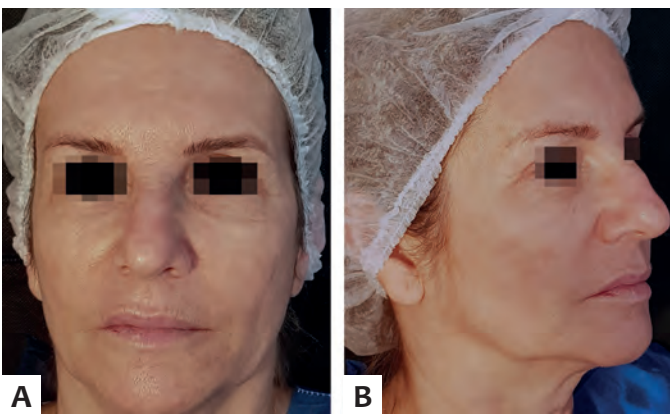

FIGURE 6: D90

asymmetry corrections. The author does not recommend the procedure due to the high rates of adverse effects.

Late complications described with the use of non-absorbable support threads are: migration, thread extrusion, and scar formation at the entry and exit points, infections, granulomas, and skin irregularities. More severe complications, such as Stensen duct rupture, facial nerve damage, and chronic foreign body sensation, were reported by other authors.^{7,22-25}

The present study is a valid representation of the short-term efficacy of this type of absorbable suture, since it evidenced a high patient satisfaction rate in different post-procedure periods as well as discrete and temporary side effects.

The data in this study support the daily practice of professionals aiming at improving their techniques for both prevention and treatment of cutaneous aging, since they reflect a high degree of tolerability, reduced risk of complications, high satisfaction rates and a shorter recovery time as compared to techniques such as rhytidectomy and non-absorbable sutures.

This study has limitations, such as the use of only one technique of application of the Silhouette® thread, and a reduced number of patients. Also, the follow-up period was limited to 90 days, which restricts the assessment of the applied product for durability, since an average of 18 months of effectiveness is expected. Future studies may answer the questions unaddressed by the present article.

The authors of the present article believe that the combination of the described technique with other methods, be these injectables, lasers or ultrasound, in a context of rejuvenation, may be taken with greater approval by patients. In light of the advancement of application methods, the increase in the number of sutures used and the increasingly effective associations, the authors of the present study believe that their findings may be enhanced by future research.

CONCLUSION

The use of absorbable suture threads is a good choice for patients with mild to moderate facial deflation and many times helps to postpone an invasive surgical procedure. Ideally, it should be used in conjunction with adjuvant techniques, such as biostimulators, cutaneous filling and botulinum toxin. Another important point is that the “face lift with threads” does not have the same indication as a surgical face-lift, since the former must be used at the first signs of relaxation of the skin. The procedure must be correctly recommended so that the expectations of the patient are met.²⁶ ●

REFERENCES

1. Isse N. Silhouette sutures for treatment of facial aging: facial rejuvenation, remodeling and facial tissue support. *Clin Plast Surg*. 2008;35(4):481-6.
2. Belda Junior W, Di Chiacchio N, Criado PR. *Tratado de Dermatologia*. 2ª ed. São Paulo: Editora Atheneu; 2014.
3. Ogilvie MP, Few JW, Tomur SS, Teven CM, Semersky AJ, Bruno CR, et al. Rejuvenating the Face: An Analysis of 100 Absorbable Suture Suspension Patients. *Aesthet Surg J*. 2018;38(6):654-63.
4. Avelar LET, Cazerta CEP, Avê MN, hitara DI. Dynamic changes of facial supporting cornerstones (pillars): considerations in aesthetic approach. *J Drugs Dermatol*. 2018;17(4):466-70.
5. Lambros V. Models of facial aging and implications for treatment. *Clin Plast Surg*. 2008; 35(3):319-27.
6. Kurita M, Matsumoto D, Kato H, Araki J, Higashino T, Yoshimura K, et al. Tissue reactions to cog structure and pure gold in lifting threads: a histological study in rats. *Aesthet Surg J*. 2011;31(3):347-51.
7. Tavares JC, Oliveira CACP, Torres RP, Bahmad F. Rejuvenescimento facial com fios de sustentação. *Braz J Otorhinolaryngol*. 2017;83(6):712-9.
8. Park TH, Seo SW, Whang KW. Facial rejuvenation with fine-barbed threads: the simple Miz lift. *Aesthet Plast Surg*. 2014;38(1):69-74.
9. De Carolis V, Gonzalez M. Neck rejuvenation with mastoid-spanning barbed tensor threads (MST operation). *Aesthet Plast Surg*. 2014;38(3):491-500.
10. Kim J, Zheng Z, Kim H, Nam KA, Chung KY. Investigation on the Cutaneous Change Induced by Face-Lifting Monodirectional Barbed Polydioxanone Thread. *Dermatol Surg*. 2017; 43(1):74-80.
11. Sasaki GH. Improved Blending of the Lid/Cheek With Modified Gore-Tex Knotted Cable Suspension Suture Systems. *Aesthet Surg J*. 2006;26(6):710-6.
12. Villa MT, White LE, Alam M, Yoo SS, Walton RL. Barbed sutures: a review of the literature. *Plast Reconstr Surg*. 2008;121(3):102e-8e.
13. Benito J, Pizzamiglio R, Theodorou D, Arvas L. Facial rejuvenation and improvement of malar projection using sutures with absorbable cones: surgical technique and case series. *Aesthetic Plast Surg*. 2011;35(2):248-53.
14. Machado Filho CDS, Santos TC, Rodrigues APLJ, Cunha MG. Ácido Polil-L-Láctico: um agente bioestimulador. *Surg Cosmet Dermatol*. 2013; 5(4):345-50.
15. Bisaccia E, Kadry R, Saap L, Rogachefsky A, Scarborough D. A novel specialized suture and inserting device for the resuspension of ptotic facial tissues: early results. *Dermatol Surg*. 2009;35(4):645-50.
16. Silhouette soft [homepage na internet]. O que é Silhouette Soft? [acesso em 07/11/2018]. Disponível em: <https://silhouette-soft.com/pt-br/what-is-silhouette-soft/>.
17. Consiglio F, Pizzamiglio R, Parodi PC, De Biasio F, Machin PN, Di Loreto C, et al. Suture with resorbable cones: histology and physico-mechanical features. *Aesthet Surg J*. 2016; 36(3):122-7.
18. Sasaki GH, Komorowska-Timek ED, Bennett DC, Gabriel A. An objective comparison of holding, slippage, and pull-out tensions for eight suspension sutures in the malar fat pads of fresh-frozen human cadavers. *Aesthet Surg J*. 2008;28(4):387-96.
19. Rezaee Khiabanloo S, Jebreili R, Aalipour E, Saljoughi N, Shahidi A. Outcomes in thread lift for face and neck: A study performed with Silhouette Soft and Promo Happy Lift double needle, innovative and classic techniques. *J Cosmet Dermatol*. Forthcoming 2018.
20. Lycka B, Bazan C, Poletti E, Treen B. The emerging technique of the antiptosis subdermal suspension thread. *Dermatol Surg*. 2004;30(1):41-4.
21. Rachel JD, Lack EB, Larson B. Incidence of complications and early recurrence in 29 patients after facial rejuvenation with barbed suture lifting. *Dermatol Surg*. 2010;36(3):348-54.
22. Gülbitti HA, Colebunders B, Pirayesh A, Bertossi D, van der Lei B. Thread-Lift Sutures: Still in the Lift? A Systematic Review of the Literature. *Plast Reconstr Surg*. 2018; 141(3):341e-7e.
23. Bigarella R. Use of polidioxanone knot threads in facial non-surgical rejuvenation. *Brazilian journal of Surgery and clinical research*. 2016;16(30):67-75.
24. Atiyeh BS, Dibo AS, Costagliola M, Hayek SN. Barbed sutures "lunch time" lifting: evidence-based efficacy. *J Cosmetic Dermatol*. 2010;9(2):132-41.
25. Paul MD. Complications of barbed sutures. *Aesthet Plast Surg*. 2008;32(1):149.
26. Nestor MS, Ablon G, Andriessen A, Few J, Gold MH, Goldberg DJ, et al. Expert Consensus on Absorbable Advanced Suspension Technology for Facial Tissue Repositioning and Volume Enhancement. *J Drugs Dermatol*. 2017;16(7): 661-6.

DECLARATION OF PARTICIPATION:

Marina Macellaro |  ORCID 0000-0002-6741-3868

Preparation and drafting of the manuscript. Critical review of the literature.

Maria Gabriela Ortiz Noronha |  ORCID 0000-0001-9577-8656

Preparation and drafting of the manuscript. Statistical analysis; Critical review of the literature.

Nathalia Hatsue Oushiro |  ORCID 0000-0001-8618-3247

Preparation and drafting of the manuscript. Critical review of the literature.

Renan Lage |  ORCID 0000-0001-7249-3658

Study design and planning; Data collection, analysis and interpretation; Effective participation in research guidance; Critical review of the manuscript.