

Imiquimod use for the treatment of extramammary Paget disease: series of four cases

Uso do imiquimode para tratamento da doença de Paget extramamária: série de quatro casos

DOI: <http://www.dx.doi.org/10.5935/scd1984-8773.20181041238>

ABSTRACT

Introduction: Extramammary Paget disease consists of a cutaneous adenocarcinoma in areas of apocrine glands. It is a rare neoplasia, and its surgical treatment yields satisfactory results. However, due to the high recurrence rates, surgeries are potentially disfiguring. Imiquimod is a topical immune-stimulant used for the treatment of anogenital warts and in situ carcinomas. Its use has been described in the scientific literature for the treatment of Extramammary Paget disease with satisfactory results.

Objective: Describe the course of four cases of Extramammary Paget disease treated with imiquimod, to evaluate evolution and therapeutic response.

Methods: A retrospective study was performed in a service of dermatology in the city of São Paulo, with the review of medical records of all patients diagnosed with Extramammary Paget disease and treated with imiquimod from January 2011 to July 2018.

Results: Four patients were included, three with vulvar lesion and one with scrotal lesion. Two women presented completed resolution of the disease, one did not respond and the man progressed with 70% regression of the lesion, having undergone surgical excision of a considerably smaller area than the initial lesion.

Conclusions: Imiquimod presents as a valid therapeutic modality for the treatment of Extramammary Paget disease.

Keywords: Paget disease, extramammary; Neoadjuvant therapy; Gynecology; Urogenital neoplasms, female; Genital neoplasms, male; Neoplasm recurrence, local; Skin neoplasms; Therapeutics; Vulvar neoplasms

RESUMO

Introdução: A doença de Paget extramamária é constituída por adenocarcinoma da pele em áreas de glândulas apócrinas. Trata-se de neoplasia rara cujo tratamento cirúrgico aparenta resultados satisfatórios. Devido às altas taxas de recorrência, entretanto, as cirurgias são potencialmente mutilantes. O imiquimode é imunestimulador tópico utilizado no tratamento de verrugas anogenitais e carcinomas in situ. Seu uso tem sido descrito na literatura científica para terapia da doença de Paget extramamária com resultados satisfatórios.

Objetivo: Descrever a evolução de quatro casos de doença de Paget extramamária tratados com imiquimode, para avaliação da evolução e resposta terapêutica.

Métodos: Foi realizado estudo retrospectivo em serviço de dermatologia da cidade de São Paulo com revisão de prontuários de todos os pacientes com diagnóstico de doença de Paget extramamária e tratados com imiquimode de janeiro de 2011 a julho de 2018.

Resultados: Foram incluídos quatro pacientes, três com lesão vulvar e um com lesão em bolsa escrotal. Duas mulheres evoluíram com resolução total da doença, uma não apresentou alteração, e o homem evoluiu com regressão de 70% da lesão, sendo submetido à exérese cirúrgica de área consideravelmente menor do que a da lesão inicial.

Conclusões: O imiquimode se apresenta como método terapêutico válido no tratamento da doença de Paget extramamária.

Palavras-Chave: Doença de Paget extramamária; Neoplasias urogenitais; Neoplasias cutâneas; Neoplasias dos genitais femininos; Neoplasias dos genitais masculinos; Neoplasias vulvares; Recidiva local de neoplasia; Terapêutica; Terapia neoadjuvante; Ginecologia

Original Articles

Authors:

John Verrinder Veasey¹
Barbara Arruda Fraletti Miguel¹
Adriana Bittencourt Campaner²
Thiago da Silveira Manzione³

¹ Clínica de Dermatologia, Hospital da Santa Casa de São Paulo – São Paulo (SP), Brasil.

² Departamento de Obstetrícia e Ginecologia, Hospital da Santa Casa de São Paulo – São Paulo (SP), Brasil.

³ Departamento de Cirurgia, Hospital da Santa Casa de São Paulo – São Paulo (SP), Brasil.

Correspondence:

John Verrinder Veasey
Hospital da Santa Casa de São Paulo
Rua Dr Cesário Mota Jr, 112
Edifício Conde de Lara – 5º andar
Vila Buarque
01221-020, São Paulo, SP
Brasil
E-mail: johnveasey@uol.com.br

Received on: 22/08/2018

Approved on: 08/12/2018

This study was performed at Hospital da Santa Casa de São Paulo – São Paulo (SP), Brasil.

Financial support: None.

Conflict of interests: None.



INTRODUCTION

Extramammary Paget disease (EMPD) is represented by cutaneous adenocarcinoma with similar histology to mammary Paget disease. It affects the skin regions with apocrine glands, more frequently the vulva, followed by the perianal area, scrotum and axilla. It is classified into primary, when it affects the skin only, and secondary, when there is an underlying or distant carcinoma.¹

Its clinical aspect can be similar to other diseases such as tinea, contact dermatitis, seborrheic dermatitis, psoriasis and Bowen's disease, making the clinical diagnosis difficult. Diagnostic confirmation is through histopathology, and lately, reflectance confocal microscopy has also been used as an *in vivo* diagnostic tool.² After confirmation of the diagnosis, it is crucial to define if EMPD is exclusively cutaneous (primary) or if there is an underlying disease (secondary) by looking for malignancy in pelvic and intra-abdominal organs, such as gallbladder, liver and colon, and breasts.¹

Treatment is challenging for many reasons. The centrifugal growth of the tumor with subclinical lesions in the periphery is one of them, which can conceal the right area to be treated. The diagnostic delay due to the similarity to other skin conditions allows for the progressive growth of the disease, and the location of the neoplasia in areas that are difficult to reach.³ Many treatments are described for EMPD: surgical excision,⁴ radiotherapy,⁴ photodynamic therapy and topical treatments,⁵ and out of those, Mohs micrographic surgery provides the best results. However, the recurrence rate is around 30%, which can lead to mutilating surgical outcomes.⁶

Imiquimod (IQM) is a substance that activates the epithelial immune response where it is applied. During this process, IQM induces keratinocytes to release cytokines that trigger the innate response of the epithelium at the same time that it stimulates the migration of Langerhans cells, that in turn start the process of acquired response when identifying the foreign agent to be attacked. In face of this combined immunobiologic stimulation, IQM demonstrates antiviral and antitumor activity.⁷ Recent studies have demonstrated good therapeutic response of EMPD to IQM.

OBJECTIVE

In this study, we present the experience of the dermatol-

ogy clinic of the only public service of the city of São Paulo on the use of IQM as monotherapy for EMPD.

METHOD

A retrospective study with files from all patients seen at the dermatology clinic of Santa Casa de São Paulo, SP, Brazil, who were diagnosed with EMPD and treated with IQM from January 2011 to July 2018 was conducted.

The characteristics analyzed from each case were: clinical profile of the patient (sex, age, comorbidities), location of the lesion, time of disease before treatment with IQM, previous treatments, time of treatment with IQM, treatment response (total, partial or lack of improvement) and time of follow-up after treatment for analysis of recurrence.

RESULTS

Four patients were included in this study: three women with vulvar lesions and one man with lesion on the scrotum. They were investigated regarding the presence of concurrent malignancies, however, there were no abnormalities. The details for each case are presented on table 1. All patients had their diagnosis of EMPD by skin biopsy and histopathology, and screening for systemic involvement through imaging studies: mammogram, abdominal and pelvic tomography. In all cases, IQM application was done on five consecutive days at night, with two days rest on the weekend without using the product.

Patient 1, 68 years old and history of systemic hypertension (HTN) and diabetes mellitus (DM), underwent hysterectomy in 2011 due to endometrial adenocarcinoma and was diagnosed with EMPD in 2016. She had a progressively growing vulvar lesion for six months, with no previous treatment. At the time of the EMPD diagnosis, she had no systemic involvement of the disease, so IQM was prescribed for eight weeks, with complete response and no recurrence after 23 months of follow-up (Figure 1).

Patient 2, 85 years old, had history of HTN, following-up vulvar EMPD since 2009, with no systemic involvement of the disease. She underwent five surgical interventions between 2009 and 2016, all of them with recurrence of the lesion. After this period, she started treatment with IQM, finishing eight weeks of application. She progressed with complete improvement of the

TABLE 1: Characteristics of the four cases of extramammary Paget disease and their course with the use of imiquimod

Patient	Sex	Age	Location	Internal Involvement	Time of disease	Previous treatments	Time of IQM (weeks)	Response	Follow-up	Recurrence
Case 1	Feminine	68	Vulva	No*	6 months	No	8	Complete improvement	23 months	No
Case 2	Feminine	85	Vulva	No	8 years	Surgical excision	8	Complete improvement	17 months	No
Case 3	Feminine	64	Vulva	No	3 years	Surgical excision	28	No response	2 months	...**
Case 4	Masculine	72	Scrotum	No	10 years	Surgical excision	8	Partial improvement	48 months	Yes

*no internal involvement at the time of treatment with imiquimod, however, with past history of uterine adenocarcinoma and hysterectomy five years prior.

**there was no response, recurrent analysis not possible

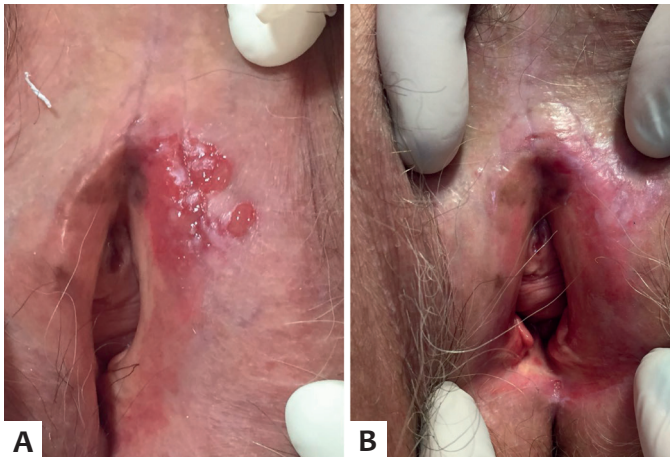


FIGURE 1: Case 1 extramammary Paget disease. **A** – Pre-treatment, lesion on the upper left region of the vulva.

B – After eight weeks of treatment with imiquimod, complete improvement

lesion, with no recurrence 17 months after finishing the treatment (Figure 2).

Patient 3, 64 years old, diagnosed with Paget disease in the vulva with no systemic involvement, underwent surgical treatment between 2014 and 2016, with recurrence. She started treatment with IQM in 2016, finishing 28 weeks of application; however, there was no satisfactory response, and she had to undergo a new surgical excision of the lesion in 2017, that yielded margins free of the tumor. Two months after the surgery she developed recurrence (Figure 3). Patient 4, male and 72 years old, had past history of HTN, acute myocardial infarction with myocardial revascularization, cardiac failure and thrombus on anticoagulant. He was diagnosed with EMPD of the scrotum in 2013, with no systemic involvement. He initially underwent two surgical interventions, with recurrence of the lesion between 2013 and 2016. He started treatment with IQM for eight weeks in 2016, with partial response and reduction of the lesion. He underwent a new surgical intervention, progressing with improvement; he is under follow-up for two years, with no signs of recurrence till present (Figure 4).

DISCUSSION

EMPD is an extremely rare malignancy, corresponding to 0.7% to 4.3% of the cases of breast malignancies⁸ and less than 1% of vulvar malignancies.⁹ Studies on this malignancy are rare, and report years of medical assistance to group the few cases, as we presented here. In seven years of dermatology assistance in a tertiary public hospital in the capital of São Paulo, there were only four cases of EMPD.

Regarding the use of IQM as treatment for EMPD cases, Luyten *et al.* observed a rate of complete response of 80% of the cases treated with this substance, and believe that the time of IQM could be related to the final result of the treatment.⁶ H. Machida *et al.* conducted a systematic review and demonstrated a rate of complete response to treatment of 52 to 80%, with re-

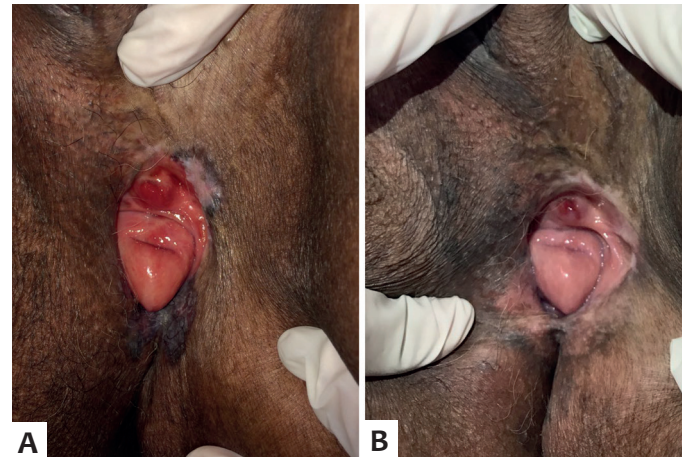


FIGURE 2: Case 2 extramammary Paget disease. **A** – Pre-treatment, two lesions on the vulvar region, one on the upper left and another inferiorly, near the posterior commissure. **B** – After eight weeks of imiquimod, complete response

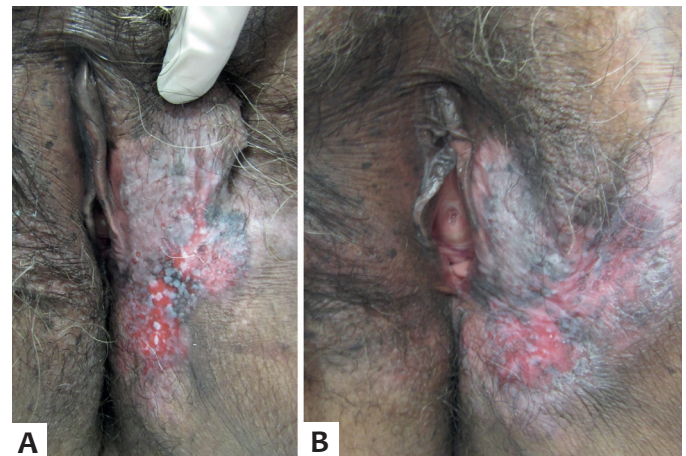


FIGURE 3: Case 3 extramammary Paget disease. **A** – Pre-treatment, extensive are of involvement on the left side of the vulva.

B – After 28 weeks of imiquimod, no response to treatment

currence rate of 19%, however, they highlighted that besides being retrospective, the studies were limited regarding the sample size. In their review, they mentioned other forms of treatment and their recurrence rates: 58% for surgical excision, 0–35% for radiotherapy, 25% for chemotherapy with 5 fluorouracil and bleomycin, 38% to 56% for photodynamic therapy, 67% for treatment with ablative laser.¹⁰ Thus, the choice for the appropriate treatment for these patients is extremely important, since these therapies can cause side effects and consequences in the quality of life of the patients.

In this study we report only four cases, what represents an extremely small sample and with little statistical relevance of the data when analyzed in isolation. Of these four cases, two patients (50%) showed complete response to IQM use, while one (25%) showed partial response and another (25%), lack of response. We

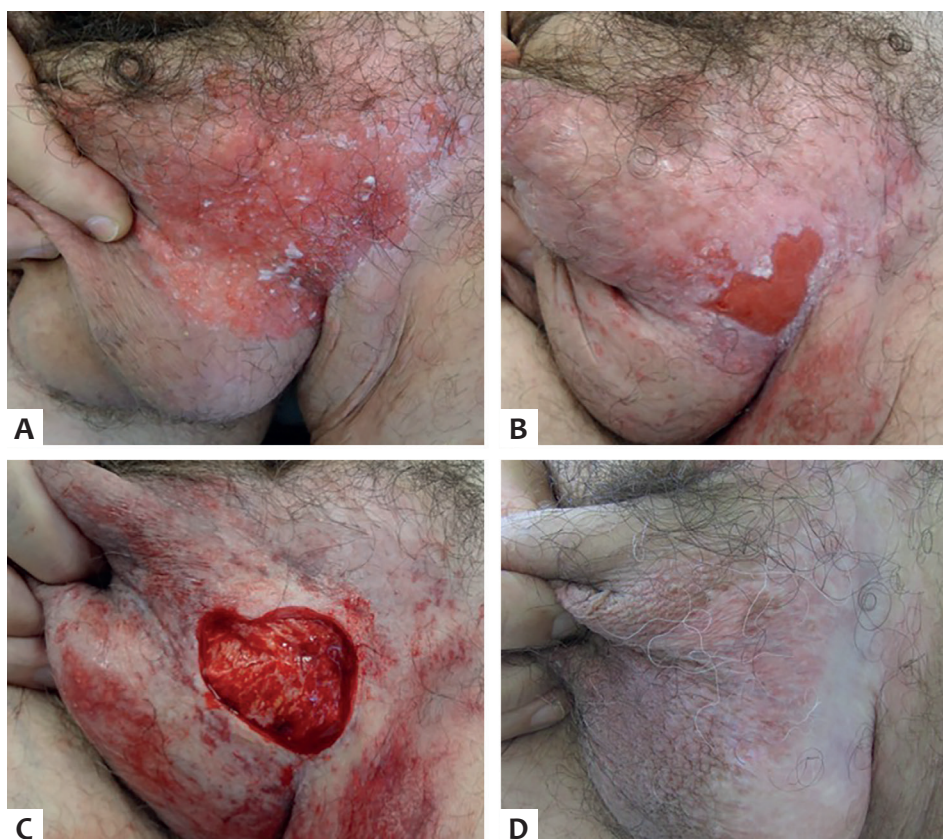


FIGURE 4: Case 4 extramammary Paget disease. **A** – Pre-treatment, extensive lesion on the scrotum. **B** – After eight weeks of treatment with imiquimod, with partial improvement and reduction of the affected area. **C** – After surgical excision. **D** – Follow-up of two months, with no recurrence till present

believe that, despite the rate of complete improvement in our study being of 50%, achieving partial response with the use of imiquimod was also beneficial. The patient had a reduction in the initial size of the lesion, which allowed for a surgical excision with disease-free margins of a considerably smaller lesion, reducing the size of the tumor before the surgery and allowing for a more conservative surgical approach, with less areas for reconstruction, shorter healing time and better cosmetic and functional outcomes. Extensive excisions in the anogenital region can be disfiguring and cause serious functional problems.

One must also consider that, even after surgery, there is a high recurrence rate for EMPD due to its multifocal nature with the presence of tumor in clinically undetectable areas. Of the cases here presented, three underwent previous surgeries and had recurrence of the disease. The two patients that had complete response with IQM progressed recurrence-free during the clinical follow-up period.

There is no consensus regarding duration of treatment, since most studies are retrospective and not standardized. Machida *et al.* recommend in their review to initiate treatment with IQM three to four times per week for six months, since this treatment seems to be time-dependent. They suggest reducing the frequency of applications in case there are side effects until the therapeutic dose is tolerated.¹⁰

The use of IQM in the cases presented was indicated as daily application five times a week, because it is similar to that suggested to treat basal cell carcinoma, another malignancy that can be treated with IQM.¹¹

CONCLUSIONS

We believe IQM is a valid treatment for EMPD, and can lead to complete or partial resolution of the disease and avoid mutilating procedures. ●

REFERENCES

1. Lopes Filho LL, Lopes IMRS, Lopes LRS, Enokihara MMSS, Michalany AO, Matsunaga N. Mammary and extramammary Paget's disease. *An Bras Dermatol*. 2015;90(2):225-31.
2. Pan Z-Y, Liang J, Zhang Q-A, Lin J-R, Zheng Z-Z. In vivo reflectance confocal microscopy of extramammary Paget disease: Diagnostic evaluation and surgical management. *J Am Acad Dermatol*. 2012;66(2):e47-53.
3. Sanderson P, Innamaa A, Palmer J, Tidy J. Imiquimod therapy for extramammary Paget's disease of the vulva: A viable non-surgical alternative. *J Obstet Gynaecol*. 2013;33(5):479-83.
4. Dilmé-Carreras E, Iglesias-Sancho M, Márquez-Balbás G, Sola-Ortigosa J, Umbert-Millet P. Radiotherapy for extramammary Paget disease of the anogenital region. *J Am Acad Dermatol*. 2011;65(1):192-4.
5. Hanna E, Abadi R, Abbas O. Imiquimod in dermatology: an overview. *Int J Dermatol*. 2016;55(8):831-44.
6. Luyten A, Sörgel P, Clad A, Giesekeing F, Maass-Poppenhusen K, Lellé RJ, et al. Treatment of extramammary Paget disease of the vulva with imiquimod: A retrospective, multicenter study by the German Colposcopy Network. *J Am Acad Dermatol*. 2014;70(4):644-50.
7. Suzuki H, Wang B, Shivji GM, Toto P, Amerio P, Sauder DN, et al. Imiquimod, a Topical Immune Response Modifier, Induces Migration of Langerhans Cells. The authors have declared a conflict of interest. *J Invest Dermatol*. 2000;114(1):135-41.
8. Wagner G, Sachse MM. Extramammary Paget disease - clinical appearance, pathogenesis, management. *J Dtsch Dermatol Ges*. 2011;9(6):448-54.
9. Cowan RA, Black DR, Hoang LN, Park KJ, Soslow RA, Backes FJ, et al. A pilot study of topical imiquimod therapy for the treatment of recurrent extramammary Paget's disease. *Gynecol Oncol*. 2016;142(1):139-43.
10. Machida H, Moeini A, Roman LD, Matsuo K. Effects of imiquimod on vulvar Paget's disease: A systematic review of literature. *Gynecol Oncol*. 2015;139(1):165-71.
11. Micali G, Lacarrubba F, Nasca MR, Ferraro S, Schwartz RA. Topical pharmacotherapy for skin cancer. *J Am Acad Dermatol*. 2014;70(6):979.e1-979.e12.


DECLARATION OF PARTICIPATION:

John Verrinder Veasey |  ORCID 0000-0002-4256-5734

Approval of the final version of the manuscript; study conception and planning; preparation and drafting of the manuscript; data collection, analysis and interpretation; effective participation in research guidance; intellectual participation in propaedeutic and / or treatment of the cases studied; critical review of the literature, critical review of the manuscript

Barbara Arruda Fraletti Miguel |  ORCID 0000-0002-0448-0369

Approval of the final version of the manuscript; study conception and planning; preparation and drafting of the manuscript; data collection, analysis and critical review of the literature, critical review of the manuscript

Adriana Bittencourt Campaner |  ORCID 0000-0002-3044-3019

Study conception and planning; intellectual participation in propaedeutic and / or treatment of the cases studied

Thiago da Silveira Manzione |  ORCID 0000-0003-1914-0129

Study conception and planning; intellectual participation in propaedeutic and / or treatment of the cases studied;