

# Profile of surgically treated lesions in toes and fingers, at a dermatology referral service

*Perfil das lesões tratadas cirurgicamente em pododáctilos e quirodáctilos em um serviço de referência de dermatologia*

DOI: <http://www.dx.doi.org/10.5935/scd1984-8773.20181021174>

## ABSTRACT

**Introduction:** Lesions in fingers and toes are frequent in the dermatological practice, and diagnosis is feasible in the majority of cases after a thorough anamnesis and physical examination.

**Objective:** To draw a profile of the most prevalent lesions in toes and fingers that were surgically approached by the dermatologic surgery team, at a dermatologic referral service, as well as to evaluate the classification of these lesions, their distribution among age groups and genders, and the correlation between clinical suspicion and anatomopathological diagnosis.

**Methods:** A retrospective observational study was performed with 344 patients, and the evaluation of 367 surgical procedures.

**Results:** The analysis showed that most of the procedures were performed in female adults, with the left hallux being the most affected location in the studied sample. It was also verified that the majority of the procedures were linked to lesions of traumatic nature, with biopsy/excision and canthoplasty/canthotomy being the most accomplished procedures.

**Conclusions:** The results of the present study contribute to the planning and design of future dermatological care.

**Keywords:** Ambulatory surgical procedures; Fingers; Toes

## RESUMO

**Introdução:** As lesões em quirodáctilos e pododáctilos são frequentes na prática dermatológica, sendo possível diagnosticar a maioria após anamnese completa e exame físico.

**Objetivo:** Traçar perfil das lesões mais prevalentes em pododáctilos e quirodáctilos abordadas cirurgicamente pela equipe de cirurgia dermatológica em um serviço de referência em dermatologia, bem como avaliar a classificação dessas lesões, sua distribuição nas faixas etárias, gêneros, locais de acometimento e a correlação entre a suspeita clínica e o diagnóstico anatomopatológico.

**Métodos:** Estudo epidemiológico observacional retrospectivo transversal incluindo e avaliando 344 pacientes e 367 procedimentos cirúrgicos.

**Resultados:** A análise demonstrou que a maior parte dos procedimentos foi realizada em adultos, do sexo feminino, sendo o hálux esquerdo a localização mais acometida na amostra estudada. Verificou-se também que a maioria dos procedimentos decorreu de lesões de natureza traumática, sendo a biópsia/exérese de lesões e a cantoplastia/cantotomia os procedimentos mais realizados.

**Conclusões:** Os resultados deste estudo contribuem para o planejamento e dimensionamento de futuros atendimentos dermatológicos.

**Palavras-chave:** Dedos; Dedos do pé; Procedimentos cirúrgicos ambulatoriais

## Original Articles

### Autors:

Luisa Preisler<sup>1</sup>  
Ludmilla Cardoso Gomes<sup>1</sup>  
José Roberto Pereira Pegas<sup>1</sup>

<sup>1</sup> Complexo Hospitalar Padre Bento de Guarulhos, Guarulhos (SP), Brazil.

### Correspondence:

Luisa Preisler  
Ambulatório de Dermatologia  
Av. Emílio Ribas, 1819, Bairro Gopouva  
CEP 07051-000 - Guarulhos (SP),  
Brasil  
E-mail: [luisapreisler@gmail.com](mailto:luisapreisler@gmail.com)

Received on: 26/03/2018

Approved on: 01/06/2018

This study was performed at the Complexo Hospitalar Padre Bento de Guarulhos, Guarulhos (SP), Brazil.

Financial support: None

Conflict of interests: None



## INTRODUCTION

Lesions in fingers and toes are common in the dermatologist physician's routine. Despite their great importance, there is little information about this topic in the dermatological literature.<sup>1</sup> Many of these lesions, in addition to affecting productivity, cause limitations to daily activities.<sup>2</sup> It was estimated that in 2004, the cost of dermatological diseases was US\$ 39.3 billion in the USA,<sup>2</sup> with a significant impact not only on the quality of life of those affected,<sup>3</sup> but also on health systems spending. Considering that epidemiological information is fundamental for directing health policies,<sup>3</sup> this paper is aimed at outlining the profile of the most prevalent lesions in toes and fingers that were treated by the dermatologic surgery team in a dermatology referral service, in addition to evaluating the classification of these lesions, their distribution by age groups, genders and body sites of occurrence, as well as the correlation between the clinical suspicion of lesions and their anatomopathological diagnosis.

## MATERIALS AND METHODS

A cross-sectional retrospective observational epidemiological study was performed, in which dermatological surgeries performed on lesions located in chirodactyls and toes were analyzed in a period of 93 months (August 2009 to April 2017), as well as their histological evaluations, and the records of patients who underwent the surgical procedures, surgical records books and pathological anatomy reports, in the dermatology ambulatory of the Complexo Hospitalar Padre Bento de Guarulhos (CH-PBG). Lesions operated by the hospital's plastic and oncological surgery teams were excluded, while lesions located in chirodactyls and pododactyls operated by the dermatologic surgery team during the period considered and ambulatorially followed up were included. The present study was approved by CHPBG's Research Ethics Committee (Opinion number: 2,300,429).

The lesions were classified by the authors into: tumoral, traumatic, inflammatory, infectious and others. The first group included tumors of vascular, cystic, fibroepithelial, neural, melanocytic, epithelial, and other origins. Traumatic lesions included nail plate alterations, onychocryptosis and callosities. Inflammatory lesions included unguinal psoriasis, annular granuloma and chronic paronychia. In the studied sample, viral warts represented infectious lesions. The lesions resulting from deposition (gouty tophi), genetic alterations (rudimentary and supernumerary fingers) and actinic keratosis, were classified as "other".

The procedures performed were standardized and grouped into: biopsy of the nail apparatus; canthotomy / canthoplasty; biopsy / lesion exeresis; curettage associated or not to electrocoagulation, and others. Biopsies of the nail apparatus comprised those performed in the nail's bed, matrix or plate. Canthotomy and canthoplasty included the implementation of Haneke's techniques,<sup>4</sup> Fanti's surgery,<sup>5</sup> matricectomy,<sup>4</sup> reduction of the nail folds using the Dubois<sup>4</sup> or "super U" techniques,<sup>4</sup> in addition to phenolization of the nail matrix.<sup>4</sup> Exeresis / biopsy corresponded to procedures for complete removal of tumors and / or biopsies of lesions located outside the nail apparatus. Curettage and electrocoagulation were performed for the

treatment of viral warts and pyogenic granulomas. The group "Others" consisted of the techniques of prolonged stay suture (mucosal cyst transfixation), oblique exeresis of the proximal nail fold, and osteotomy, used for the treatment of mucinous / myxoid cysts, chronic paronychia and osteochondromas, respectively.

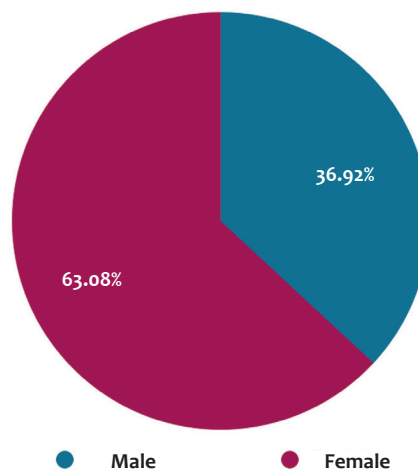
For concordance analysis between preoperative and post-operative diagnoses, two variables were established: "yes" and "no / inconclusive". The first variable includes the cases in which the preoperative diagnostic hypothesis was confirmed by anatomopathological analysis. The second refers to cases of disagreement between pre- and postoperative diagnoses, to those whose previous hypotheses were not identified in the analyzed records, or those with inconclusive results. The lesions studied were also grouped and classified as benign or malignant.

## RESULTS

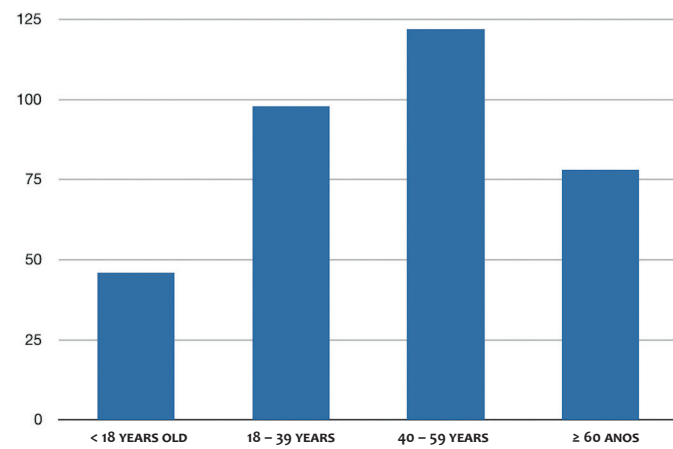
A total of 454 records of patients followed up by the dermatologic surgery team were analyzed, with 110 exclusions due to discordance of lesion location, incomplete data, missing medical records, or the non-surgical nature of the procedures, such as cryotherapy and infiltration of periungual medication.

A total of 344 patients were included in the study, of which 63.08% were female, and 36.92% were male (Graph 1). The age ranged from 5 to 89 years (mean value = 43.1 years, STD = 19.59 years). Of the patients evaluated, 13.37% were younger than 18 years old at the time of the procedure, 28.49% were between 18 and 39 years old, 35.47% were between 40 and 59 years old, and 22.67% were older than 60 years (Graph 2).

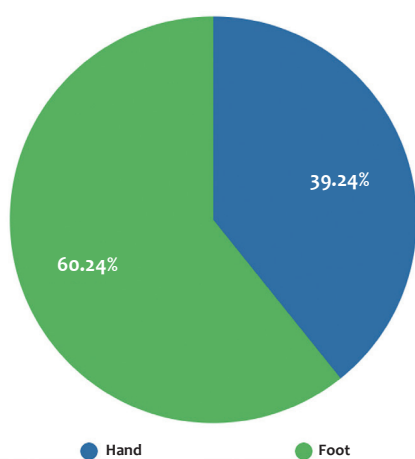
Regarding the location of surgically treated lesions, the study showed that they were more frequent in pododactyls (60.76%) than in chirodactyls (39.24%) (Graph 3), with the most frequently affected being the left hallux (22.07%) and the right hallux (19.89%) (Figure 1).



GRAPH 1: Gender



GRAPH 2: Age group



GRAPH 3: Chirodactyls and pododactyls that underwent procedures

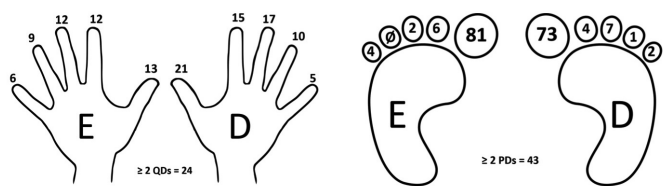
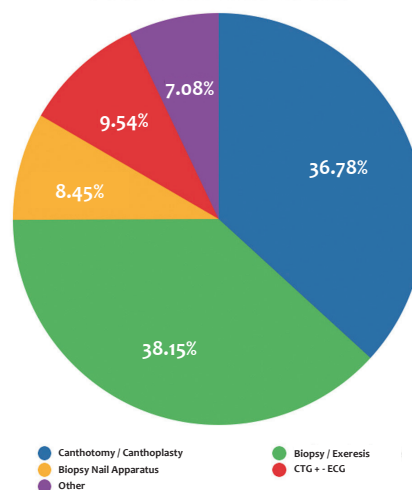


FIGURE 1: Number of lesions operated on each finger and toe

A total of 367 procedures were performed, with the most frequent being biopsy / excision of lesions in fingers and toes, corresponding to 38.15% of the total, while biopsies of nails comprised only 8.45% of the cases. Canthotomy / canthoplasty was the second most frequent procedure, with 36.78% of the total. Curettage, whether or not accompanied by electrocoagulation, accounted for 9.54% of the sample. Other less frequent procedures, such as oblique excision of the proximal nail fold, osteotomy and the prolonged stay suture technique (transfixation of mucosal cyst) corresponded to 7.08% of the total (Graph 4).



GRAPH 4: Procedure performed

Regarding the procedures performed, 141 lesions were sent for anatomopathological study. Taking into account only lesions that were sent for analysis, 55.32% were classified as having tumoral origin (Graph 5).

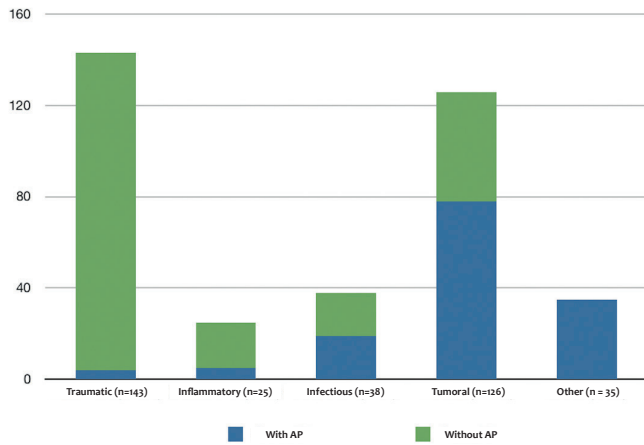
Evaluating all 367 procedures, it was possible to verify that the majority resulted from lesions of traumatic nature (Graph 5).

Of the lesions of tumoral origin, 92.31% were benign, and 7.69% malignant, the latter corresponding to five squamous cell carcinomas and one melanoma, totaling 6 malignant neoplasms in the sample. Graph 6 shows the proportion of benign lesions (95.74%) and malignant lesions (4.26%), as percentages of the total sent for anatomopathological analysis.

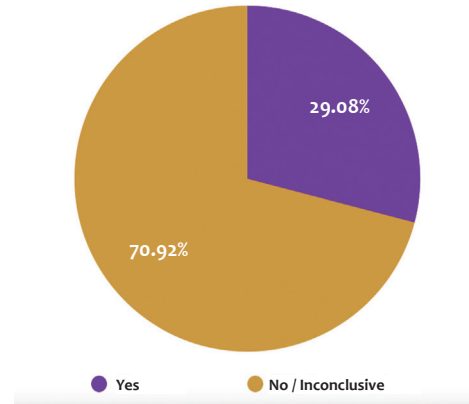
The concordance between the diagnostic hypothesis and the anatomopathological report was positive for 29.08% of the sample, with the remaining 70.92% coming out inconclusive or discordant (Graph 7).

## DISCUSSION

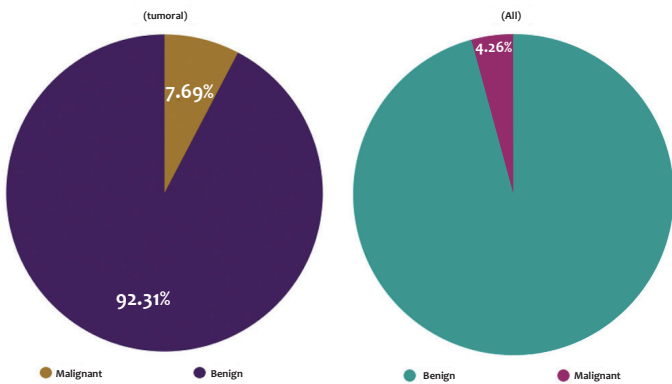
Lesions in toes and fingers can mostly be diagnosed by complete anamnesis and physical examination, and handled adequately by dermatologist physicians with training in dermatological surgery.<sup>6</sup> Epidemiological information about them is crucial for directing health policies, however they are unfortunately limited when taking into account all dermatological nosologies.<sup>3</sup> In the case of lesions in fingers and toes, the information is even scarcer. In a study carried out by the Brazilian Society of Dermatology in 2006 on the profile of diseases treated in dermatological consultations in Brazil, the main reason for consultation was acne, followed by superficial mycoses, pigmentation disorders and actinic keratosis. A subsequent study carried out in 2011 at a dermatology reference center in the Northern Brazilian State of Amazonas on the frequency of dermatoses, found STDs, allergic dermatoses, unspecified dermatoses, leprosy and acne, seborrhea and the like as the five most diagnosed groups.<sup>7</sup> Both studies evaluated only ambulatorial consultations



GRAPH 5: Nature of the lesions



GRAPH 7: Concordance between the hypothesis and the AP anatomopathology examination → sim



GRAPH 6: Benign lesions x malignant lesions

without information on the location of the lesions, also not contemplating non-surgical procedures, which probably was one of the factors that contributed to the discordance with the findings of the present study, where only lesions located on toes and fingers were evaluated. A study carried out from 2002 to 2007 in Curitiba, the capital of the Southern Brazilian State of Paraná, analyzed the surgical procedures performed in a medi-

cal residency service, verifying that the most frequent procedure was diagnostic biopsy.<sup>8</sup> Although this study did not describe the location of the lesions treated, it was possible to observe the presence of agreement with the findings of the present study.

Regarding the most frequently affected age group and gender, the present study is in line with the available literature regarding ambulatory care, with the majority of patients being female and young adults.<sup>2,3</sup> No studies were found in the literature describing the frequency and types of surgical procedures performed in fingers and toes, nor the most frequent nature of the lesions or correlation between clinical and anatomopathological diagnosis.

**CONCLUSION**

Analysis of the results showed that most of the procedures were performed in adult female patients, with the left hallux being the most affected location in the sample studied. Based on the analysis of the data collected, it was also verified that most of the procedures resulted from lesions of traumatic nature, with biopsy / excision of lesions, and canthotomy / canthoplasty being the most frequently performed procedures, with prevalence of the benign lesions over malignant ones. The present study contributes to the planning and design of future dermatological consultations. ●

## REFERENCES

1. Sobanko JF, Dagum AB, Joseph FS, Davis IC, Kriegel DA. Soft Tissue Tumors of the Hand. Benign. *Dermatol Surg*. 2007;33(7):651-67.
2. Bickers DR, Lim HW, Margolis D, Weinstock MA, Abrams BB, Goodman C, et al. The burden of skin diseases: 2004. A joint project of the American Academy of Dermatology Association and the Society for Investigative Dermatology. *J Am Acad Dermatol*. 2006;55:490-500.
3. Sociedade Brasileira de Dermatologia. Perfil nosológico das consultas dermatológicas no Brasil. *An Bras Dermatol*. 2006;81:549-58.
4. Di Chiacchio N, Belda Junior W, Criado PR. Unhas: o que há de novo. 1ª ed. Editora Atheneu: Rio de Janeiro; 2015.
5. Oliveira GB, Rossi NCP, Cury DO, Ballavenuto JMA, Antonio CR, Antonio JR. Tratamento de unha em pinça pela técnica de Fanti. *Surg Cosmet Dermatol*. 2014;6(2):122-5.
6. Sobanko JF, Dagum AB, Joseph FS, Davis IC, Kriegel DA. Soft Tissue Tumors of the Hand. Malignant. *Dermatol Surg* 2007;33(7):771-85.
7. Raposo AA, Schettini APM, Sardinha JCG, Pedrosa VL. Perfil nosológico de centro de referência em dermatologia no Estado do Amazonas - Brasil. *An Bras Dermatol*. 2011;86(3):463-8.
8. Morais RL, Guislandi C, Santamaria JR, Serafini SZ, Mulinari-Brenner F. Dermatologia clínico-cirúrgica: avaliação da mudança no perfil dos procedimentos de um serviço de residência médica no Paraná-BR. *Surg Cosmet Dermatol* 2010;2(2):105-10.

## DECLARATION OF PARTICIPATION:

**Luisa Preisler** |  ORCID 0000-0002-1600-9953

Conceptual development and research project planning; preparation and write up of the manuscript; data acquisition, analysis and interpretation; approval of the final version of the manuscript

**Ludmilla Cardoso Gomes** |  ORCID 0000-0002-8165-5345

Conceptual development and research project planning; preparation and write up of the manuscript; data acquisition, analysis and interpretation; approval of the final version of the manuscript

**José Roberto Pereira Pegas** |  ORCID 0000-0002-2541-6008

Conceptual development and planning of the research project, review and approval of the final version of the manuscript