

# 2940-nm Erbium Laser, fractionated with dual pulse, for photorejuvenation: clinical and pathologic trial of effects on skin tissue

## ABSTRACT

**Introduction:** The 2940-nm Erbium Laser has been used for years in photoaging treatment, with pulse duration of 0.25 ms. Currently, it has been widely used in fractionated mode. New pulse duration of 5 ms was introduced in an attempt to promote tissue coagulation, in addition to ablation, improving its treatment performance. **Objective:** To investigate the mechanism by which this laser rays act on cutaneous tissue, in its fractionated and dual pulse mode, clinically and histopathologically. **Material and methods:** Six female patients with marked photoaging (Fitzpatrick Classification Scale, degrees III and IV) were selected to this study. Biopsies were performed 1 week before and 2 months after treatment. Clinical and histological assessments were conducted using the following stains: hematoxylin-eosin, Verhoeff, and Masson's trichrome. **Results:** There was significant clinical improvement in all patients, and histology showed foci sizes compatible with the laser microbeam shot in areas where decreased solar elastosis occurred. In two cases with more significant results, these areas were measured. **Conclusions:** Clinically, there was marked improvement in six patients treated. Focal changes were found and they were similar in size to the rays shot, while previous studies with fractionated 2940-nm Erbium showed areas of non-circumscribed neocollagenesis.

**Keywords:** rejuvenation, photoaging, lasers.

## INTRODUCTION

Since the beginning of its therapeutic use in the past decade, ablative 2940-nm Erbium and 10,600-nm CO<sub>2</sub> lasers have been useful in photoaging skin treatment.<sup>1,2</sup> As both have great affinity for water, they are ablative lasers; that is, they remove the skin and promote a strong residual heat, causing the water in dermis to be heated approximately 60 to 100°C and, therefore, desired effects such as actinic elastosis reduction and neocollagenesis promotion occur.<sup>3,4</sup> The initial results were exciting, but over time several side effects were observed, more pronounced and frequent with CO<sub>2</sub>, such as temporary or permanent hypochromia, hypertrophic scars, and keloids.<sup>5</sup> Therefore, there was a decline in the use of these devices.

Six years ago, approximately, the first fractional lasers have emerged, which are the modified Erbium laser,<sup>6,7</sup> with a wavelength of 1550 and 1540 nm,<sup>8</sup> and the YAG lasers of 1440 nm. These lasers have less affinity for water and are non-ablative (do not remove the epidermis). Over time, it was found that with these wavelengths, the capacity of collagen production is limited and that it would be necessary to use more effective techniques for treating patients with more severe degrees of photoaging. Since then, application of ablative lasers was resumed, now in fractionated mode, that is, only fractions of the skin are exposed to rays in a single treatment session, and thus there is a reduction of thermal damage in each procedure. With this procedure there is a less intense and shorter postoperative period and with less risk of side effects, but the results are subtler.

## Authors:

Roberto A. Mattos<sup>1</sup>  
Neusa Y.S. Valente<sup>2</sup>  
Mônica Senise<sup>3</sup>  
Valéria B. Campos<sup>4</sup>

<sup>1</sup>Preceptor – Hospital do Servidor Público Estadual de São Paulo; MD in Dermatology; Board Member of the Laser Department – SBD

<sup>2</sup>Dermatopathologist – Hospital de Servidor Público Estadual de São Paulo; Preceptor – Hospital Servidor Público Estadual de São Paulo; PhD in Dermatology

<sup>3</sup>Dermatologist Member of the Brazilian Society of Dermatology

<sup>4</sup>Postgraduate in Laser and Photomedicine at Harvard Medical School, Coordinator of the Laser Department – Brazilian Society of Dermatology 2009/2010; MD in Dermatology

## Correspondence to:

Roberto A. Mattos  
Alameda Casa Branca, 615/ap. 121  
São Paulo – SP – Brasil  
CEP: 01408-00  
Tel: +55 (11) 3889-8246

Submitted on: 09/30/2009

Approved on: 11/10/2009

We declare no conflicts of interest.

The 2940-nm Erbium Laser has lower penetration and thermal effect than the 10600 nm CO<sub>2</sub>,<sup>4</sup> therefore, also presenting subtler results. This is because the 2940-nm Erbium has a greater affinity for water than CO<sub>2</sub> and, when shot in a time of 0.25 ms, it does not cause tissue coagulation.

In order to verify if it increases treatment efficacy, dual pulse was used in this study, besides the shooting time of 0.25 ms, another with a longer time of 5 ms, which adds to the 2940-nm Erbium the ability to cause tissue coagulation (Figure 1), although lower than that of CO<sub>2</sub>.

## MATERIAL AND METHODS

This was a pilot, open, and prospective study conducted at the Outpatient Dermatology Clinic of Hospital do Servidor Público Estadual de São Paulo. Six female patients were enrolled. Inclusion criteria was photoaging grades III and IV. Four patients had skin phototype II, one phototype III, and one phototype IV. The age of patients ranged from 56 to 72 years. Exclusion criteria were severe systemic diseases and/or diseases associated with photosensitivity. All patients were instructed about the procedure details, in pre, intra and postoperative periods, and signed an informed consent. This protocol followed the Ethical Guidelines of the 2000 Declaration of Helsinki.

The six patients were using tretinoin cream 0.05% on alternate days for years. There was no prescription of topical bleaching pre or postoperatively. Biopsy fragments were collected 1 week before and 2 months after treatment, fixed in 10% formalin, and processed for paraffin embedding. Staining was performed with hematoxylin-eosin for morphological analysis (thickness of the epidermis and its layers and atypical keratinocytes and melanocytes), Verhoeff's staining for analysis of elastic fibers (quantification of solar elastosis), and Masson's trichrome staining for collagen analysis (quantification of new collagen). Analysis of the results was made by a dermatopathologist through a blind method. The patients were photographed 1 week before and 2 months after the procedure with digital camera Canon EOS DS 6031 (Canon Inc, Japan). Photographs were standardized and always performed with front and side incidence. In preoperative period, patients used acyclovir 200 mg twice daily (2 days before, on procedure day, and two days after) to prevent herpes simplex and azithromycin 500 mg per day (on procedure day and two days after) for bacterial infection prophylaxis. Lidocaine cream 4% (Dermomax<sup>®</sup>) was used without occlusion, 45 minutes before the procedure.

The laser used was 2940-nm Erbium dual pulse, platform component StarLuXTM Pulsedlight&Laser System (Palomar Medical Technologies, Inc, Burlington, MA). This laser is an

Erbium-doped crystal Yttrium Aluminium Garnet (Er:YAG) that emits a wavelength of 2940 nm. Energy emission is by optical spot containing microbeams through which the rays are emitted. The spots vary in size of shooting area and also in density of microbeams (Table 1). The total number of rays released to the skin depends on the spot used and the number of passes during treatment. Pulse duration to be used can be 0.25 ms, 5 ms, or both contained in the same shot, characterizing the dual pulse. Metal glasses for eye protection and the following parameters were used: 1) red spot (10x10 mm) with standard pulse of 0.25 ms (two passes across the face with energy of 9 mJ/microbeam); 2) blue spot (6X6mm), which has a higher density of microbeams, combining pulse duration of 0.25 ms and 5 ms (dual pulse) with the same energy of 9 mJ/microbeam, 2 passes with 30% overlap in periorbital and perioral areas, and only 1 pass without overlapping the rest of the face. The procedure lasted on average 40 minutes. Immediately after, were used cold compresses to reduce the burning sensation. Solid Vaseline or saline were prescribed when and how often it was required to decrease the treated area dryness until complete reepithelization and sunscreen SPF 60 every 4 h after this period. A week later, patients returned to their routine topical medication.

## RESULTS

### Clinical

Immediate postoperative period (Figure 1) shows the difference in density of rays emitted by the spots. The photograph obtained after 7 days shows complete reepithelization, with residual erythema (Figure 2). Photos taken two months after procedure showed the clinical improvement observed (Figures 3 and 4) with marked reduction of melanosis, rhytides, and reduction of melanin pigments oxidation, changing the skin color. The only patient with skin phototype IV did not present any side effect, even when considering the possibility of hyperpigmentation due to intense inflammatory effect of the procedure itself (Figure 5). The only patient who, by her own decision, did not take acyclovir as prophylactic anti-herpes had labial herpes simplex, with a few vesicles, two days after the procedure and was treated with topical acyclovir.

Table 1 – Characteristic of optical spots

Spot (size)	Density of microbeams (µB/cm <sup>2</sup> )	Microbeam sizes (microns)
Blue: 6 x 6 mm	469	120 – 140
Red: 10 x 10 mm	169	210 – 230

Microbeam: structure of optical spots through which light rays are emitted.

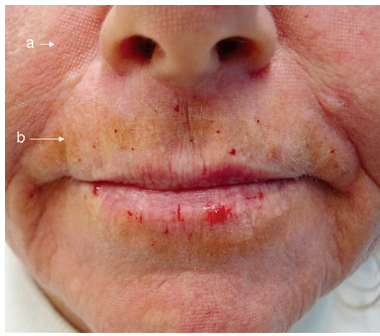

Figure 1 – Immediate postoperative period.  
A. Red spots : low density microbems, pulse of 0.25 ms.  
B. Blue spots : high density microbems, dual pulse of 0.25 ms + 5 ms.

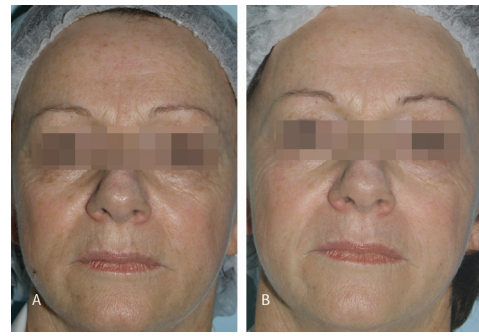

Figure 4 – Moderate photoaging (phototype II).  
A. Pretreatment.  
B. Two months after treatment: Decrease of rythides and melanosis.

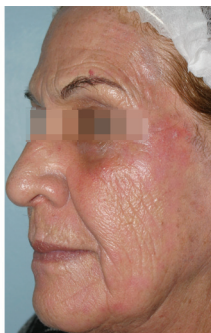

Figure 2 – Seven days after procedure. More pronounced erythema in periorbital area where dual pulse was applied (0.25 ms + 5 ms).

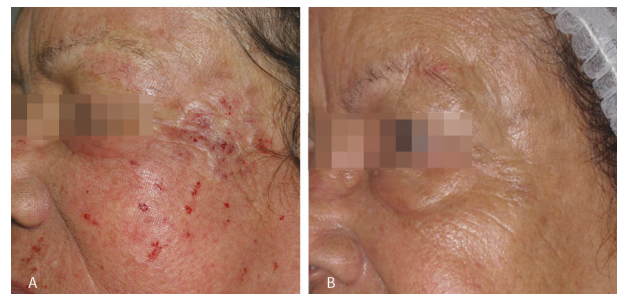

Figure 5 – Patient with skin phototype IV.  
A. Immediate postoperative period: dual pulse (0.25 ms + 5 ms) used in periorbital area.  
B. Two months after treatment: without pigmentary changes.

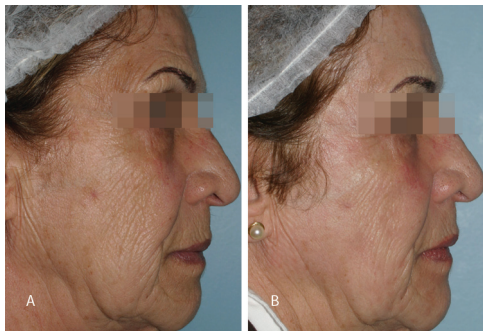

Figure 3 – Marked photoaging (phototype III).  
A. Pretreatment.  
B. Two months after treatment: marked decrease of rythides and improved skin color.

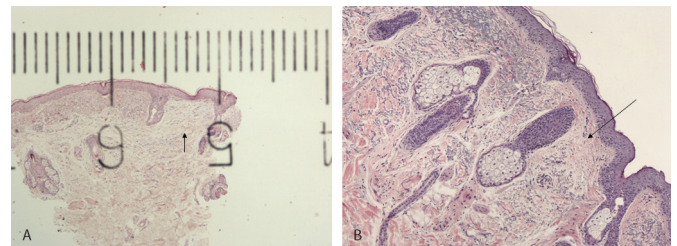


Figure 6 – A and B H&E staining  
Area with destruction of elastotic fibers and new collagen deposition (arrow).  
Case 1. H&E: original magnification 40 x 450 microns width x 200 microns depth  
Case 2. H&E: original magnification 100 x 200 microns width x 200 microns depth

### Histopathological

In hematoxylin–eosin staining, the main finding was a focal change produced by the ray emitted by microbeam. Measurement of these foci showed in one case almost the same dimension of 200 microns microbeam, and in another case it was slightly larger, 450 microns wide. In both cases the depth measure was 200 microns (Figure 6). Staining for elastic fibers (Verhoeff) showed marked reduction of

elastotic fibers (Figure 7) and in Masson's trichrome were observed fine collagen fibers and soft color, characteristic of new collagen fibers (Figure 8).

### DISCUSSION

Treatments with fractional ablative lasers have recently been performed due to its modified and recent technology. CO<sub>2</sub> laser causes more thermal damage and more pronounced

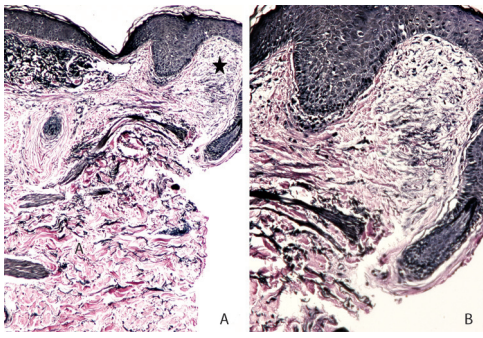


Figure 7 – A and B (case 2): elastic fibers staining (Verhoeff).  
A. Papillary dermis (star) with replacement of elastotic fibers by thinner fibers (pre-elastics). Original magnification 200x.  
B. Detail of Figure. A. Original magnification 400x

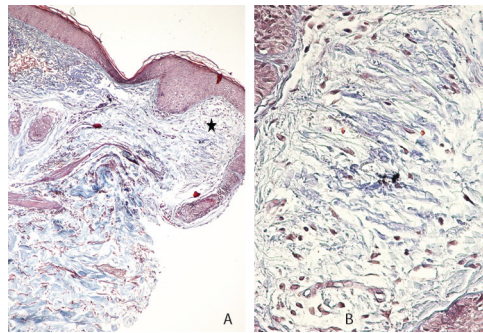


Figure 8 – A and B (case 2) staining for collagen fibers (Masson's trichrome).  
A. Papillary dermis with new collagen deposition (star). Original magnification 200x.  
B. Detail of Figure. A. Original magnification 400x.

results,<sup>10</sup> but its side effects are very well documented, since the time it was used in non-fractional mode.<sup>11</sup> The use of non-fractionated 2940-nm Erbium laser is a safer alternative, but with more subtle results. When 2940-nm Erbium laser (fractional or not) is used in traditional pulse of 0.25 ms, it is incapable of causing skin tissue coagulation, with bleeding occurring during procedure and no skin contraction. With a pulse of 5 ms, alone or associated with a pulse of 0.25 ms, coagulation zones occur around the micro-columns of ablation, thus adding an important effect on the final outcome,<sup>12</sup> with greater formation of new fibers, in addition to skin contraction. This effect appears to have occurred in the entire face, being more visible in the periorbital in which 2 passes were applied with dual pulse and overlap between them. More discrete results were observed in the perioral region, despite the 2 passes with dual pulse. This is an area of difficult response with all fractionated lasers. Of the laser technologies, only the conventional 10,600 nm CO<sub>2</sub> (not fractionated) causes a greater impact in this region when a single treatment is performed.

With the use of longer pulse, we observed marked improvement with only one treatment, considering that with the fractionating, only part of the skin is treated in one session. Another fact of great relevance to be considered is that the selected patients had a very strong degree of photoaging, which suggests that the results were very important. Most studies with fractionated 2940-nm Erbium are performed in patients with mild skin grades,<sup>13</sup> or moderate photoaging.<sup>14</sup> A study using fractionated 2940-nm Erbium with pulse of 0.25 ms and pulses of 1, 1.5 and 2 ms,<sup>14</sup> but not shot at the same time (not characterizing dual pulse), showed formation of new collagen and elastic fibers in non limited areas of dermis; these findings differed from the ones in our research.

In the present study, histological analysis was blind and the changes described were observed only in the samples after treatment, confirming the reliability of the analysis. Most current works are performed with postoperative period histological studies, and the width of the cleft caused by ablation and found histologically is about the same width of microbeam that emits rays. In this study, we found in one case the focus of repaired tissue with similar dimension to the microbeam and in another case twice the width of the microbeam. This greater width may be a consequence of the repair process or by coincidence of very close or even overlapping rays, as during procedure more than one pass were made with optical spots.

One advantage of using 2940-nm Erbium (fractionated or not) is that reepithelization is done quickly (2 to 3 days) and, on day 4 after surgery, patients can return to their daily activities (using corrective bases or not). Another advantage is the reduction of side effects caused by the fractionated Erbium compared to fractionated CO<sub>2</sub>.<sup>15,16,17</sup>

There are reports of cases treated with fractionated CO<sub>2</sub> without pigmentary changes in patients with higher skin phototypes,<sup>18</sup> although hyperpigmentation can occur with this technique.<sup>19</sup> Our only patient with skin phototype IV surprisingly did not show hyperpigmentation, although she has been subjected to the same parameters of the other patients and did not use bleaching creams before and/or after the procedure. This fact can be explained by individual pigmentary characteristics. In the case of treatments with fractional ablative lasers, CO<sub>2</sub> or 2940-nm Erbium, bleaching creams can be used routinely before the procedure in patients with skin types III to V.<sup>11</sup> Use of systemic medications for herpes simplex prevention is considered mandatory for patients who have history of previous outbreaks.

Another important fact is the pain that occurs during and after the procedure. In all six cases the pain was well tolerated with prior application of 4% liposomal lidocaine cream without occlusion, while in the procedure with fractionated CO<sub>2</sub> pain intensity is much greater, both intra-

and postoperatively.<sup>19</sup> After 2 months, we questioned patients about the results and the rate of satisfaction was high, although it has not been measured objectively. All patients said they would submit to a new session, as they found treatment well tolerated and with good results.

Therefore, we conclude that fractionated 2940-nm Erbium with pulses of 0.25 ms and 5 ms, when used in combination (dual pulse) and performed with multiple passes, is a technique presenting good results for cutaneous photoaging treatment, very safe and suitable for patients with mild to severe photoaging. As it is a fractionated treatment, we believe to be interesting to perform more than one session, especially for patients with photoaging grades III and IV.

### ACKNOWLEDGMENTS

To Dr. Bogdana Victoria Kadunc and Dr Gabriel Gontijo, for reviewing the article.

### REFERÊNCIAS

- Anderson RR, Parrish JA. Selective photothermolysis precise microsurgery by selective absorption of pulsed irradiation. *Science* 1983; 220:524-7.
- Alster TS. Clinical and histological evaluation of six Erbium: Yag lasers for cutaneous resurfacing. *Lasers Surg Med* 1992; 297-316.
- Fitzpatrick RE, Ruiz-Esparza J, Goldman MP. The depth of thermal necrosis using CO<sub>2</sub> laser: a comparison of the superpulsed mode and conventional mode. *J Dermatol Oncol* 1991; 17:340-4.
- Khatri KA, Ross V, Grevelink JM, Magro CM, Anderson RR. Comparison of the Erbium: Yag and carbon dioxide lasers in resurfacing of facial rhytides. *Arch Dermatol* 1999; 135:391-7.
- Berwald C, Lavy JL, Magadon C. Complications of the resurfacing laser: retrospective of 749 patients. *Ann Chirg Plast Esthet* 2004 Aug; 49(4):360-5.
- Sink RK, Hantahs Bm, Herrom GS, Rhaman Z, Struck SK, Zachary CB. The effect of pulse energy variations on the dimensions of microscopic thermal treatment zones in nonablative fractional resurfacing. *Lasers Surg Med* 2007; 39(2):145-55.
- Narurkar VA. Nonablative fractional treatment in the male patient. *Dermatol Ther* 2007; 20(6):430-5.
- Levy JL, Besson R, Mordon S. Determination of optimal parameters for nonablative remodeling with a 1,54 micron Er: glass laser: a dose response study. *Dermatol Surg* 2002; 28(5):405-9.
- Clementoni MT, Gilardino P, Gabriele FM, Beretta D, Schianti R. Non-sequential fractional ultrapulsed CO<sub>2</sub> resurfacing of photodamaged skin. Preliminary clinical report. *J Cosm Las Ther* 2007; 9:218-85.
- Ross EV, Miller C, McChank et al. One pass CO<sub>2</sub> versus multiple pass Er:YAG laser resurfacing of rhytides: a comparison side-by-side study of pulsed CO<sub>2</sub> and Er:Yag lasers. *Dermatol Surg* 2001; 27(8):709-15.
- West TB, Alster TS. Effect of the incidence of hyperpigmentation following cutaneous CO<sub>2</sub> laser resurfacing. *Dermatol Surg* 1999; 25:15-7.
- Dierickx CC, Khatri KA, Tannous Z, Childs JJ, Cohen R. Microfractional ablative skin resurfacing with two novel Erbium laser systems. *Laser Surg Med* 2008; 40(2):113-23.
- Lapidoth M, Odo M, Odo M. Novel use of Erbium YAG (2940 nm) for fractional ablative photothermolysis in the treatment of photodamaged facial skin: a pilot study. *Dermatol Surg* 2008 Aug; 34(8):1048-53. Epub May 6.
- Trelles MA, Mordon S, Velez, Urdiales F, Levy JL. Results of fractional ablative facial skin with erbium: yttrium-aluminium-garnet one week and two months later after one single treatment in 30 patients. *Laser Med Sci* 2009; 24(2):186-94. Epub 2008Feb19.
- Fife, D J, Fitzpatrick RE, Zachary CB. Complications of fractional CO<sub>2</sub> laser resurfacing: four cases. *Laser Surg Med* 2009; 41:179-84.
- Ross RB, Spencer J. Scarring and persistent erythema after a fractionated ablative CO<sub>2</sub> laser. *J Drugs Dermatol* 2008 Nov; 7(11):1072-3.
- Avram MM, Tope WD, Yu T, Szachowicz. Hypertrophic scarring of the neck following ablative fractional carbon dioxide laser resurfacing. *Laser Surg Med* 2009; 41:185-8.
- Tan KL, Kurniavati RN, Gold MH. Low risk of post inflammatory hyperpigmentation in skin types 4 e 5 after treatment with fractional CO<sub>2</sub> laser device. *J Drug Derm* 2008; 7:774-7.
- Campos VB, Mattos RA, Filippo AA, Torezan LAR. Laser no rejuvenescimento facial. *Surg Cosm Derm* 2009; 1:29-35.