

Original Article

Clinical evaluation of the efficacy of trichloroacetic acid and subcision, combined or isolated, for abdominal striae

Authors:

Maurício Shigueru Sato¹
Aline Fukuda²
Larissa Luvison Gomes da Silva³
Fabiane Mulinari-Brenner⁴
Rebecca Tung⁵

¹Fellow in Dermatological Surgery of the Dermatology Department - Universidade Federal do Paraná

²Fellow in Dermatological Surgery of the Dermatology Department - Universidade Federal do Paraná

³Resident of the Pathology Department - Universidade Federal do Paraná

⁴Dermatologist and Head of Dermatology Service, University Hospital of Curitiba - Universidade Federal do Paraná

⁵Dermatologist and Mohs Surgeon at the Cleveland Clinic Foundation - Ohio USA

Correspondence to:

Maurício Shigueru Sato
Rua Prudente de Moraes, 1241
Curitiba - PR - Brasil
CEP: 80430-220
Tel: +55 (41) 3362-7899
Fax: +55 (41) 3024-0607
E-mail: mash_mauricio@hotmail.com

Submitted on: 04/07/2009
Approved on: 10/25/2009
We declare no conflicts of interest.

ABSTRACT

Introduction: Striae are frequent complaints in dermatology, however most studies are based on the use of laser, and the effects of other treatment modalities are observed by few doctors.

Objective: To compare three therapeutic modalities: Subcision alone, trichloroacetic acid (TCA) 20% alone, and subcision combined with application of TCA 20% in treatment of striae.

Materials and Methods: Eleven female patients, skin phototype II-IV with striae gravidarum, had their lower abdomen divided into 4 quadrants. One stria of each quadrant was selected to be subjected to one of 3 procedures and 1 quadrant was the control. Objective evaluation was performed by the physician and subjective evaluation was performed by the patient.

Results: Reduction in width with subcision and in length with TCA 20% were observed by measurement. In the subjective evaluation, improvement was observed mainly with the subcision-TCA 20% treatment. Photographic evaluation was disregarded. At statistical analysis, there was no significant difference between treatments. There were no adverse effects related to treatments. **Conclusion:** Despite the reported improvement, especially with the subcision-TCA 20% treatment, there was no statistically significant difference between treatments.

INTRODUCTION AND OBJECTIVE

Striae is a quite common complaint in dermatology practice. However, there are only a few conclusive studies regarding effective treatments for this condition. Clinically, striae are linear or fusiform lesions of variable length and width according to the site and condition in which they develop. Striae gravidarum predominate in abdomen and breast and, associated with changes in weight, they predominate in arms and armpits.^{1,2,3} Lesions are usually asymptomatic and follow cleavage lines.⁴ They are always transverse to the direction of greatest tension: when major tension is horizontally applied, stria appears in vertical direction and vice versa.^{2,4} They may present slight burning and itching, but aesthetics is the main concern.¹

Color of striae depends on combination of microvascular component and size and activity of melanocytes.⁵ Clinical appearance is influenced by the patient's skin phototype and, in dark-skinned individuals, these two perceptions can be changed, since the human eye detect the difference in color between striae distensae and the surrounded skin.^{5,6} Striae can be erythematous (red), bluish (cerulae), white (alba), and blackened (nigra).^{6,7} In fair-skinned individuals, striae begin as erythematous or pink lesions, with a smooth and tense surface (redish), and gradually lose pigmentation becoming atrophic and white (alba).^{1,5} Striae cerulae appear in individuals who have used steroids for a long time, and nigras in patients with skin phototypes IV and V. In this case, the color appears to be controlled by a mechanical-biological process that activates or inhibits melanogenesis in dark-skinned people.^{5,6}

Histological findings of striae are similar to a scar: flattening of epidermis, attenuation of epidermal cones, and presence of thin collagen bands grouped mainly in the papillary dermis, which could also extend to deeper layers in horizontal direction to the epidermis. Special stains for elastic fibers showed that striae have absent and fine elastic fibers in some areas.^{5,7}

A variety of clinical conditions predispose the onset of striae, a common problem in dermatology. Pregnancy, adolescent growth spurt, infections, obesity, use of steroids, and physical activity with muscle hypertrophy are the most frequent conditions, justifying female predominance as a frequent cosmetic complaint. Among adolescents, 40% to 70% have striae while 90% of women have at least one area of striae after pregnancy. In the early stages, the lesions are usually red or pink (striae rubrae), becoming white and atrophic with evolution (striae alba). The etiology of striae is still unknown, but the role of endocrine conditions and skin stretching are accepted as triggering factors.^{1,3,7}

Striae predisposition was in the past associated with adreno-cortical hyperactivity, diabetes, and fibroblasts dysfunction; currently, however, the genetic predisposition seems to be the main triggering factor. After excessive skin stretching, to the rupture of dermal elastic fibers, fibroblasts become unable to adequately repair the extracellular matrix components responsible for skin resistance, and the striae appear. In vitro, skin with striae, or apparently normal skin of individuals with striae, shows a decrease in the rate of growth, migration and proliferation of fibroblasts with decreased production of elastin, fibrillin-1, collagen-1, and fibronectin, compared with the skin of individuals without striae, showing the previous susceptibility of these individuals.⁸ In striae gravidarum, the main risk factors are: low maternal age, weight gain, and newborn weight.³

Treatment options for striae are very limited and have disappointing results. Partial results have been reported with topical use of tretinoin, combined or not with glycolic acids or L-ascorbic acid. The new technologies derived from laser gained popularity and were used in striae treatment. The 585-nm pulsed dye laser is the most studied, with clinical and histological improvement after treatment.^{9,10,11,12} The 308-nm Excimer laser and 585-nm pulsed dye laser associated with non-ablative radiofrequency and intense pulsed light were also tested, but the high cost limits these forms of treatment.^{11,12,13,14,15,16,17}

New effective and easy to access methods are needed to facilitate the access to striae treatment. Subcision was initially described by Orentreich for treatment of scars and wrinkles in 1995.¹⁸ As stria is considered a cutaneous scar by many dermatologists, subcision could be a choice for treatment of this condition. There are few reports regarding the use of subcision for treatment of striae, with inconclusive results.¹⁹ On the other hand, there was improvement in the appearance of striae after the use of dermabrasion followed by TCA 15%.²¹ There are no publications on the use of subcision associated with TCA for striae treatment.

The purpose of this study was to observe and compare, in abdominal striae, the response to 3 treatment modalities: subcision alone, subcision combined with application of TCA 20%, and application of TCA 20% alone.

MATERIALS AND METHODS

We conducted a comparative, experimental, prospective, and longitudinal study with outpatients from the Dermatology Department of Hospital de Clínicas from Curitiba, Paraná.

Were included female patients with striae in the lower abdomen, with 18 years of age or older and no history of previous treatment. Patients with a history of hypertrophic scar or keloid, use of topical or systemic medication in the past year, pregnancy, and low capacity of understanding were excluded from the study. The study was approved by the Research Ethics Committee of the Hospital de Clínicas, and all patients signed an informed consent.

Striae were classified as red, alba, cerulae, or nigra according to color. The intensity was classified as mild, moderate, or severe according to their numbers in each quadrant. In clinical history, data such as skin type, age, sex, previous treatment, hypertrophic scar or keloid history, evolution time, and striae color were evaluated.

The lower abdomen was divided into 4 quadrants, and the umbilical scar considered as the upper limit. The size of each quadrant was 10 cm x 5 cm (length x width). One stria of each quadrant was selected to be subject to one of the procedures described below:

subcision alone: the area was cleaned with alcohol 70%, stria limits was marked with ink, using anesthesia with 2% lidocaine with epinephrine, followed by insertion of needle Nokor BD 18G into deep dermis, with forward and backward movements until layer dissection was performed without resistance;

TCA 20% alone: the area was cleaned with alcohol 70%, stria limits was marked with ink, and TCA 20% applied twice on stria with a cotton swab;

subcision+TCA 20: after completion of subcision according to the technique described above, TCA 20% was applied twice on stria with a cotton swab.

The last quadrant was reserved for control and received no treatment. Photographs were taken with camera Sony Super SteadyShot DSC-W 80 in auto-adjustment mode, with maximum zoom (3x) and without flash in each quadrant at baseline and 12 weeks after treatment.

Assessment of therapeutic response was as follows:

Objective: with observation of the lesion characteristics, measurement of striae length and width by the same investigator, and calculation of percentage change;

Subjective: the patient rated the result as: no improvement (0), poor (1-25%), fair (25-50%), good (50-75%), excellent (75-100%), for each of the 3 treatments;

Photographic: with observation of the treated areas before and after treatment by 2 independent dermatologists who classified the response as: no improvement (0), poor (1-25%), fair (25-50%), good (50- 75%), excellent (75-100%), for each of the 3 treatments.

For statistical analysis, the Wilcoxon Signed-Rank was used to compare the same treatment (before and after). For comparison between different treatments, the Kruskal-Wallis test was used with $p \leq 0.05$ considered statistically significant.

RESULTS

Eleven female patients were included in this study, with Fitzpatrick’s skin phototype II-IV, aged between 20 and 48 years (mean 30.6 years), and striae gravidarum in the lower abdomen without prior treatment. Ten patients had striae alba and one patiente had striae nigra. One stria was classified as severe, seven as moderate, and three as mild in intensity. Striae duration ranged from 8 to 480 months (mean 153.1 months). One patient did not complete the study due to follow-up loss. (Table 1).

In subjective evaluation by patients, there was improvement mainly with the subcision-TCA 20% treatment (Figure 1). Of the 10 patients treated, 6 reported improvement of more than 75% compared to the stria initial state. Patients treated with TCA 20% alone reported 50% improvement. However, only two patients reported improvement above 50% with subcision alone. There was difficulty in performing the striae length and width measurements. Some measures of width and length increased significantly after treatment, suggesting technical difficulties for the correct marking of points to be measured.

There was a decrease in width mainly with subcision (23.3%), followed by treatment with TCA 20% alone (15%), and after the combination of both (8.7%) (Figure 2).

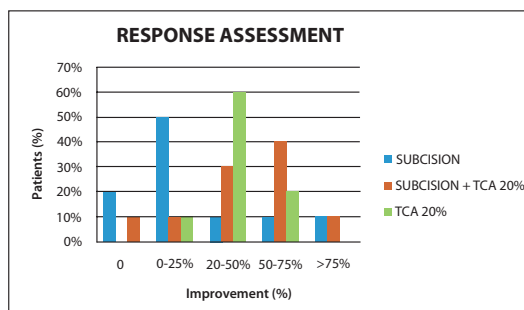


Figure 1 – Response assessment after treatment.

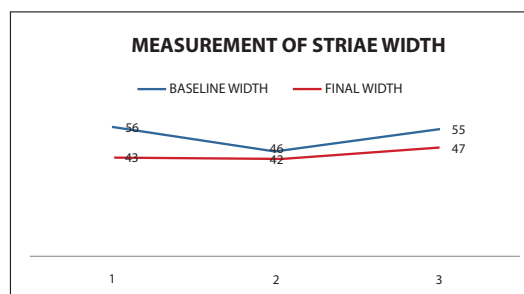


Figure 2 – Comparison between treatments concerning width.

Table 1 – Description of Patients Included in the Study

Patients	Sex	Age (years)	Fototype (Fitzpatrick)	Evolution (months)	Intensy	Color (stria)
	F	20	III	36	Moderate	B
	F	23	IV	9	Moderate	N
	F	22	IV	72	Moderate	B
	F	48	II	348	Discrete	B
	F	35	III	192	Moderate	B
	F	48	III	336	Moderate	B
	F	23	IV	72	Discrete	B
	F	26	IV	8	Moderate	B
	F	28	IV	48	Moderate	B
	F	42	IV	480	Discrete	B
	F	22	IV	84	Moderate	B

F, female; B, white or alba; N, nigra.

Regarding the decrease in length of striae, treatment with TCA 20% showed higher scores than the others treatments (18%), followed by subcision-TCA 20% (14%), and subcision alone (8.1%) (Table 2 and Figure 3). Despite these results, the overall performance of TCA 20% for abdominal striae treatment was considered only mild (Figure 4).

Color, texture, and overall appearance of striae were assessed at baseline and 3 months after treatment, presenting no difference by the investigator evaluation. Among adverse events, all patients reported tolerable discomfort during treatment, with no difference between tecniques and peeling of skin after treatment with TCA. There were no complications related to striae treatment.

Photographic assessment was performed by two independent dermatologists, but it was aborted due to the difficulty of a standardized measurement for photographs, the treatment of only one stria per quadrant, and the inconsistent results difficult to observe and classify on the suggested parameters.

DISCUSSION

There is no standard treatment for striae, and the options are very limited.²² The results are disappointing in demonstrating significant improvement. Most published studies involve the use of laser or new technologies of high cost. The 585 nm Pulsed

Table II – Percentage Decrease in Striae Measurement After Treatment

	Striae1 baseline	Striae1 final	Reduction %	Striae2 baseline	Striae2 final	Reduction %	Striae 3 baseline	Striae 3 final	Reduction %
Total width	56	43	23.3	46	42	8.7	55	47	15
Total length)	571	525	8.1	542	471	14	125	74.7	18

Striae 1, subcision; striae 2, subcision + TCA 20%; striae 3, TCA 20%.

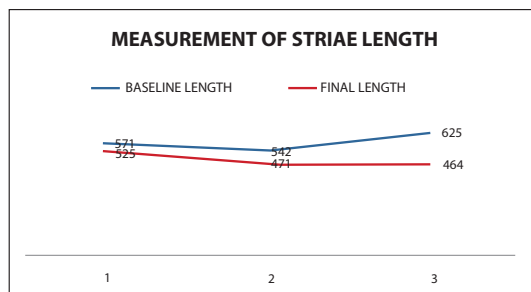


Figure 3 – Comparison between treatments concerning length.

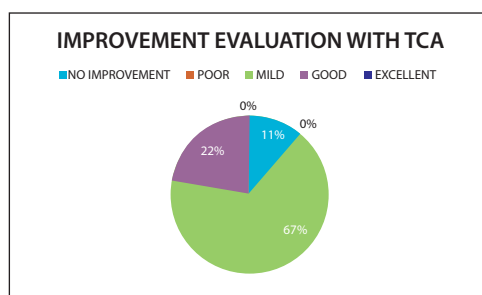


Figure 4 – TCA performance in striae treatment.

Dye laser is the most studied of all types, and has demonstrated clinical and histological difference after treatment.^{9,10} Other technologies used for striae treatment are Pulsed Dye Laser – PDL (585 nm) associated with radiofrequency Thermage®,¹¹ 308 nm Excimer laser,^{12,13} and intense pulsed light.¹⁴

Reports on chemical treatment of striae are also limited in literature. Many topical agents have been used. Elson ML showed that among 20 patients with striae of various etiologies treated with topical tretinoin 0.1%, 15 had significant improvement in photographic evaluations.²¹ However, Pribanich *et al.* failed to reproduce the same results with a concentration of 0.025% tretinoin in a blind study.²³ There are reports of improvement in red striae with 20% glycolic acid combined with tretinoin 0.05% or associated with L-ascorbic acid 10%.¹⁹ In 10 patients with striae alba, after 4 and 12 weeks of blind treatment, analyses by visual scale, profilometry and histopathologic analysis showed that both regimens improved the appearance of striae.

Evaluation of improvement and worsening in striae treatment is complex. Many previous studies have reported exclusive visual improvement, others report improvement in photographic evaluation. The profilometric method is a technique that allows quantification from the determination of a surface roughness factor. Contact profilometry is done with a profilometer equipped with a pointed edge to trace the skin surface, thus producing vertical movements which are converted into an electrical signal that is then integrated as a skin roughness factor. In this study, the fragility of the support in these criteria was clear, showing the need for histological complementation. Both patient and investigator subjective criteria can definitely affect the results evaluation, as well as the studies in which improvement may not have been evident. Biopsies before and after treatment are needed to evaluate the pattern of change in elastic and collagen fibers to clarify the achieved results.

Trichloroacetic acid (TCA) at a concentration of 35–50% has been used with variable results and complications when used in large areas. TCA could stimulate fibroblastic reaction.²⁰ The use of dermabrasion followed by TCA 15% in 69 patients of various skin phototypes and after 1 to 8 treatments (mean 4.2) showed 70% improvement in striae appearance, as assessed by both physician and patient.²⁰

Treatment with TCA 20% alone was responsible for a greater decrease in striae length (Table 2), which could validate the data obtained in the previous study. According to patients' evaluation, there was improvement mainly with subcision + ATA 20% treatment, and the worst results were observed with subcision alone (Figures 5 and 6). The improvement results by striae measurement before and after treatment were not concordant with the subjective analysis of the patients. There was a greater decrease in width with subcision and in length with TCA 20%, however, one must consider the technical difficulties in striae measurement (Figures 2 and 3).

There are no other studies in literature with these treatment modalities. Despite the limited response of subcision, there was no complication of this procedure, as described in a previous study.

CONCLUSION

The treatments of striae with ATA 20% associated or not with subcision seem to be effective in striae treatment. These treatments are low cost and proved to be safe in this study.

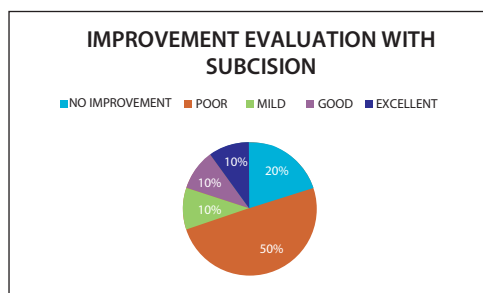


Figure 5 – Subcision performance in striae treatment.

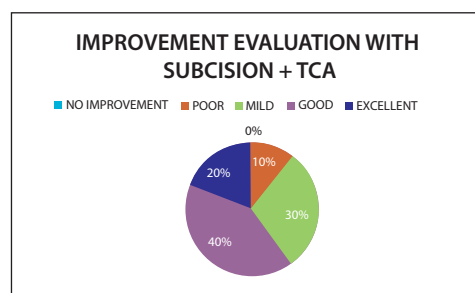


Figure 6 – Subcision + TCA 20% performance in striae treatment.

The subjective criteria and photographic assessment of striae improvement are fragile, and histological evaluation before and after treatment should always be included for an objective assessment and, preferably, blind for the modalities applied.

REFERÊNCIAS

- Sharon A, Salter MD, Alexa B *et al.* Striae gravidarum. *Clin Dermatol* 2006; 24:97-100.
- Cho S, Park ES, Lee DH *et al.* Clinical features and risk factors for striae distensae in Korean adolescents. *J Eur Acad Dermatol Venereol* 2006; 20:1108-13.
- Atwal GSS, Manku LK, Griffiths CEM *et al.* Striae gravidarum in primiparae. *Brit J Dermatol* 2006; 155:965-9.
- Mitts TF, Jimenez F, Hinek A *et al.* Skin biopsy analysis reveals predisposition to stretch mark formation. *Aesthetic Surg J*, 2005; 25:593-600.
- Franchimont CP, Hermans JF, Hermans T *et al.* Striae distensae in darker skin types: the influence of melanocyte mechanobiology. *J Cosmetic Dermatol* 2005; 174:178-4.
- Hermans JF, Piérard GE. High-resolution epiluminescence colorimetry of striae distensae. *J Eur Acad Dermatol Venereol* 2006; 20:282-7.
- McDaniel DH, Ash K, Zukowski M. Treatment of stretch marks with the 585-nm Flashlamp-Pumped Pulsed Dye Laser. *Am Soc Dermatol Surg* 1996; 22:332-7.
- Watson REB, Parry EJ, Humphries JD *et al.* Fibrillin microfibrils are reduced in skin exhibiting striae distensae. *Brit J Dermatol* 1998; 138:931-7.
- Jimenez GP, Flores FF, Berman B *et al.* Treatment of striae rubra and striae alba with the 585-nm Pulsed – Dye Laser. *Am Soc Dermatol Surg* 2003; 29:362-5.
- Groover IJ, Alster TS. Laser revision of scars and striae. *Dermatol Therapy* 2000; 13:50-9.
- Suh DH, Chang KY, Son HC *et al.* Radiofrequency and 585-nm Pulsed Dye Laser treatment of striae distensae: A report of 37 asian patients. *Am Soc Dermatol Surg* 2007; 33:29-34.
- Golberg DJ, Sarradet D, Hussain M. 308 nm Excimer laser treatment of mature hypopigmented striae. *Dermatol Surg* 2003; 29:596-9.
- Armenakas MRA, Bernstein LJ, Friedman PM *et al.* The safety and efficacy of 308-nm Excimer Laser for pigment correction of hypopigmented scars and striae alba. *Arch Dermatol* 2004; 140:955-60.
- Pérez EH, Charrier EC, Ibieta EV *et al.* Intense Pulsed Light in the treatment of striae distensae. *Dermatol Surg* 2002; 28:1124-30.
- Goldman AG, Rossato F, Prati C. Stretch Marks: treatment using the 1064nm Nd:YAG laser. *Dermatol Surg* 2008; 34:686-92.
- Tay YK, Kwok C, Tan E. Non ablative 1450-nm Diode Laser treatment of striae distensae. *Lasers in Surgery and Medicine* 2006; 38:196-9.
- Khenaizan SA. Nokor needle marking: A simple method to maintain orientation during subcision. *J Drugs Dermatol* 2007; 6:343-4.
- Montoya PL, Velázquez PP, Tomoka MTH *et al.* Evaluation of subcision as a treatment for cutaneous striae. *J Drugs Dermatol* 2005; 4:346-50.
- Ash K, Lord J, Zukowski M *et al.* Comparison of topical therapy for striae alba (20% Glycolic Acid/0,05% Tretinoin versus 20% Glycolic Acid/10% L-Ascorbic Acid). *Am Soc Dermatol Surgery* 1998; 24:849-56.
- Adatto MA, Deprez P. Striae treated by a novel combination treatment – sand abrasion and a patent mixture containing 15% trichloroacetic acid followed by 6-24 hours of a patent cream under plastic occlusion. *J Cosmetic Dermatol* 2004; 2:61-7.
- Elson ML. Treatment of striae distensae with topical tretinoin. *J Dermatol Surg Oncol* 1990 Mar; 16(3):267-70.
- Pribanich S, Simpson FG, Held B, Yarbrough CL, White SN. Low-dose tretinoin does not improve striae distensae: a double-blind, placebo-controlled study. *Cutis* 1994; 54:121-4.