

# A comparison of the immunological response to botulinum toxin type A in skin before and after axillary hyperhidrosis treatment

## ABSTRACT

**Introduction:** there are both unpublished and published anecdotal case reports of skin rash, acneiform eruptions and onset of *Herpes simplex* in patients injected with botulinum toxin for treatment of facial wrinkles and hyperhidrosis. We carried out a research to determine if there are immunological changes in the skin in ab initio treatment of patients with botulinum toxin. **Methods:** the immunological response to botulinum toxin type A was assessed in skin before and after its application in 15 patients with axillary hyperhidrosis. The following immunohistochemical markers were used to determine the local immunological profile before and after application of botulinum toxin: CD4+, CD8+, CD1a, CD25, anti-TNF- $\alpha$ , HLA-Dr, ICAM-1, anti-IFN- $\gamma$  and anti-IL-4. **Results and discussion:** a descriptive statistical analysis of each marker was carried out and the data were analyzed by Wilcoxon sign test. It was concluded that there was no alteration in skin after hyperhidrosis treatment with botulinum toxin a when markers were compared.

**Keywords:** axillary, hyperhidrosis, immunological response, botulinum toxin, hyperhidrosis treatment.

## INTRODUCTION

The most frequent complications with the use of botulinum toxin type A (BoNTA) and its application for cosmetic purposes described in the medical literature include ecchymosis, hematoma, pain, discomfort or a weight sensation in the forehead, acneiform eruptions, headache, paresthesia, eyebrow ptosis, keratoconjunctivitis, blurred vision, photophobia, diplopia, edema, transient erythematous papule, foreign body sensation in the eyes, migraine, strabismus, dysphagia and lacrimation.<sup>1,2</sup>

Complications that can occur due to the treatment of hyperhidrosis include muscle weakness, paresthesia, compensating hyperhidrosis, ecchymosis, hematoma, pain and complications from anesthetic techniques chosen and used by the physician.<sup>3-5</sup>

Complications related to other treatments include hypochromia,<sup>6</sup> pain, facial palsy, epiphora, difficulty chewing, ectropion, entropion, keratoconjunctivitis, blurred vision, photophobia, diplopia, conjunctivitis, ecchymosis, hematoma, edema, foreign body sensation in the eyes, diarrhea, migraine, cough, dysphonia, epistaxis, urinary infection, strabismus, lacrimation, muscle weakness (muscle fibrosis and atrophy), muscle changes due to wrong application, metal taste, transient neuronal trauma, hypotonia, cervical pain, respiratory obstruction, xerostomia and bladder dysfunction.<sup>7-13</sup>

Finally, the systemic symptoms described include general weakness, dry mouth and eyes, urinary retention, cold-like symptoms, botulism syndrome symptoms,<sup>14</sup> fatigue, nausea, vomit, skin exanthema, antibody formation, albumin allergy, myasthenic crisis, neuromuscular syndrome,<sup>10,12,13,15-18</sup> type I reaction<sup>12</sup> and necrotizing fasciitis.<sup>19</sup>

Some medications have human albumin and the risk of contamination and transmission of viral diseases, including Creutzfeldt-Jakob disease, cannot be ruled out.<sup>20</sup> The large-scale use

## Authors:

Bhertha Miyuki Tamura  
Luiz Carlos Cucé

## Correspondence to:

Bhertha Miyuki Tamura  
Rua Ituxi, 58, apt. 603  
Saúde – Rio de Janeiro – RJ  
CEP: 04055-020  
Phone: +55 (21) 5584-9354  
Fax: +55 (21) 5051-6961  
E-mail: bhertha.tamura@yahoo.com.br

Submitted on: 08/10/2009  
Approved on: 10/15/2009  
We declare no conflicts of interest.

of this medication for the treatment of several dermatological diseases, including the use for improvement of hyperkinetic wrinkle lines, has aroused our curiosity regarding the immunological changes that might occur in the skin.

We decided to study and compare the immunological repercussion of botulinum toxin type A in the skin, before and after its application in the treatment for axillary hyperhidrosis; for this study, we used the immunohistochemical markers anti-CD1a, CD4+, CD8+, CD25, TNF- $\alpha$ , HLA-DR, ICAM-1, IFN- $\gamma$  and IL-4. The selection of this disease and of the treatment site are due to the simple and fast technique, low morbidity, response from all patients to treatment and the possibility of performing skin biopsy in an unexposed area. Therefore, the patients accepted to participate in this study.

## METHODS

This is a non-randomized, coorte, quasi-experimental study. Fifteen patients with axillary hyperhidrosis were selected for treatment after being informed about therapy, how biopsies would be performed, follow-up visits and signing the informed consent term. There were 14 females and one male, age range of 19-56 years (mean of 33.5 years). Following the diagnosis of hyperhidrosis, we demarcated the compromised axillary area with the Minor test.<sup>2,5,21-23</sup>

Botulinum toxin was diluted with 4 mL of saline solution immediately before treatment. We injected (using 1-mL syringes and 30 G½ needles) two units per injection site in the intradermal region.<sup>1,3,24,26-29</sup> This dilution corresponds to the ratio of two units of medication to each 0.08 mL of solution. The distance maintained between the injection sites was 1.5 cm<sup>30-33</sup> and the injection technique used is shown in Figure 1.

In the first stage of the research, we injected botulinum toxin in the left axilla and performed a normal skin biopsy in the axillary fold of the right axilla. Thirty days after the first injection, we treated the right axilla and performed a skin biopsy in the axillary fold of the previously treated left axilla.

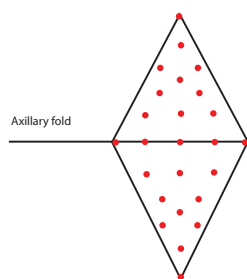


Figure 1 – Distribution of botulinum toxin injection sites in the axilla.

## Freezing Technique

The biopsy fragment to be sent for immunohistochemical evaluation was placed on a cork support and coated with a cryoprotective solution (Tissue-tek – Milles Laboratories, USA). Next, it was gradually frozen in a bottle containing liquefied isopentane (Reagen) in a liquid nitrogen environment, wrapped in aluminum paper and maintained in liquid nitrogen until processing.

## Immunohistochemical Technique

Imunoperoxidase technique on cryopreserved tissue was used and adjusted. It is the current technique applied by the Tropical Dermatology Laboratory of Sao Paulo (HC-FMUSP).

The frozen skin fragments underwent cryomicrotomy to obtain 4-micrometer thick fragments, collected with glass slides coated with adhesive solution of 3-aminopropyltriethoxysilane (Sigma Chemical Co., St Louis, MO/EUA, code A3648) followed by fixation with anhydrous acetone, pro-analysis, for 10 minutes at room temperature. After fixation, the specimens were submitted to immunohistochemical reaction with the method of streptavidin-peroxidase complex (modified from HSU, 1981).<sup>34</sup> The material was washed with distilled water and submerged in the Tris-HCL (hydroxymethyl aminomethane – chloridric acid) buffer at pH 7.4, for 5 minutes, at room temperature. Subsequently, the endogenous peroxidase was blocked with hydrogen peroxide (3% in Tris-HCL) and the fragment was submitted to three immersions in the Tris-HCL buffer for 5 minutes. The area surrounding the fragment was dried and the primary antibody diluted in bovine serum albumin (BSA) was added by drops. The dilutions of primary antibodies were standardized with the use of skin fragments of psoriasis (for antibodies anti-ICAM-1 and anti-CD1a) and tonsillar extracts, obtained after elective tonsillectomies for the antibodies anti-CD4+, anti-CD8+ and anti-HLA-DR. The material was incubated overnight in a humid chamber and, on the next day, the specimens were submitted to three immersions in Tris-HCL, for five minutes. After drying the area surrounding the fragment, the secondary biotinylated antibody was dripped, that is, the mouse anti-immune globulin G produced in rabbits for the following antibodies: anti-ICAM-1 (DAKO, code M7063, titer 1/100), anti-HLA-DR (DAKO, code M704, titer 1/150), anti-CD4+ (DAKO, code M0716, titer 1/100), anti-CD8+ (DAKO, code M7103, titer 1/100), anti-CD1a (DAKO, code M721, titer 1/100), anti-CD25 (DAKO, code M0731, titer 1/20), anti-TNF- $\alpha$  (Santa Cruz, code SC-1350, titer 1/50, IFN- $\gamma$  (R&D, code AF285-NA, titer 1/20) and for the anti-LihL-4 antibody (R&D, code AF204-NA, titer 1/20) (Table I).

Table I – Representation of surgical specimens obtained before and after treatment of axillary hyperhidrosis; they were evaluated with anti-CD1a markers in the epidermis, and with anti-CD4+, anti-CD8+ and anti-ICAM-1 in the dermis

	Anti-CD1a	Anti-CD1a	Anti-CD1a	Anti-CD1a	Anti-CD4	Anti-CD4	Anti-CD8	Anti-CD8	Anti-ICAM-1	Anti-ICAM-1
	Ep	Ep	Dermis	Dermis	Ep	Ep	Ep	Ep	Dermis	Dermis
	before	30 days	before	30 days	before	30 days	before	30 days	before	30 days
1	3.63	0.79			119	128	93	74	0.36	0.36
2	5.61	2.24	0.16	0.91	30	90	14	37	0.30	0.40
3	0.44	2.91	0.05	1.12	44	72	43	72	0.40	0.54
4	0.7	7.5	0.38	1.67	12	126	25	137	0.43	1.04
5	8.3	5.24	0.78	0.64	70	56	25	70	1.65	0.39
6	1.96	3.48	---	---	158	94	202	199	0.52	0.45
7	8.96	2.7	0.59	0.37	178	68	116	50	0.71	0.60
8	9.3	1.04	0.89	0.027	199	95	293	63	1.49	0.26
9	0.66	2.51	0.09	0.03	47	103	43	133	0.05	1.55
10	5.89	6.95	---	---	80	131	8	125	0.59	1.46
11	1.78	0.41	0.06	0.04	47	20	48	0	1.90	0.94
12	0.19	4.69	---	---	40	131	66	62	0.28	0.43
13	0.72	2.1	---	---	110	129	89	92	0.24	0.91
14	1.43	6.66	---	---	110	27	83	48	0.23	0.72
15	3.18	3.29	---	---	70	65	85	49	0.60	0.11
Média	3.51	3.5	0.37	0.60	87.6	89	84.1	83.6	0.65	0.68
P*	0.910		0.779		0.865		0.932		0.706	

After immersion of the specimens in Tris-HCL (three changes in five minutes), the area surrounding the fragment was dried. The tertiary complex streptavidin-biotin- peroxidase (StrepABC complex/HRP duet, mouse/rabbit, DAKO, code KO492) was placed in a 1:500 dilution, and the specimens were incubated in a humid chamber, for one hour, at 35-37°C. After this stage, they were immersed in Tris-HCL three times within five minutes.

Development of immunoperoxidase reaction was performed with a solution of 0.006% 3,3' diaminobenzidine hydrochloride (DAB) (Sigma Chemicals, code D-5637/D-8001) in a Tris-HCL buffer, added by 600 µL of hydrogen peroxide 20 volume (H<sub>2</sub>O<sub>2</sub>/20v) for three minutes.

After staining, the specimens were rinsed in distilled water. Counterstaining was performed with Carazzi's hematoxylin for one minute, and they were rinsed again for 5 minutes.

The material was dehydrated in an ascending chain of ethyl alcohol, diaphanized in xylol, coated with a Permount synthetic resin (Fisher Scientific Fair Lawn, NJ/USA, code SP15-100) and a cover slip.

The positive control of the reactions was obtained by observing the control fragments (psoriatic skin and tonsilla) concomitantly with the material being studied. The negative control of the reactions was indicated by the absence of primary antibodies that were replaced by the Tris-HCL buffer.

### Histomorphometric Evaluation of the Specimens Collected

A total of 32 slides with hematoxylin-eosin staining for control were prepared, and 288 slides were prepared for immunohistochemical reactions. Histomorphometric

evaluations were performed using the Kontron Eletronic 300 Image Analysis System. The workstation was composed of a binocular optical microscope (Zeiss), a color video camera (SONY CCD-Iris), image digitalizing plaque, a microcomputer with a 133 MHz Pentium processor, IBM-PC compatible, operating in Windows 95 – 32bits.

Images were digitalized with the aid of a specific program for image analysis (Kontron 300), which allowed sharing of data with the text processor (Microsoft Word) and electronic spreadsheet (Microsoft Excel). The use of these programs determined the treatment analysis and interpretation, acquisition of measurement values of the structures with all possible variables and automatic distribution of data generated by the image analysis station for electronic spreadsheets and text processor.

The histological fragments were processed in the image analysis system using 2x and 4x objective lenses, and 10x ocular lenses. This quantification was performed in the smallest spatial unit called pixel. The calibration factor (CF) was automatically calculated in pixels and this factor was used by the program for calculations in corresponding micrometers (µm) according to calibration.

Skin represented in the histological sections of the specimens was analyzed with random evaluation of the dermis and epidermis. The area fraction was analyzed with a 20x magnification (anti-CD1a, anti-ICAM-1 and anti-TNF-γ). The cell count was performed with counts per field with a 40X magnification and a total of 10 fields per slide were counted (anti-CD25, anti-LihL-4, anti-CD4+, anti-CD8+, anti-IFN-γ and anti-HLA-DR). The mean of these fields was counted for obtaining the final results.

The count of structures that could be well individualized, such as CD4+ and CD8+ lymphocytes in the dermo-epidermal junction, Langerhans cells in the epidermal area, dermal ICAM-1 and HLA-DR, was oriented by the cell nuclei. Stained vascular endothelium was disregarded in the count of ICAM-1 and HLA-DR due to the occurrence of this event in normal skin.

The count of individualized structures such as CD-25, anti-LihL-4, anti TNF- $\alpha$  and anti-IFN- $\gamma$  was oriented by immunohistochemical labeling in cytoplasm. In such cases, the stained nuclei were disregarded. The reading and count were carried out by a skilled and well-trained observer.

### Statistical Analysis

The statistical analysis involved the use of a statistical package called SPSS 10.0 for Windows. Descriptive statistical analysis was performed in order to observe the frequency, mean, median, standard deviation and other parameters; that is, the descriptive statistics illustrates more clearly the data distribution and behavior.

For evaluation of the possible immunological changes in the skin according to the immunohistochemical aspect, before and after injection of the BoNTA, the non-parametrical statistical analysis was used by means of the Wilcoxon sign test.<sup>35,36</sup>

### RESULTS AND DISCUSSION

Slides stained with hematoxylin-eosin showed in all cases the presence of normal skin that was compatible with the area studied.

Figures 2 through 8 show the evaluation and number of structures that could be well individualized; the photographs are representations of the labeled specimens indicating the cells or areas that were evaluated by the digitalized photograph system described in the methods section. The structures are exhibited as follows: CD4+ (Figure 2) and CD8+ (Figure 3) lymphocytes in the dermo-epidermal junction; Langerhans cells (Figure 4) in the epidermal region; dermal ICAM-1 (Figure 5) and HLA-DR (Figure 6) oriented by the cell nuclei. CD-25 (Figure 7), anti-LihL-4 (Figure 8), anti TNF- $\alpha$  and anti-IFN- $\gamma$ , were oriented by the immunohistochemical labeling in the cytoplasm.

Initially, a descriptive statistical analysis was performed for each marker with values that were comparable (Table II). Afterwards, the data were analyzed with the Wilcoxon sign test (Tables III, IV, and V). The evaluation of fragments obtained from the patient's skin, before and after the treatment for axillary hyperhidrosis, regarding the immunohistochemical aspect resulted in the following data:

The anti-CD1a pre-treatment immunohistochemical labeling showed a minimum of 0.19 labeled cells/field and a maximum of 9.3 cells/field (mean of 3.51 cells/field); anti-

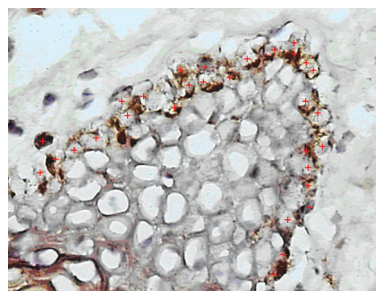


Figure 2 – Individualization of labeled cells (identified in the photograph with red signs) with anti-CD4+ antibody for cell count. The arrows point to some of these cells (magnification 40X).

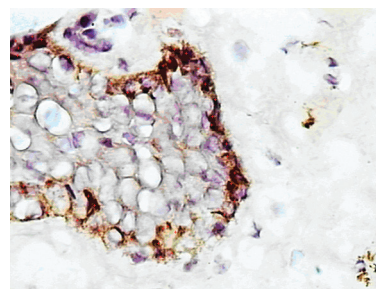


Figure 3 – Individualization of labeled cells (identified in the photograph with red signs) with anti-CD8+ antibody for cell count. The arrows point to some of these cells (magnification 40X).

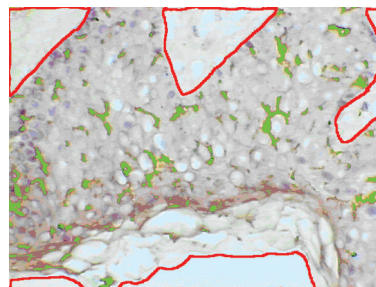


Figure 4 – Delimitation of epidermis (red line) and individualization of cells labeled with anti-CD1 antibody for cell count (filled out with green) (magnification 20X).

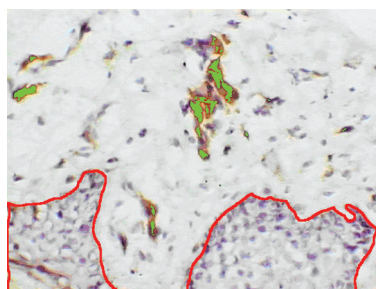


Figure 5 – Individualization of dermis and epidermis (red line) and cells labeled with anti-ICAM-1 antibodies for cell count which are being filled by the green color (magnification 20X).

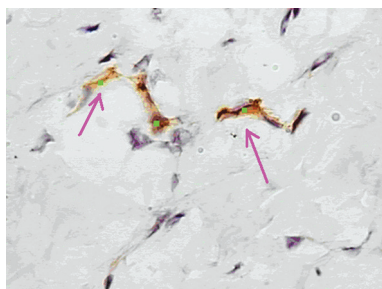


Figure 6 – Individualization of labeled cells (green signs according to the arrows) with anti-CD 25 antibody for count (magnification 40X).

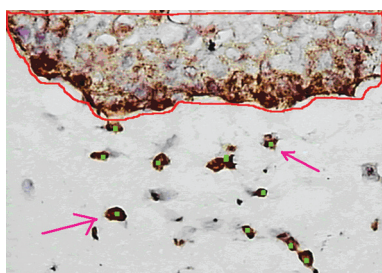


Figure 7 – Individualization of epidermis, dermis (red line) and cells labeled with anti-LihL-4 antibody for count (green signs) (magnification 40X).

CD4+ with a minimum of 12 and a maximum of 199 cells/field (mean of 87.6 cells/field); anti-CD8+ with a minimum of 8 and a maximum of 293 cells/field (mean of 84.1 cells/field).

The anti-CD1a post-treatment immunohistochemical labeling showed a minimum of 0.41 labeled cells and a maximum of 7.5 cells/field (mean of 3.5 cells/field); anti-CD4 with a minimum of 20 and a maximum of 131 cells/field (mean of 89 cells/field); anti-CD8+ with a minimum of 0 and a maximum of 293 cells/field (mean of 83.6 cells/field).

The immunohistochemical evaluation of the slides using anti-ICAM-1 marker in pre-treatment skin showed a minimum value of 0.045 and a maximum value of 1.9 cells/field (mean of 0.62 cells/field) and post-treatment values of 0.11 (minimum) and 1.55 cells/field (maximum); mean of 0.7 cells/field. In Table II, the level of significance considered was 0.05 in the Wilcoxon sign tests.

The anti-CD25, anti-TNF- $\alpha$ , anti-HLA-DR, anti-LihL-4 and anti-IFN- $\gamma$  pre-treatment immunohistochemical labeling showed only one positive case, with a pre-treatment cell count of 30 and a post-treatment count of 28 cells/field for anti-CD25, and the other pre- and post-treatment values were 2.05 and 6.85; 58 and 64; 0 and 85; 22 and 26 cells/field, respectively.

The pre- and post-treatment data analysis obtained with anti-CD4+ and CD8+ markers with Wilcoxon sign tests

Table II – Pre- and post-treatment data analysis obtained with anti-CD4+ and CD8+ markers with Wilcoxon sign tests

	Anti-CD4+ before	Anti-CD4+ 30 days	Anti-CD8+ before	Anti-CD8+ 30 days
Mean	87.60	89.00	87.00	80.73
Median	70.00	94.00	80.00	70.00
Standard deviation	56.51	37.11	73.42	49.52
Minimum	12	20	14	0
Maximum	199	131	293	199

shows that there was no significant difference between the pre- and post-treatment stages (Table III).

When analyzing the data in detail, we observe a decrease in variability (see standard deviation) for the markers, except for anti-CD1a expressed in the dermis. Another way to observe this result when only the anti-CD1a marker is analyzed is that the minimum and maximum values significantly changed, thus reducing data dispersion. However, if we apply the test to analyze the means, we come to the conclusion that the response for the anti-CD1 immunohistochemical marker in the dermis before and after treatment is the same (Table IV). Applying the Student's *t*-test, we also conclude that there is no significant difference between the results obtained.

For anti-TNF- $\alpha$ , anti-CD25, anti-HLA-DR, anti-LihL-4, IFN- $\gamma$  and anti-ICAM-1 markers in the epidermis, no conclusion was achieved based on the data collected, since the results obtained were negative in almost all slides analyzed.

The analysis of pre- and post treatment data obtained with anti-ICAM-1 marker in the dermis using the Wilcoxon sign tests did not show any significant difference in the both stages (Table 5).

Table III – Analysis of pre- and post-treatment data obtained with anti-CD1a marker using the Wilcoxon sign test

	Anti-CD1a Epidermis	Anti-CD1a Epidermis	Anti-CD1a Dermis	Anti-CD1a Dermis
Mean	3.5167	3.5007	0.3750	0.6009
Median	1.9600	2.9100	0.2700	0.5050
Standard deviation	3.2770	2.2494	0.3307	0.6016
Minimum	0.19	0.41	0.05	0.03
Maximum	9.30	7.50	0.89	1.67

Table IV – Analysis of pre- and post-treatment data obtained with anti-ICAM-1 marker using the Wilcoxon sign tests

	Anti-ICAM-1 Antes	Anti-ICAM-1 30 dias
Mean	0.6497	0.6773
Median	0.4300	0.5400
Standard deviation	0.5644	0.4246
Minimum	0.05	0.11
Maximum	1.9	1.55

## DISCUSSION AND CONCLUSION

Immune reactions were approached under different aspects according to the literature review, resulting in an update of current and past research.

Our study aimed to evaluate possible changes in immunity in the skin of patients receiving BoNTA injection. To this date, we have not found in the medical literature any study that addressed this issue regarding the action of this drug in the skin. We found a report of one patient who was treated for facial hyperkinetic wrinkles with BoNTA four times; one week after each injection, including the first one, the patient developed a herpes simplex in the area treated.

Despite its large-scale use for treatment of expression wrinkles and hyperhidrosis, there is no clinical and laboratory observation regarding what really happens in the skin. These facts aroused our interest in evaluating the immune behavior in the skin before and after the use of this medication.

The second biopsy in this study was performed 30 days after injection of the drug, based on studies in the medical literature suggesting that the process of recognition and activation of the immune system takes 20 to 30 days. This time period is respected and the recommendation so far is that re-injection of BT should be avoided before this interval in order to minimize the occurrence of sensitization<sup>16,37</sup>.

We demonstrated that the skin does not present any immunological abnormality caused by the injection of the dosages used by most physicians to treat hyperhidrosis, when analyzing anti-CD4+, CD8+, HLA-DR, ICAM-1, TNF- $\alpha$ ; CD25; LihL-4 and IFN- $\gamma$  and anti-CD1a markers in the epidermis and dermis.

Immune markers were chosen with the purpose of defining a profile of cellular immunity and to know if there is any humoral stimulation in this kind of treatment. When analyzed separately, patients 3 and 4 showed increased reactions after treatment and patients 7, 8 and 11 showed decreased reactions (Table 2).

Would there be individual differences in immunological response of the skin after treatment of hyperhidrosis, both in terms of T-cell mediated immune response and humoral response in some individuals? And what would be the behavior of these patients after the second injection of the medication? A more detailed evaluation would be very interesting, applying the protocol used by Larsen *et al.* (1990)<sup>37</sup>, Lukas *et al.* (1996)<sup>38</sup> and Sugiura *et al.* (2003),<sup>39</sup> tracking cell migration with biopsies after 24 and 48 hours in addition to evaluation after 30 days. We believe this study should be performed starting from our research to try to determine if there is a local inflammatory response that is dependent or non-dependent on host mediators or the level of involvement of epidermal dendritic cells in intensity of the skin immune response to chemical products according to Lappin *et al.* (1996).<sup>40</sup>

Therefore, in our work we conclude that:

There was no change in the skin before or after treatment of hyperhidrosis with botulinum toxin type A when anti-CD4+, anti-CD8+, anti-HLA-DR, anti-ICAM-1, anti-TNF- $\alpha$ , anti-CD25, anti-LihL-4, anti-IFN- $\gamma$  and anti-CD1a markers in the epidermis and dermis were evaluated according to the techniques proposed in this study.

## REFERÊNCIAS

- Guyuron B, Huddleston SW. Aesthetic indications for botulinum toxin injection. *Plast Reconstr Surg* 1994; 93:913-8.
- Carruthers A, Kiene K, Carruthers J. Botulinum A exotoxin use in clinical dermatology. *J Am Acad Dermatol* 1996; 34:788-97.
- Glogau RG. Botulinum A neurotoxin for axillary hyperhidrosis. *Dermatol Surg* 1998; 24:817-9.
- Glogau RG. Treatment of palmar hyperhidrosis with botulinum toxin. *Semin Cutan Med Surg* 2001 Jun; 20(2):101-8.
- Lowe NJ, Yamauchi PS, Lask G *et al.* Efficacy and safety of botulinum toxin type A in the treatment of palmar hyperhidrosis: a double-blind, randomized, placebo-controlled study. *Derm Surg* 2002; 28(9):822-7.
- Friedland S, Burde RM. Porcelainizing discolorization of the periocular skin following botulinum A toxin injections. *J Neuro-Ophthalmol* 1996 Mar; 16(1):70-2.
- Borodic G, Johnson E, Goodnough M, Schantz E. Botulinum toxin therapy, immunologic resistance, and problems with available materials. *Neurology* 1996; 46:26-9.
- Poewe W, Deuschl G, Nebe A *et al.* What is the optimal dose of botulinum toxin A in the treatment of cervical dystonia? Results of a double blind, placebo controlled, dose ranging study using Dysport. *J Neurol Neurosurg Psychiatry* 1998; 64:13-7.
- Brashear A, Lew MF, Dykstra DD *et al.* Safety and efficacy of NeuroBloc (botulinum toxin type B) in type A-responsive cervical dystonia. *Neurology* 1999 Oct 22; 53(7):1439-46.
- Brashear A. The botulinum toxin in the treatment of cervical dystonia. *Semin Neurology* 2001; 21(1):85-90.
- Brashear A, Gordon MF, Elovic E *et al.* Botox post-Stroke spasticity study group. Intramuscular injection of botulinum toxin for the treatment of wrist and finger spasticity after stroke. *N Engl J Med* 2002 Aug 8; 347(6):395-400.
- Klein AW. Complications and adverse reactions with the use of botulinum toxin. *Semin Cutan Med Surg* 2001 Jun; 20(2):109-20.
- Murray C, Solish N. Metallic taste: an unusual reaction to botulinum toxin A. *Dermatol Surg* 2003; 29:562-3.
- Tugnoli V, Eleopra R, Quatralo R *et al.* Botulism-like syndrome after botulinum toxin type A injections for focal hyperhidrosis. *Br J Dermatol* 2002 Oct; 147(4):808-9.
- Bell MS, Vermeulen LC, Sperling KB. Pharmacotherapy with botulinum toxin: Harnessing Nature's most potent neurotoxin. *Pharmacotherapy* 2000; 20(9):1079-91.
- Borodic G, Johnson E, Goodnough M, Schantz E. Botulinum toxin therapy, immunologic resistance, and problems with available materials. *Neurology* 1996; 46:26-9.
- Borodic G. Myasthenic crisis after botulinum toxin. *The Lancet* 1998 Dec; 352(9183):1832.
- Lange DJ, Rubin M, Greene PE *et al.* Distant effects of locally injected botulinum toxin: a double-blind study of single fiber EMG changes. *Muscle Nerve* 1991 Jul; 14(7):672-5.
- Latimer PR, Hodgkins PR, Vakalis AN *et al.* Necrotizing fasciitis as a complication of botulinum toxin injection. *Eye* 1998; 12(1):51-3.
- Schaffner R, Kreyden OP. Complications and side-effects of botulinum toxin A. *Curr Probl Dermatol* 2002; 30:141-8.
- Moraru E, Auff E, Schider P. Hyperhidrosis of the palms and soles. *Curr Probl Dermatol* 2002; 30:156-96.
- Hund M, Kinkelin I, Naumann M, Hamm H. Definition of axillary hyperhidrosis by gravimetric assessment. *Arch Derm* 2002 Apr; 138:539-40.
- Naumann M, Davidson JRT, Glaser DA. Hyperhidrosis: current understanding, current therapy cme. [www.medscape.com/viewprogram/1540](http://www.medscape.com/viewprogram/1540) Feb 28, 2003.
- Glogau RG. Botulinum A neurotoxin for axillary hyperhidrosis. *Dermatol Surg* 1998; 24:817-9.
- Schneider P, Binder M, Kittler H *et al.* A randomized, double-blind, placebo-controlled trial of botulinum A toxin for severe axillary hyperhidrosis. *Br J Dermatol* 1999 Apr; 140(4):677-80.

26. Schnider P, Moraru E, Kittler H *et al.* Treatment of focal hyperhidrosis with botulinum toxin type A: long-term follow up in 61 patients. *Br J Dermatol* 2001; 145(2):289-93.
27. Naver H, Swartling C, Aquilonius SM. Palmar and axillary hyperhidrosis treated with botulinum toxin: one-year clinical follow-up. *Eur J Neurol* 2000; 7(1):55-62.
28. Heckmann M. Hyperhidrosis of the axilla. *Curr Probl Dermatol* 2002; 30:149-55.
29. Tamura BM, Chang B. Marking techniques and their influence on hyperhidrosis treatment in hyperhidrosis and botulinum toxin. *São Paulo ART Almeida & DM Hexsel* 2004: 141-7(a).
30. Goldman, A. Treatment of axillary and palmar hyperhidrosis with botulinum toxin. *Aesth Plast Surg* 2000 24:280-2.
31. Heckmann M, Ceballos-Baumann AO, Plewig G. Botulinum toxin A for axillary hiperhidrosis (excessive sweating). *N Engl J Med* 2001 Feb; 344(7):488-93(a).
32. Heckmann M, Schaller M, Breit S, Plewig G. Evaluation of therapeutic success of hyperhidrosis therapy. *Arch Dermatol* Jan 2001; 137(1):94(b).
33. Naumann M. Evidence-based medicine: botulinum toxin in focal hyperhidrosis. *J Neurol* 2001; 248(Suppl 1):I/31-I/33.
34. Hsu H, Watanabe J. The inactivation profile of rabbit muscle creatine phosphokinase in Tris-acetate buffer solutions. *Chem Pharm Bull (Tokyo)* 1981 Nov 29(11):3350-5.
35. Moron, CMA. Estudo clínico e imunohistoquímico da dermatite de contato das mãos. Dissertação de mestrado. Faculdade de Medicina da Universidade de São Paulo 2001:45-6.
36. Herrmann J, Mall V, Bigalke H *et al.* Secondary non-response due to development of neutralizing antibodies to botulinum toxin A during treatment of children with cerebral palsy. *Neuropediatrics* 2000 Dec; 31(6):333-4.
37. Larsen CP, Steinman RM, Wirmer-Pak M *et al.* Migration and maturation of Langerhans cells in skin transplants and explants. *J Exp Med* 1990; 172:1483-93.
38. Lukas M, Stossel H, Hefel L *et al.* Human cutaneous dendritic cells migrate through dermal lymphatic vessels in a skin organ culture model. *J Invest Derm* 1996 Jun; 106(6):1293-9.
39. Sugiura K, Shamoto M, Sakamoto N *et al.* It is true that, when Langerhans cells migrate from the skin to lymph node, they are transported via lymph vessels. *Dermatol* 2003; 206(3):222-4.
40. Lappin MB, Kimber I, Norval M. The role of dendritic cells in cutaneous immunity. *Arch Dermatol Res* 1996 Mar; 288(3):109-21.