

Surgery technique report

Split earlobe repair: literature review and new technique proposal

ABSTRACT

Split earlobe usually results from sudden trauma or continuous use of heavy earrings. Among the various surgical techniques proposed for split earlobe correction, the choice will depend on the existing split, partial or total, and should offer a lower chance of recurrence. The total split corrections may be made with or without preservation of the earring orifice. Lobe fixation during intervention is essential, whatever the technique used, and can be done with tongue blade or sterile chalazion clamp. For the surgical procedure, we used Adson clamp, iris scissors, and scalpel blade 11 or 15. Skin suture was done with mononylon 5.0 or 6.0. In the new technique, besides the advantage of maintaining the orifice, there is greater security to support the earring with less chance of recurrence.

Keywords: ear, external ear, acquired ear deformities, otologic surgical procedures, outpatient surgical procedures.

INTRODUCTION

Split earlobe usually results from sudden trauma or continuous use of heavy earrings. There are several surgical techniques to correct the defect, and the correction depends on the existing cleft. Defects can be divided into partial cleft, which is the occurrence of cleft enlargement, or total cleft, which is the occurrence of lobe splitting into two or three points.

Corrections of total cleft are divided into two major groups: with or without preservation of the earring orifice. In the first case, a new orifice can be made after at least six months of healing. It is important to note that the region is prone to non-aesthetic scars, both reversed and hypertrophic, or keloid.

The procedure is done with local anesthesia through the blockage of the ear with lidocaine 1 or 2% and a vasoconstrictor, and may be supplemented with a solution containing 10 mL lidocaine 2% without vasoconstrictor, and 0.3 mL of adrenalin applied on the same lobe. Previous surgical marking should be performed, and minimum amount of solution should be infiltrated to prevent surgical field deformation.

With any technique performed, lobe fixation during the intervention is mandatory and can be improvised with sterile tongue blade, which is positioned under the ear lobe and handled by the assistant surgeon, giving support to the surgical procedure. A clamp for chalazion used by ophthalmologists for eyelid eversion, when available, is of great utility. In addition to stabilizing the lobe position, it also promotes hemostasis facilitating the action of a surgeon. For the procedure, delicate surgical material is used, such as Adson clamp, iris scissors and scalpel blade 11 or 15. Suturing with mononylon 5.0 or 6.0 are good options for closure.

Regardless of the technique to repair the lobe, the postoperative period presents no complications, and the local hygiene and dressing changes can be performed at home. Some techniques require more care than others, for example, the one in which the orifice is maintained, and the earring is placed intraoperatively. In this case, care is needed in handling dressing changes so the earring does not leave the ear neither damages the lobe.

Authors:

Adriana Alves Ribeiro¹
Luciana de Matos Lourenço²
Thais Helena Cardoso de Barros
Matsuda³
Nelson Marcos Ferrari⁴

¹Voluntary Dermatologist –
Dermatologic Surgery Department
of Santa Casa de São Paulo

²Assistant Dermatologist –
Dermatology Department of
Faculdade de Medicina da Fundação
do ABC

³Intern Doctor – Clinic of
Dermatology Santa Casa de São
Paulo

⁴Assistant and chief of the
Dermatologic Surgery Department
– Santa Casa de São Paulo; Volunteer
at Dermatology Department of
FMFABC

Correspondence to:

Adriana Alves Ribeiro
Rua Bento de Andrade 486
São Paulo – SP
Tel: +55 (11) 3887-4615
E-mail: adrialvesribeiro@uol.
com.br

Submitted on: 05/10/2009
Approved on: 08/20/2009
We declare no conflicts of interest.

Earlobe repair with partial cleft

There are three techniques used for this repair. The technique with punch or Tan¹ is a good option if the cleft is smaller than 4 mm.

The punch, one millimeter larger than the cleft, is positioned perpendicular to the lobe, and its rotation movement de-epidermises the cleft from its front to the back side; i.e., throughout its length. The skin should be pulled by the tip of the lobe during the punch action, which results in an incision and consequent transverse suture in relation to the lobe. Hence, we have increased security in making a new orifice and a lower probability of recurrence. The orifice should be done six months after complete healing.

Cleft can also be repaired using the partial direct closure edge to edge, indicated when the cleft is greater than 4 mm. Initially, the cleft is sufficiently de-epidermized with a scalpel so that there is a proper healing and prevention of scar reversal. The wound is sutured edge to edge with simple or mattress stitches (Donatti or U point), both in front and in back, taking care that the stitches do not cross the extension of the lobe wall. Stitching with absorbable sutures in the subcutaneous tissue can be performed.

The third option for the correction of partial cleft is the Reiter and Alford technique² (Figure 1), also called “parallel opposing flaps”. The flaps have created pedicles along the edge of the slit, one in front at the right side and another in the back at the left side of the lobe. The flaps are rotated as saloon doors and each one will cover the raw area of the other when sutured, making the cleft disappear.

Earlobe repair with total cleft

It is more difficulty to repair because the inferior lobular margin was lost. The original orifice can be kept or not. To prevent the occurrence of scar reversal through retraction,

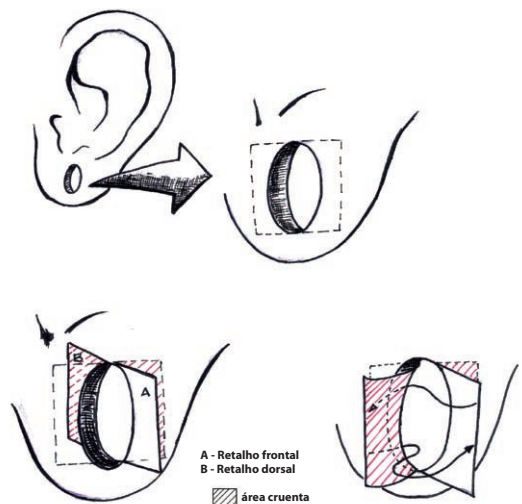


Figure 1 – Reiter and Alford technique (parallel opposing flaps) - (A) Frontal flap, (B) Dorsal flap.

techniques that promote eversion, such as Z-plasty, L-plasty or flap in V, are used to correct the final appearance of the scar.

Earlobe repair with total cleft without preserving the orifice

When there is no desire to keep the earring orifice, the widely used technique edge to edge, or side by side, is probably the most used in our area and easy to perform; since the new hole is not in line with the scar, the possibility of recurrence is small.

The technique consists in de-epidermizing the cleft and making a stitch repair at the lower end connecting the tips of the cleft, which guides the anterior and posterior sutures, also avoiding dissimilarity in the new lobe contour. Vertical mattress stitches (upright or “U” stitches) or horizontal (lying down or Donatti stitches), which evert the scar edges, are used to prevent inversion (Figure 2).

Variations were created to avoid scar reversal and give greater consistency to earlobe suture. Casson’s technique³ consists of edge to edge suture in the anterior and posterior edges and zeta-plasty in the lower lobe. Apesos and Kane⁴ advocate detaching by 1 mm the skin edges to be sutured, which helps prevent scarring reversal.

Tromovitch *et al.*⁵ (Figure 3) described the zeta-plasty performed in total lobe thickness in its anteroposterior direction. We can also choose the zeta-plasty performed only in the anterior lobe with the posterior portion being sutured with direct closure, a technique described by Reiter and Alford.²

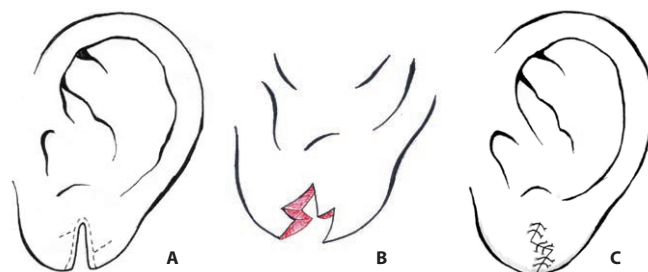


Figure 3 – Earlobe repair with total cleft with anteroposterior zeta-plasty - (A) Defect and lines of incision; (B) Incision with raw area; (C) Final aspect.

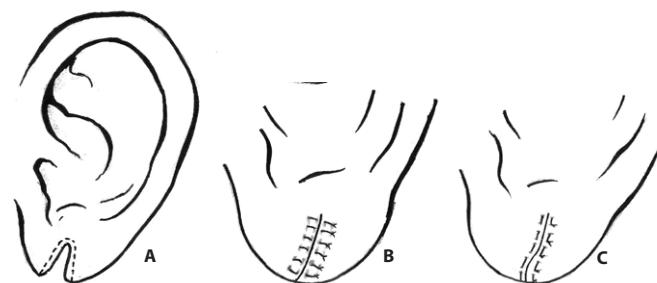


Figure 2 – Earlobe repair with total cleft without preserving the orifice - (A) Defect and lines of incision; (B) Simple stitches; (C) “U” stitches.

Fatah⁶ created an “L” in the anteroposterior direction, i.e., in the total thickness of the lobe, breaking the suture line and creating a dent support for the suture. This “L” can be done on medium-lateral direction, also creating a dent in this direction and was described by Harahap.⁷ Kalimuthu *et al.*⁸ perform a raw “V” at the end of the lobe, followed by de-epidermization of the medial edge and another “V” at the end of the lateral edge, so that both edges fit perfectly at the end of the suture.

There are still other creative technique options described to repair the lobe without preserving the orifice. In Arora's technique,⁹ the cleft is repaired, and the lobe thickness becomes larger. Two triangular areas are de-epidermized to correct the cleft, one anterior at the lateral edge and the other posterior at the medial edge. They are sutured overlapping one another, resulting in increased thickness of the lobe. Effendi's technique¹⁰ proposes a flap rotation of the cleft medial part over the lateral part; in order to extend the de-epidermized lateral edge in the lateral direction, where the medial edge will be sutured.

Earlobe repair with total cleft preserving the orifice

There are also several techniques to preserve the earring orifice. Earrings previously sterilized, or nylon 1.0 or 2.0, is used to maintain the new orifice.

Boo-Chai's technique¹¹ is the simplest, only the inferior part of the orifice and the cleft walls are de-epidermized and then sutured side by side, thus maintaining the earring orifice. In Buchan's technique,¹² the skin of the cleft is completely excised. A flap along the cleft is made at the posterior side of the lobe, which crosses the cleft raw angle serving as a floor to form a new channel for the earring. The wound is closed with simple stitches on both anterior and posterior sides of the lobe.

In Argamaso¹³ and Zoltie¹⁴ techniques, the orifice epithelium is preserved, and anterior and posterior flaps are made, which are sutured with overlapping. The difference is that in Argamaso's technique the flaps are triangular, and in Zoltie's technique they are rectangular.

In Elsayh's technique,¹⁵ two flaps bordering both sides of the cleft along its entire length are made, preserving the epidermis of the orifice. The two flaps are tied in the proximal part, forming the new orifice, and the distal part of both flaps is removed and discarded. Final closure is done with simple suture.

In Pardue's technique¹⁶ (Figure 4), the cleft edges are excised, and the skin of the upper portion of the orifice at one of the sides is preserved. A flap is created with that portion, which is rotated like a snail towards the opposite side and then sutured with nylon, with internal stitches through the dermis of its lower end at the prior orifice raw corner, forming a new orifice. The edges are closed with simple sutures from the anterior lobe to the posterior.

In the techniques of Walik and Larrabee¹⁷ and Hamilton and La Rossa,¹⁸ the flap rotation to form a new orifice is the same as in Pardue's technique,¹⁶ however, in closing the gap, a Z-plasty at the lower end of the lobe is performed. Fayman's technique¹⁹ uses Pardue's flap, and the cleft closure is made with Z-plasty involving the entire length of both sides of the cleft. The Fatah's technique,⁶ flaps in L, previously described can be combined with Pardue's technique¹⁶ to form a new orifice giving greater support to the final result.

Proposed new technique

The authors have performed the technique called modified Pardue's technique with good results both in aesthetics and in support of the new orifice, and without recurrence (Figure 5).

We performed the flap in the same way, but the inner part of the prior earring cleft and the posterior part of the flap are de-epidermized preserving only the skin of the anterior portion of the flap. When sutured through the dermis of the flap extremity, at the raw angle of the prior orifice, the flap is rotated and twisted at the same time, so that the skin of the prior flap becomes the inner part of the new orifice, thereby forming a tight and more resistant orifice to support the earring (Photos 1 to 6).

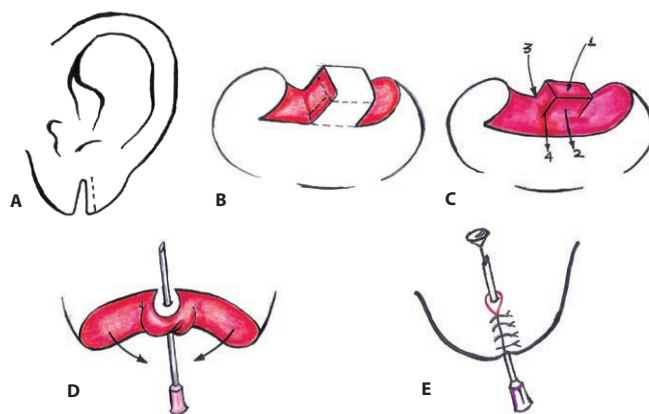


Figure 5 – Modified Pardue's technique - (A) Defect and line of incision; (B) Flap anterior and posterior de-epidermization; (C) Point for flap rotation and twisting; (D) Rotation and twisting final aspect; (E) Earring placement through the needle hole.

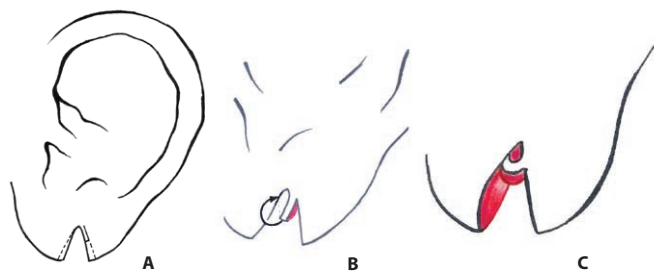
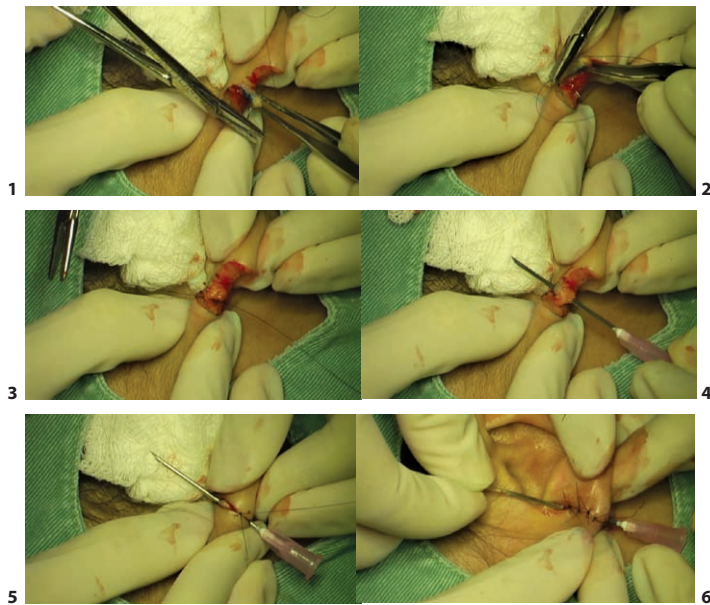


Figure 4 – Pardue's technique - (A) Defect and lines of incision; (B) Flap; (C) Flap suture.



CONCLUSIONS

When choosing the best option for split earlobe repair, we must consider all factors that will influence the final outcome, such as lobe size, cleft type (partial or total), number of orifices already existing, and a tendency to non-aesthetic scars.

Considering the technical possibilities, we chose the technique that will leave the lobe more like the original, with a round not pointed shape, and the orifice centered. It is important to choose the technique most appropriate to each case, allowing the smallest chance of recurrence. The

major techniques that do not preserve the orifice seem to be safer. However, when using the modified Pardue's technique, besides the advantages of maintaining the orifice, there is better chance to support the earring with less chance of recurrence, and satisfactory aesthetic aspect.

REFERENCES

- 1- Tan EC. Punch technique: an alternative approach to the repair of pierced earlobe deformities. *J Dermatol Surg Oncol* 1989;15:270-272.
- 2- Reiter D, Alford EL. Torn earlobe: a new approach to management with a review of 68 cases. *Ann Otol Rhinol Laryngol* 1994;103:879-884.
- 3- Casson P. How do you repair a split earlobe? *J Dermatol Surg* 1976;2:21.
- 4- Apesos J, Kane M. Treatment of traumatic earlobe clefts. *Aesthetic Plast Surg* 1993;17:253-255.
- 5- Tromovitch TA, Stegman SJ, Glogau RG. Flaps and grafts in dermatologic surgery. St Louis: Mosby, 1989.
- 6- Fatah MF. L-plasty technique in the repair of split earlobe. *Br J Plast Surg* 1985;38:410-414.
- 7- Harahap M. Repair of split earlobes. A review and a new technique. *Plast Reconstr Surg* 1984;74:299-300.
- 8- Kalimuthu R, Larson BJ, Lewis N. Earlobe repair: a new technique. *J Dermatol Surg Oncol* 1982;8:187-191.
- 9- Arora PK. Reconstruction of the middle-aged torn earlobe: a new method. *Br J Plast Surg* 1989;42:118.
- 10- Effendi SH. Reconstruction of the middle-aged torn earlobe: a new method. *Br J Plast Surg* 1988;41:174-176.
- 11- Boo-Chai K. The cleft ear lobe. *Plast Reconstr Surg* 1961;28:681-688.
- 12- Buchan NG. The cleft ear lobe: a method of repair with preservation of the earring canal. *Br J Plast Surg* 1975;28:296-298.
- 13- Argamaso RV. The cleft ear lobe: a method of repair with preservation of the cleft earlobe. *Br J Plast Surg* 1978;31:337-338.
- 14- Zoltie N. Split earlobes: a method of repair preserving the lobe. *Plast Reconstr Surg* 1987;80:619-621.
- 15- Elsayh NI. Reconstruction of the cleft earlobe with preservation of the perforation for an earring. *Plast Reconstr Surg* 1986;77:322-324.
- 16- Pardue AM. Repair of torn earlobe with preservation of the perforation for an earring. *Plast Reconstr Surg* 1973;51:472-473.
- 17- Walike J, Larrabee WF Jr. Repair of the cleft ear lobe. *Laryngoscope* 1985;95:876-877.
- 18- Hamilton R, LaRossa D. Method for repair of cleft earlobes. *Plast Reconstr Surg* 1975;55:99-101.
- 19- Fayman MS. Split earlobe repair. *Br J Plast Surg* 1994;47:293.