

Original Article

Chemabrasion for the treatment of perioral wrinkles: clinical analysis and epidermal Langerhans cells qualification

Authors:

Ana Paula Gomes Meski, MD¹
Luiz Carlos Cucé, MD² PhD

¹Dermatologist, Hospital das Clínicas, Faculdade de Medicina da Universidade de São Paulo
²Dermatologist, Hospital do Servidor Público Municipal de São Paulo

Correspondence to:

Ana Paula Gomes Meski
Rua Canário, 1112/181
São Paulo, SP Brasil
CEP: 04521-004
Phone: 55 (11) 5531-2423
E-mail: anapaula@dermatologiaintegrada.com.br

ABSTRACT

Introduction: Skin photoaging can be treated with ablative therapies that may cause immunological changes to the skin. **Objective:** To evaluate the results of chemabrasion in the treatment of perioral wrinkles and the change in number of Langerhans cells. **Material e methods:** Application of 35% trichloroacetic acid followed by manual dermabrasion using waterproof sandpaper in 12 female patients with perioral wrinkles. The patients were evaluated 30 days and 1 year after surgery. Immunohistochemistry was used to measure Langerhans cells, which were counted before treatment and 1 month post-treatment. **Results:** Improved perioral photoaging and reduced number of Langerhans' cells ($p = 0.002$) were seen in all patients. **Conclusion:** Chemabrasion provides effective results in the treatment of perioral wrinkles but Langerhans cells remain low for 30 days after therapy.

Keywords: skin photoaging, chemabrasion, methods, dermabrasion, methods, trichloroacetic acid, therapeutic use, immunohistochemistry, methods, Langerhans cells.

INTRODUCTION

Several techniques used to improve the skin photoaging promote ablation of the epidermis and/or the dermis, among them the chemical peels, dermabrasion and ablative lasers.

The mechanical abrasion, described in the literature by the term dermabrasion, is one of the oldest techniques.^{1,2} Realized with steel diamond sandpaper coupled with high-speed engines, it presents several risks such as: accidental trauma in the eyes and lips, spreading particles of contaminants to the medical team,³ hypochromia,⁴ and scars.

The same procedure performed manually with water sandpapers presents itself as a safer technique, because the physician has absolute control of the intensity of abrasion and the level of depth, without reaching unwanted areas or disseminating contaminant particles. It was considered by some authors as the treatment of choice for perioral⁵ wrinkles by allowing gradual abrasion, deeper on wrinkles and superficial on the periphery of the treated area, avoiding lines of demarcation. In 1996, Chiarello reported good results in the treatment of perioral wrinkles using initially more rough water sandpapers followed by finer ones.⁶

Ablative techniques can be combined to obtain better results with less risk. In 2006, the laser abrasion was described, which consists in the combination of CO₂ laser and dermabrasion for the treatment of deep perioral wrinkles with improvement of 95%.⁷

The association of dermabrasion with chemical exfoliation was proposed by Dupont and colleagues in 1972,⁸ and it was named chemabrasion in 1977 by Stagnone.⁹ Both authors used 88% phenol before dermabrasion with diamond sandpaper. In 1994, the technique of manual dermabrasion with water sandpaper was described followed by the application of trichloroacetic acid (TCA) 25% for treatment of facial photoaging.¹⁰ The implementation of TCA 35% before manual dermabrasion was reported for treating non-distensible acne scars,¹¹ and this is the first study that demonstrates this technique for the treatment of perioral wrinkles.

(We declare no conflict of interest).

Perioral wrinkles are dynamic wrinkles resulting from mastication and speech, and in more advanced age they are transformed into static wrinkles¹². In 1998, Baker classified them into three types, based on their number, location and depth. Type I perioral wrinkles are superficial and affect 1/3 to 1/2 of the upper lip in number less than or equal to 8, type II are moderate and present in more than 2/3 of the upper lip, varying in number from 9-15, while type III lines are profound and affect the upper and lower lips in more than 16.¹³ The treatments that give the best results for these wrinkles are ablative procedures.

Herpes simplex virus reactivation is common after these procedures. The infection usually occurs in the first week of the postoperative period, according to the report of the first case in 1940.¹⁴ Recent studies report a reduced number and altered function of the Langerhans cells in the epidermis, with the occurrence of a symptomatic disease after the reactivation of the virus.^{15,16} The ablative methods completely remove the epidermis and, consequently, they also remove the Langerhans cells.

The objectives of this study were to evaluate the clinical results of chemabrasion performed with TCA 35% followed by mechanical abrasion with water sandpaper in perioral photoaged skin and to quantify Langerhans cells in the postoperative period.

MATERIAL AND METHODS

A prospective, open, uncontrolled study was approved by the ethics committee of the Hospital das Clínicas, Faculdade de Medicina, Universidade de São Paulo. After information and consent, chemabrasion was performed in 12 female patients, aged between 45 and 80 years, phototypes I and III according to Fitzpatrick classification, presenting with perioral wrinkles types II and III, according to the classification proposed by Baker.¹³ Patients with a history of herpes simplex infection, altered healing process, use of keratolytic substances in the treatment area or systemic isotretinoin in the previous 12 months, and those who were unable to realize adequate photoprotection for at least 60 days after surgery were excluded. A series of standardized photographs were performed with the same camera used for all the patients, the same lighting and focal distance, before chemabrasion and after 30 days and 12 months.

Technique: After antisepsis of the face, anesthesia of infraorbital and mentonian bilateral nerves with 2% lidocaine and epinephrine 1:100,000 was performed. The application of TCA 35% was realized with cotton until Rubin¹⁷ white solid level 3 was achieved across the perioral region, covering nasogenian grooves, 3 mm from the outer edge of the vermilion of the lips, and the lower edge. Water

sandpaper numbers 180, 220 and 400 were used in this order, i.e. from the more rough to the most delicate. The sheets of paper were cut into pieces of 4 x 5 cm and autoclaved. To increase the flexibility and the abrasive power, the sandpapers were soaked in 0.9% sterile saline and, for ease of handling, they were firmly attached around the body of a 3-mL sterile syringe.

The skin was stretched during the sanding process, and the procedure was realized with uniform pressure, in horizontal and circular movements. Sandpaper number 180 was the first one used in order to remove surface skin bleached by TCA until the bleeding began, indicating the plane of the papillary dermis. Sanding was deeper on the wrinkles. Sandpaper number 220 was used until the appearance of confluent points of bleeding, indicating that the upper reticular dermis was reached. Sandpaper number 400 was used to the final phase of dermabrasion. The dressing was made with gentamicin sulphate 1 mg/g ointment and sterile gauze, and it was removed the next day. Application of the ointment was kept for 10 days, three times daily (Figure 1).

The evaluation was done by clinical examination, picture comparison and change in the type of wrinkles, according to the Baker classification, 30 days and 12 months after the procedure. The quantification of Langerhans cells by immunohistochemical test was realized, and 2 biopsies in the upper lip and in the inferior-lateral portion of the right nostril were collected with 4 mm punches, ten days before chemabrasion, and 30 days after at the contralateral symmetrical region, both in photoexposed areas.

The material was frozen, submitted to cryomicrotomy, fixed in acetone, incubated with primary antibody and processed by the avidin-biotin modified method.¹⁸ The mouse monoclonal antibody used in the study was the anti-CD1a for Langerhans cells (Dako M721, 1:100). The reaction was developed with diaminobenzidine (Sigma Chemical) and counterstained hematoxylin.

The readings of the immunohistochemical examinations were performed in optical microscopes, with a 40X objective and graticule coupled to a 10X ocular, with an increase in microscopic fields of 400X. The graticule area in this increase corresponds to 0.0625 mm². For each fragment the areas of five fields were analyzed, and the average number of immunomarked cells per unit area (mm²) was obtained. The epidermal Langerhans cells are characterized by the epidermal fraction area with positivity for CD1a.

The statistical analysis was performed by the Wilcoxon nonparametric test in order to compare the number of cells. A significance level of 0.05 ($\alpha = 5\%$) was used. Descriptive levels (P) lower than this value were considered significant and represented by *.

RESULTS

Clinical outcome: In the day following the surgery, there was intense yellowish exudate which gradually disappeared between the 7th and 10th days, when reepithelialization was complete in all patients. They reported mild pain without the use of analgesics. The skin showed erythema and edema for two to three weeks after the procedure, and transient hypochromia was observed in the region treated, lasting up to 30 days in all cases.

There was erythema, exudate, crusting, pustules and painful erosions in 3 (25%) patients on the fifth day postoperatively, as well as herpes simplex infection, which was treated with oral acyclovir (2 g/day) for 10 days. The improvement was noticeable from the second day of treatment with resolution on the tenth day. It did not result in healing sequelae. The treatment of maintenance was based on the continuous and exclusive use of sunscreen.

Thirty days after treatment, all patients showed improvement of the aged perioral region at clinical examination, and in four of them a better definition of the lip contour was noticed. The deeper wrinkles and furrows caused by the flaccidity of the skin did not improve.

After 12 months the results were maintained in all patients and the improvement of the general appearance of the skin was more evident, especially a larger rejuvenation of the perioral region when compared to the rest of the face (Figure 2). According to the classification proposed by Baker, the analysis of perioral wrinkles made 30 days after the procedure showed that among the four patients initially with wrinkle type II two improved, changing their classification to type I, and two remained as type II, despite the improvement in skin texture and clinical appearance. Among the eight patients with deeper perioral wrinkles (type III), four had their classification altered to type II, and four remained as type III (Table 1).

IMMUNO-HISTOCHEMICAL ANALYSIS

Comparing the findings before and after chemabrasion, there was statistically significant decrease in the number of Langerhans cells in the epidermis ($p = 0.002$) (Figure 3) (Tables 2 and 3)

DISCUSSION

In this study, the TCA 35% was applied before manual dermabrasion with water sandpaper, since queratocoagulation caused by the acid makes the skin friable and defines the depth to be achieved, facilitating the dermasanding. The procedure also becomes more predictable with its use, eliminating variables that are interfering with the depth of dermabrasion, such as the skin thickness.¹⁹

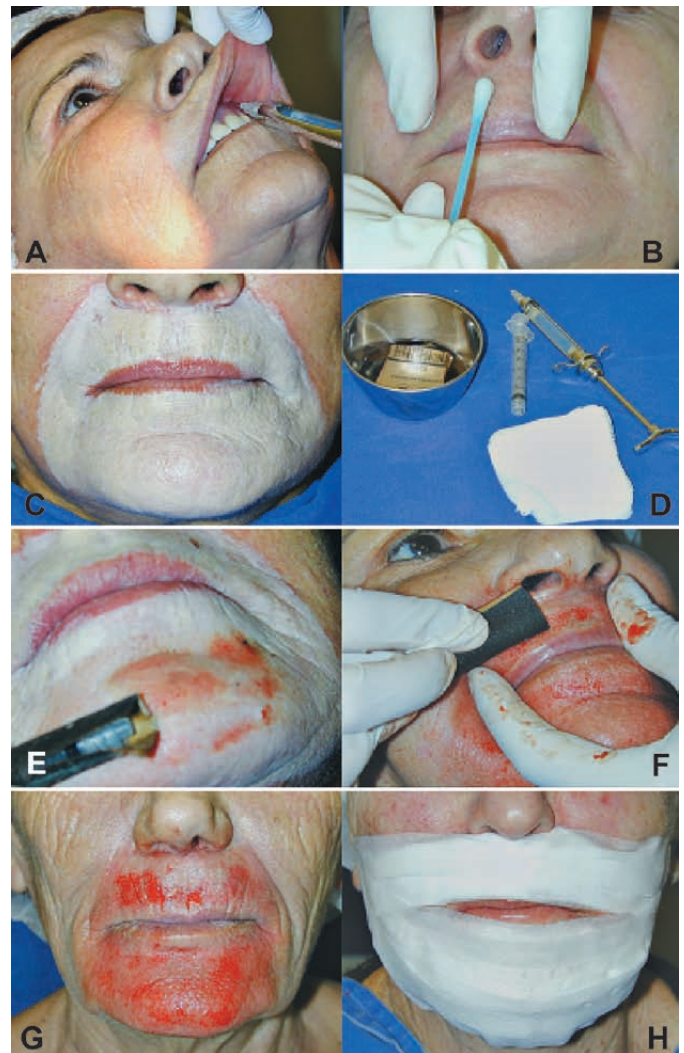

Figure 1. Chemabrasion technique for perioral wrinkles. A) Anesthesia; B) Application of TCA 35%; C) White solid level 3; D) Material; E) and F) Dermabrasion with sandpaper number 220; G) Final phase of dermabrasion; H) Dressing.

The chemabrasion technique most often described in the literature associates phenol 88% with motor dermabrasion.²⁰ The advantage of using phenol is immediate anesthetic effect after its application to the skin but its use increases the risk of permanent hypochromia, due to the destruction that this drug can cause in melanocytes.²¹ Some authors use the freezing of the skin to facilitate dermasanding, which can damage melanocytes, causing hypopigmentation.²² Hypochromia occurred in all patients in our study, with average duration of 15 days after chemabrasion for removal of melanocytes by sanding. The clinical analysis of patients showed no subsequent change of skin pigmentation, showing that this technique is safe.

The photoaging signs improvement of the perioral region was observed in all patients. Among those with no change in the

number of wrinkles and in the Baker classification, 13 patients showed improvement of skin texture and color. After one year monitoring, the improvement of photoaging was more evident, even if topical treatments other than sunscreens were not used, suggesting a delayed response of the skin to the ablative process.

The most important complication was the high rate of infection with herpes simplex (25%), which may have been influenced by the absence of prophylaxis with oral acyclovir, not used in this study due to the inclusion of only patients with no previous history of disease.

There is controversy in the literature about the prophylaxis recommendation. In 2001 Harmon suggested that prophylaxis for herpetic infection after dermabrasion lasted 10-14 days.²³ In 1996 Perkins and Sklarew published a study with 181 patients undergoing dermabrasion or chemical exfoliation of the perioral region, and they found that patients with no history of herpetic infection who did not receive acyclovir orally showed a 50% rate of infection after the procedure.^{24,25} In such cases, treatment of infection should be promptly initiated to prevent local spread, secondary bacterial infection, delayed healing, scarring, and pigmentary changes.

The herpes simplex virus activation is a common complication of cutaneous ablative techniques, showing that during these procedures the skin undergoes immunological changes. It is believed that the reduction in the number of Langerhans cells is one of the major factors that contribute to the installation of these infections, due to their role in immune surveillance.²⁶

Even mild trauma to the skin with adhesive tape leads to migration of Langerhans cells from the epidermis to the lymphatic vessels in four days and their return to normal counting after 15 days.²⁷ There is no provision of an exact time for the reappearance of these cells in the epidermis, but it is believed that it is lower when the trauma does not result in its total elimination, because the remaining cells undergo division and produce new ones.²⁸ The chemabrasion remove all skin, so a slower occurrence of Langerhans cells is expected, depending solely on the migration of cells from the bone marrow. This study showed that its occurrence is independent from the skin complete healing and it does not occur after 30 days. Further research is necessary to know the period in which the normalization of the number of Langerhans cells occurs after the use of techniques that result in total ablation of the epidermis.

The recommendation that patients do not expose themselves to the sun and use sunscreens after ablative treatments is essential to avoid further reduction in the number of Langerhans cells, as the ultraviolet radiation is another cause of their reduction in the epidermis with the apoptosis stimulus.²⁹ Topical tretinoin should be recommended during this period. It speeds up the healing process,³⁰ reduces the risk of post-inflammatory hyperpigmentation³¹ and

Chart 1 – Classification of perioral wrinkles from 12 patients before, 30 days and 1 year after chemabrasion according to the Baker criteria.

Patient	Before	After 30 days	After 12 months
1	III	III	III
2	II	I	I
3	III	II	II
4	III	III	III
5	III	III	III
6	II	I	I
7	II	II	II
8	II	II	II
9	III	II	II
10	III	III	III
11	III	II	II
12	III	II	II

Chart 2 – Quantification of Langerhans cells in the epidermis (number of CD1a cells per/mm²) from patients before and 30 days after the chemabrasion for treatment of perioral wrinkles. Patient

Patient	CD1a before	CD1a after
1	144	16
2	208	32
3	288	144
4	96	16
5	48	0
6	272	48
7	160	80
8	192	176
9	368	112
10	32	16
11	336	16
12	144	16

Chart 3 – Number of CD1a positive cells /mm² in the epidermis of patients with perioral wrinkles before and 30 days after chemabrasion.

	Before	30 days
	CD1a	CD1a
	n = 12	n = 12
Media	190,6	56
Minimum	32	0
Maximum	368	176

n = number of biopsies (Wilcoxon signed-rank test; p* = 0.002)

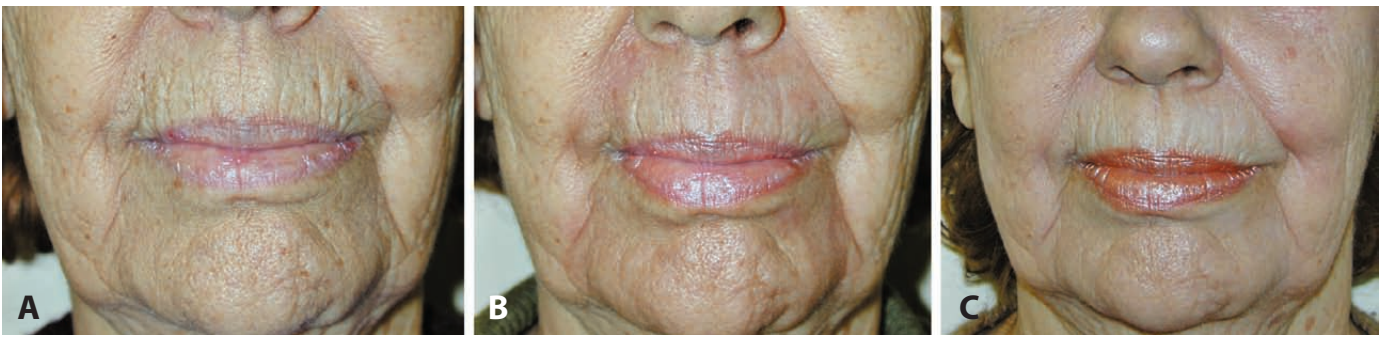

Figure 2. Patient who was submitted to chemabrasion of perioral wrinkles. A) Before; B) After 30 days; C) After 12 months

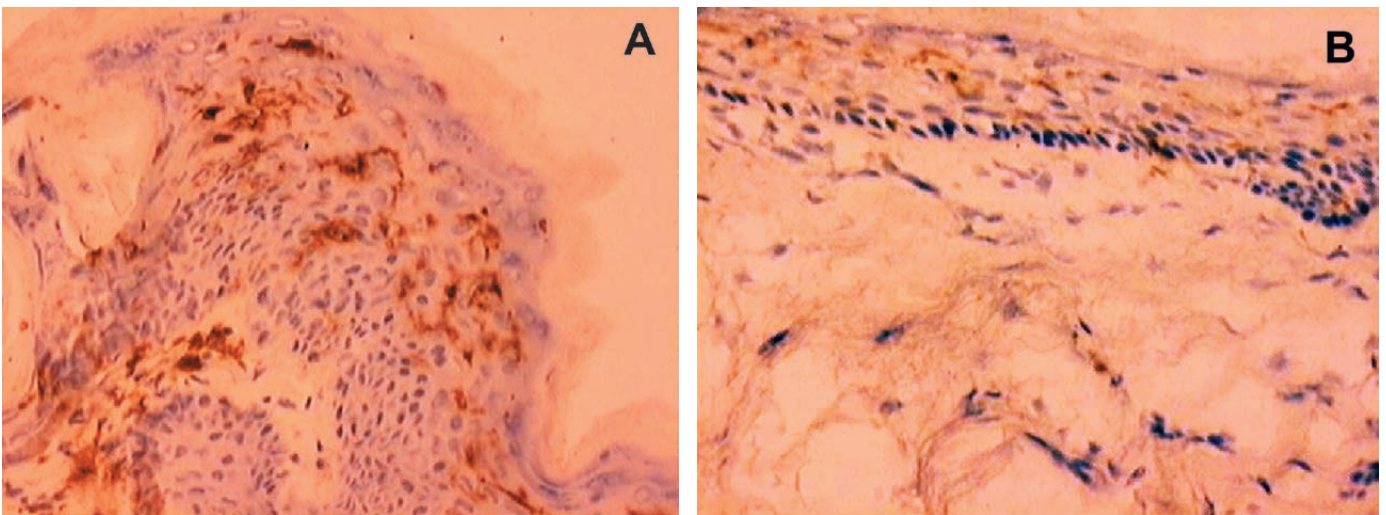


Figure 3. Epidermal Langerhans cells in perioral region revealed by CD1a antibody. A) Before chemabrasion; B) 30 days after the chemabrasion there was a decrease in the number of Langerhans cells. Imuno-histochemical Technique.

increases the number of Langerhans cells in the epidermis if used at 0.025%.³²

CONCLUSIONS

It was concluded that:

1 – Chemabrasion, involving 35% and TCA manual water sandpaper dermabrasion, is an effective and safe procedure for the treatment of the perioral region aging, with results maintained or improved after one year.

2 – Thirty days after the procedure, there is significant reduction in the number of Langerhans cells in the epidermis. Thus, the decrease in the skin immune defense system occurs not only in the first days after chemabrasion (a higher incidence of herpes infection stage), but it persists for at least up to a month, although the complete reepithelialization occurs within 10 days [s&ct](#).

REFERENCES

1. Epstein E. Planning for precancerous skin. A ten-year evaluation. *Calif Med* 1966;105(1):26-7.
2. Orentreich N. Dermabrasion. *J Am Med Womens Assoc* 1969;24:331-6.
3. Wentzell JM, Robinson JK, Wentzell JM Jr, et al. Physical properties of aerosols produced by dermabrasion. *Arch Dermatol* 1989;125:1637-43.
4. Stuzin JM, Baker TJ, Baker TM. A controlled evaluation of dermabrasion versus CO₂ laser resurfacing for the treatment of perioral wrinkles. (Discussion). *Plast Reconstr Surg* 2000;106(6):1373-4.
5. Perkins SV. Proven modalities for facial skin resurfacing? *Arch Otolaryngol Head Neck Surg* 2004;130:1334-5.
6. Chiarello SE. Tumescing dermasanding with cryospraying. A new wrinkle on the treatment of rhytids. *Dermatol Surg* 1996;22:601-10.
7. Fezza JP. Laserabrasion: the combination of carbon dioxide laser and dermasanding. *Plast Reconstr Surg* 2006;118:1217-21; discussion 1222-3.
8. Dupont C, Ciaburro H, Prevost Y, et al. Phenol skin tightening for better dermabrasion. *Plast Reconstr Surg* 1972;50:588-90.
9. Stagnone JJ. Chemabrasion, a combined technique of chemical-peeling and dermabrasion. *J Dermatol Surg Oncol* 1977;3:217-9.
10. Harris DR, Noodleman FR. Combining manual dermasanding with low strength trichloroacetic acid to improve actinically injured skin. *J Dermatol Surg Oncol* 1994;20:436-42.
11. Kadunc BV, Trindade de Almeida AR. Surgical treatment of facial acne scars based on morphologic classification: a Brazilian experience. *Dermatol Surg* 2003;29:1200-9.

12. Perkins SW, Sandel HD. Anatomic considerations, analysis, and the aging process of the perioral region. *Facial Plast Surg Clin North Am* 2007;15:403-407.
13. Baker TM. Dermabrasion. As a complement to aesthetic surgery. *Clin Plast Surg* 1998;25:81-8.
14. Findlay GM, MacCallum FO. Recurrent traumatic herpes. *Lancet* 1940;1:259.
15. Sprecher E, Becker Y. Herpes simplex virus type 1 pathogenicity in footpad and ear skin of mice depends on Langerhans cell density mouse genetics and virus strain. *J Virol* 1987;61:2515-22.
16. Manickasingham SP, Hill TJ, Williams NA. Modulation of Langerhans cell phenotype, migration and maturation by agents known to cause herpes simplex virus reactivation in a mouse model. *Clin Exp Immunol* 1996;106(2):304-311.
17. Rubin MG. Trichloroacetic acid peels. In: *Manual of chemical peels*. Philadelphia: Lippincott Williams & Wilkins; 1995. p. 110-129.
18. Hsu SM, Raine L, Fanger H. Use of avidin-biotin-peroxidase complex (ABC) in immunoperoxidase techniques: a comparison between ABC and unlabeled antibody (PAP) procedures. *J Histochem Cytochem* 1981;29:577-80.
19. Gin I, Chew J, Rau K, et al. Treatment of upper lip wrinkles: a comparison of the 950 microsec dwell time carbon dioxide laser to manual tumescent dermabrasion. *Dermatol Surg* 1999;25:468-73; discussion 473-4.
20. Fulton JE Jr. Dermabrasion, chemabrasion, and laserabrasion. Historical perspectives, modern dermabrasion techniques, and future trends. *Dermatol Surg* 1996;22:619-28.
21. Ruiz-Maldonado R. Saturated phenol as a local anesthetic for manual dermabrasion. *Dermatol Surg* 1997;23:187-89; discussion 190.
22. Hanke CW, Pinskl JB, Roenigk HH Jr, Alt TH. Caution--new skin refrigerants. *J Dermatol Surg Oncol* 1984;10:167.
23. Harmon CB. Dermabrasion. *Dermatol Clin* 2001;19:439-442.
24. Drake LA, Ceilley RI, Cornelison RL, Dobes VWL, et al. Guidelines of care for dermabrasion. *J Am Acad Dermatol* 1994;31:654-7.
25. Perkins SW, Sklarew EC. Prevention of facial herpetic infections after chemical peel and dermabrasion: new treatment strategies in the prophylaxis of patients undergoing procedures of the perioral area. *Plast Reconstr Surg* 1996;98:427-33; discussion 434-5.
26. Pollara G, Katz R, Benjamin M. The host response to herpes simplex virus infection. *Curr Opin Infect Dis* 2004;17(3):199-203.
27. Holzmann S, Koch F, Stroitzner P, et al. Tape stripping leads to emigration of Langerhans cells from the epidermis, their entry into afferent lymphatics *in vivo*, and allows immigration of progenitors. *J Invest Dermatol* 2000;114(1):228.
28. Miyauchi S, Hashimoto K. Epidermal Langerhans cells undergo mitosis during the early recovery phase after ultraviolet-B irradiation. *J Invest Dermatol* 1987;88:703-8.
29. Kolgen W, Both H, van Weelden H, et al. Epidermal langerhans cell depletion after artificial ultraviolet B irradiation of human skin *in vivo*: apoptosis versus migration. *J Invest Dermatol* 2002;118:812-7.
30. Mandy SH. Tretinoin in the preoperative and postoperative management of dermabrasion. *J Am Acad Dermatol* 1986;15:878-9, 888-9.
31. Weinstein C. Carbon dioxide laser resurfacing. Long-term follow-up in 2123 patients. *Clin Plast Surg* 1998;25:109-30.
32. Murphy GF, Katz S, Kligman AM. Topical tretinoin replenishes CD1a-positive epidermal Langerhans cells in chronically photodamaged human skin. *J Cutan Pathol* 1998;25:30-4.6