

## Original Article

# Subungueal glomus tumors treated by the mohs micrographic surgery: recurrence index and literature review

### Authors:

Selma S. Cernea<sup>1</sup>  
Nilton Di Chiacchio<sup>2</sup>  
Adriana Vanti<sup>3</sup>

<sup>1</sup> MD in Dermatology  
<sup>2</sup> MD in Dermatology – FMUSP  
<sup>3</sup> MD in Dermatology – FMUSP

### Correspondence to:

Selma S. Cernea  
Alameda Franca, 267/conjunto 21  
CEP: 014.22-000  
E-mail: selma\_cernea@uol.com.br

### ABSTRACT

**Introduction:** The subungueal glomus tumor is characterized by painful nodules triggered by thermal and tactile change. A complete lesion excision is the treatment of choice but relapses are frequent. **Objective:** To compare the rates of recurrence of conventional surgeries described in the literature with the ones we found after the Mohs micrographic surgery (MMS). **Material and methods:** Ten patients diagnosed with subungueal glomus tumor were included; nine female and one male. Was realized excision of these lesions by the technique of Mohs micrographic surgery in two patients. **Results:** Of the ten patients, eight were considered cured after follow up of 14 to 93 months (average of 47.8 months). There were two recurrences which occurred after 47 and 51 months. One case was reoperated by MMS and there was no evidence of disease after 24 months. **Conclusion:** The results obtained with the use of MMS in subungueal glomus tumors were similar to those reported in the literature with conventional techniques, usually with a shorter period of follow up.

### INTRODUCTION

The glomus tumor is a benign neoplasm of glomus cells of uncommon occurrence representing 1 to 4.5% of hand tumors.<sup>1</sup> It shows intermittent severe pain that can be triggered by trauma or by changes in temperature. Clinically, it appears as a small subcutaneous nodule, firm in consistency, pink or blue colored, and with sizes ranging from 0.3 to 2 mm, with reports of tumors up to 8 mm.<sup>2,3,4,5,6</sup> Ungueal deformities are rare.<sup>4</sup>

Its distribution is often in the third and fifth decades of life, and the history of trauma or repeated microtraumas is common. It is more prevalent in women and rare during childhood. There are reports of familial cases, with dominant autosomal inheritance.<sup>7</sup>

The clinical diagnosis is made by the presence of the symptom triad: pain, change in tactile sensitivity, and sensitivity to cold.<sup>8</sup>

The histologic characteristics of these tumors include the presence of neuromioarterial structure,<sup>6</sup> with branched vascular channels separated by conjunctive stroma, containing nests of specialized glomus cells, probably derived from pericytes, which are isolated pericapillaries cells distributed along the capillaries. The cells present regular size with marked membranes and small cytoplasm.<sup>9,10,11</sup>

In simple radiography, the presence of bone erosion may suggest the diagnosis; however this is a rare finding that, according to some authors, is only present in 22% of patients.<sup>8</sup> High-resolution magnetic resonance imaging is considered the best test at present because it allows the complete delineation of the lesion<sup>12</sup> in most cases.

The main differential diagnoses are: neuromas, hemangiopericytoma, leiomyomas, and espiroadenoma eccrine.<sup>13</sup>

The treatment of choice for glomus tumor is complete surgical excision, which results in immediate relief of symptoms. The tumor surgical access may be by transungueal or lateral, depending on its localization.<sup>5</sup>

The recurrence rates with conventional surgery are considered high and may vary from 5 to 35%.<sup>7,8,14,15</sup>

(We declare no conflict of interest).

Mohs micrographic surgery (MMS) is a technique for skin tumor removal that, provides a more complete histologic evaluation, through a survey of surgical margins. A total resection of the tumor is obtained with better rates of cure, also allowing greater preservation of normal tissue. This technique has been used with encouraging results for the excision of ungual neoplasms such as squamous cell carcinoma, with level of cure of about 96%. Its great advantage is oncologic safety, maintaining the preservation of adjacent normal tissue, with obvious aesthetic and functional benefit.

The objective was to apply this technique for the removal of glomus tumors and to compare with the rates of recurrence of conventional surgery which are reported in the literature, since there are no published series in the literature supporting its use in these tumors.

## MATERIAL AND METHODS

In this prospective study, ten patients with a diagnosis of subungual glomus tumor were submitted to MMS from June 2001 to December 2005 at the Dermatologic Surgery Department of the Hospital do Servidor Público Municipal de São Paulo. Nine patients were female, and one was male, with ages ranging from 38 to 59 years. In eight patients the lesions were located on fingers and two on toes. In one patient the tumor recurred and MMS was repeated, totaling 11 surgical procedures.

Clinical diagnosis was based on the triad of pain, change in tactile sensitivity, and sensitivity to cold in all cases. Five patients underwent magnetic resonance imaging. One had a simple radiography showing bone erosion, and in all cases the diagnosis was confirmed by histologic examination after surgery.

Surgeries were performed with blockade of the distal finger realized with 2% lidocaine without vasoconstrictor, followed by proximal tourniquet. After the total removal of the nail plate, the lesions were excised in block including the nail bed

and the tumor until the bone level. The entire lateral margin in a ring shape of about 2 to 3 mm thick was excised. This layer, after careful identification and mapping, was submitted for examination in freezing cryostat and staining of slides with hematoxylin-eosin, examined by optical microscope at 100 and 400x. During this process, the garrote was removed. If persistence of the tumor was confirmed, the garrote was used again and new slices were analyzed until its complete eradication. The healing occurred by second intention after this step completed (Figure 1).

Patients were instructed to return every week until complete healing of the surgical wound. Subsequently, they were reviewed every six months for two years and then annually. The parameter used to cure was the absence of the classic symptoms.

## RESULTS

Nine (90%) of the ten patients undergoing MMS were female and one (10%) male, with the average age of 48.5 years. Three patients were in the fourth decade (30%), four in the fifth (40%), and three in the sixth decade of life (30%). Fingers were more affected (80%) compared with toes (20%). Among the eleven lesions operated, two were excised in a single stage (18.2%), six needed two stages (54.5%), one needed three stages (18.2%), and one, four stages (9.0%).

The follow-up ranged from 14 to 93 months with an average of 47.8 months. There were two recurrences that occurred after 47 and 51 months, respectively; one of them was submitted to the MMS and remained without signs of recurrence after 27 months. A third patient had persistent pain and underwent new surgery, in which the presence of tumor was not observed (Table 1).

## DISCUSSION

The glomus tumor is an uncommon injury with higher incidence in females, usually in the subungual location. In

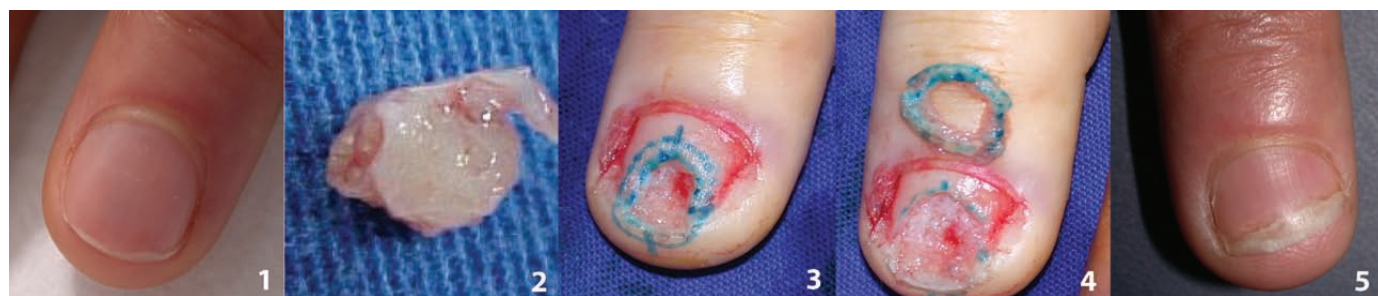

Figure 1. 1) Before surgery; 2) Surgical piece; 3) Margin establishment; 4) Margin submitted to freezing; 5) Final result.

Table 1. Table of Patients

Patient	Age/Gender	Position	Exam	Fase/fragments	Follow-up
1	42/F	Halux D	RX	2/3	(months)
2	38/F	IV QDD		2/3	57
3	39/F	IV QDD	MRI	4/7	69
4	53/M	IV QDD	MRI	2/3	64
5	56/F	V QDD	MRI	2/3	24
Idem	Idem			3/3	51
6	37/F	Halux D	CT	2/3	27
7	48/F	IV QDE		1/3	93
8	59/F	I QDE	MRI	1/3	61
9	46/F	IV QDD	MRI	2/8	28
10	44/F	IQDE	MRI	3/5	39

MRI - magnetic resonance imaging; CT - computed tomography

males, these tumors appear in other areas of the body.<sup>9</sup> Our casuistic was similar to the literature, and 90% of the patients were females. The age distribution ranged from 38 to 59 years, showing a trend in older patients when compared to the literature.<sup>7</sup>

In a review of 48 glomus tumors removed by the team of Gandon et al., the authors mention that all the removed lesions were encapsulated, which facilitates its clinical definition, allowing a complete withdrawal.<sup>22</sup> In this series

of glomus tumors removed by the MMS, which is the first published in the national and international literature, we found that in 82% (9/11) of surgeries performed there was a need for two or more stages of freezing for the removal of these lesions. This suggests the presence of subclinical extensions of these tumors or the occurrence of rupture of the capsule during surgery. In both situations, the importance of the mapping during the implementation of MMS is highlighted. Another aspect that must be

Table 2. Published articles in the literature

Author	Number of cases	Technique	Follow-up	Recurrence – number of cases and percentage
Gandon <i>et al.</i> 1992	48	Para ungual	4,5 years	2 – 4,2%
Chen <i>et al.</i> 1995	12	NI	4,5 years	0 – 0%
Van Geertruyden <i>et al.</i> 1996	51	Transungual	2 years	2 – 3,9%
Foucher <i>et al.</i> 1999	55	Lateral	6,75 years	7 – 12,8%
Tanaka <i>et al.</i> 2001	30	Transungual	NI	9 – 30%
Assmus e Dombert 2002	36	Transungual	NI	2 – 5,5%
Chen <i>et al.</i> 2003	34	NI	1 a 6 years	5 – 14,7%
Ozdemir <i>et al.</i> 2003	60	Transungual and mediolateral	16 months	9 – 15%
Vasisht <i>et al.</i> 2004	19	Lateral	NI	3 – 15,8%
Moon <i>et al.</i> 2004	16	Transungual	NI	0 – 0%
Maalla <i>et al.</i> 2007	10	NI	14 months	0 – 0%
Li <i>et al.</i> 2008	30	Microsurgery	15 months	0 – 0%


emphasized, and is difficult to measure and to compare with the literature, is the improvement of the aesthetic and functional results that this technique provides, due to the preservation adjacent tissue.

The rates of recurrence found in the literature vary from 0 to 30% with variable follow-up time.<sup>22-33</sup> Only in two studies this parameter was greater than that reported in our cases (54 and 81 months) 25 and 28 (Table 2). In all these reports, the surgical technique used was the transungueal or lateral approach.

The recurrence rate we found (20%) is found within the literature.

Some authors believe that recurrence is classified into early and late. Early recurrences, before an year, are attributed to incomplete excision or another non-tumor diagnosed at the time of this initial withdrawal, while the late one, after an year, are possibly due to the appearance of another tumor, which seems relevant.<sup>20</sup> In this series, we observed two cases of recurrence after 47 and 51 months, among the 10 operated cases (20%). One patient was submitted again to a MMS and remained without recurrence for 24 months. Analysing the time of recurrence of injuries and the literature data, we can consider that it is not a case of recurrence but a possible new tumor.

The oncological, functional and aesthetic results obtained in this series of patients with glomus tumors treated by MMS were encouraging, providing the opportunity to conduct studies including a larger number of cases.

We conclude that our recurrence rate in cases of subungual glomus tumors under Mohs micrographic surgery (20%) is within the range found in previous published works. 

## REFERENCES

1. Du Vivier A. Atlas de Dermatologia Clínica. 2 ed. São Paulo: Manole, 1997, pp. 828-829.
2. Rohrich RJ, Hochstein LM, Millwee RH. Subungueal glomus tumors: an algorithmic approach. *Ann Plast Surg* 1994;3:303-4.
3. Ogino T, Ohnishi N. Ultrasonography of a subungual glomus tumour. *J Hand Surg* 1993;18B:746-7.
4. Parsons ME, Russo G, Fucich L, Millikan LE, Kim R. Multiple glomus tumors. *Int J Dermatol* 1997;36:894-900.
5. Moor EV, Goldberg I, Westreich M. Multiple glomus tumor: a case report and review of the literature. *Ann Plast Surg* 1999;43:436-8.
6. Shih, TTF, Sun JS, Hou SM et al. Magnetic resonance imaging of glomus tumor in the hand. *Int Orth* 1996;20:342-5.
7. Geertruyden JV, Lorea P, Goldschmidt D, Fontaine S, Schuind F, Kinnen L, Ledoux P, Moermans JP. Glomus tumours of the hand. A retrospective study of 51 cases. *J Hand Surg* 1996;21B(2):257-60.
8. Carrol RE, Berman AT. Glomus tumors of the hand. *J Bone Joint Surg* 1972;54 A:691-703.
9. Heys SD, Brittenden PA, Eremin O. Glomus tumour: an analysis of 43 patients and review of the literature. *Br J Surg* 1992;79:345-7.
10. Gould EV, Manivel JC, Alvares-Saavedra J, Monforte H. Locally infiltrative glomus tumors and glomangiosarcomas. A clinical, ultrastructural, and immunohistochemical study. *Cancer* 1990;65(2):310-8.
11. Liapi-Avgeri G, Karabela-Bouropoulou V, Agnanti N. Glomus Tumor. A histological, histochemical and immunohistochemical study of the various types. *Path Res Pract* 1994;190:2-10.
12. Hou S-M, Shih Tt-F, Lin M-C. Magnetic resonance imaging of an obscure glomus tumour in the fingertip. *J Hand Surg [Br]* 1993;18B:482-3.
13. Haupt HM, Stern JB, Berlin SJ. Immunohistochemistry in the differential diagnosis of nodular hidradenoma and glomus tumor. *Am J Dermatopathol* 1992;14(4):310-4.
14. Brenner P, Krause Bergmann A, Witting K. Solitare glomustumoren der hand. Eine klinisch-pathologische Erfrassungsstudie. *Langenbecks Archiv fur Chirurgie* 1995;380: 321-6.
15. Carlstedt T, Lugnegard H. Glomus tumor in the hand. A clinical and morphological study. *Acta Orthop Scand* 1983;54(2):296-302.
16. Mohs FE. Chemosurgery for skin cancer: fixed tissue and fresh tissue techniques. *Arch Dermatol* 1976;112:211-14.
17. Snow SN. Techniques and indications for Mohs micrographic surgery. In Mikhail, G.R. *Mohs Micrographic Surgery*. Philadelphia, W. B. Saunders Company, 1991;11-60.
18. Cernea SS. Experiência do grupo de Cirurgia Micrográfica de Mohs do HCFMUSP dez 1989 a abril 1993 *An Bras Dermatol* 1994;69:365-73.
19. Zaiac M N, Weiss E. Mohs micrographic surgery of the nail unit and Squamous Cell Carcinoma. *Derm Surg* 2001;27:246-51.
20. Dailiana ZH, Drapé JL, Le Viet D. A glomus tumour with four recurrences. *J Hand Surg [Br]* 1999;24B(1):131-2.
21. Varian JPV, Cleak DK. Glomus tumors in the hand. *Hand* 1980;12:293.
22. Gandon J, Legallard Ph, Brueton R, Le Viet D, Foucher G. Forty-eight glomus tumours of the hand Retrospective study and four-year follow-up. *Ann. Hand. Surg* 1992;11:401-5.
23. Van Geertruyden J, Lorea P, Goldschmidt D, de Fontaine S, Schuind F, Kinnen L, et al. Glomus tumours of the hand. A retrospective study of 51 cases. *J Hand Surg [Br]* 1996; 21(2):257-60.
24. Chen WC, Lee TS, Ku MC, Hsu KC. Glomus tumors of the upper extremity: experience with twelve cases. *Zhonghua Yi Xue Za Zhi (Taipei)* 1995;55(2):163-7.
25. Foucher G, Le Viet D, Dailiana Z, Pajardi G. Glomus tumor of the nail area. Apropos of a series of 55 patients. *Rev Chir Orthop Reparatrice Appar Mot* 1999; 85(4):362-6.
26. Takata H, Ikuta Y, Ishida O, Kimori K. Treatment of subungual glomus tumour. *Hand Surg* 2001;6(1):25-7.
27. Assmus H, Dombert T. Glomus tumours of the extremities: localization and operative treatment in 36 cases. *Handchir Mikrochir Plast Chir* 2002;34(2):103-7.
28. Chen SH, Chen YL, Cheng MH, Yeow KM, Chen HC, Wei FC. The use of ultrasonography in preoperative localization of digital glomus tumors. *Plast Reconstr Surg* 2003;112(1):115-9, discussion 120.
29. Ozdemir O, Coskunol E, Ozalp T, Ozaksar K. Glomus tumors of the finger: a report on 60 cases. *Acta Orthop Traumatol Turc* 2003;37(3):244-8.
30. Vasisht B, Watson HK, Joseph E, Lionelli GT. Digital glomus tumors: a 29-year experience with a lateral subperiosteal approach. *Plast Reconstr Surg* 2004; 114(6):1486-9.
31. Moon SE, Won JH, Kwon OS, Kim JA. Subungual glomus tumor: clinical manifestations and outcome of surgical treatment. *J Dermatol* 2004;31(12):993-7.
32. Maalla R, Hmid M, Mellouli O, Klila M. Glomus tumours of the hand. About 10 cases. *Tunis Med* 2007;85(6):469-72.
33. Li QL, Zhang JF, Li HB. Early diagnosis and microsurgical treatment of hand glomus tumor in 30 female cases. *Zhongguo Gu Shang* 2008;21(5):381-2.